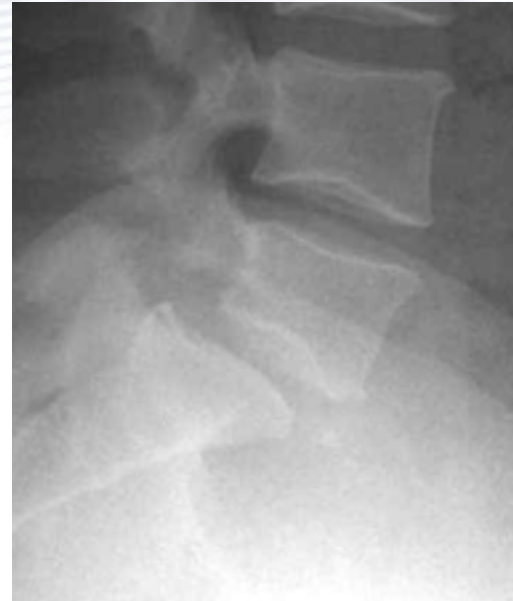
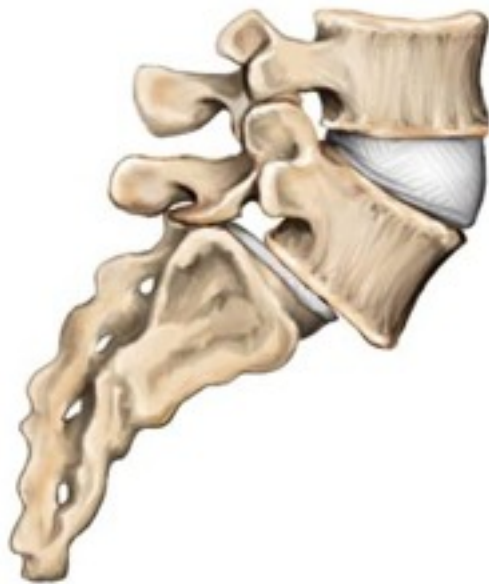

Orthopaedic Postgraduate Teaching
Sunderland 13th February 2012

Spondylolysis & Spondylolisthesis for the FRCS(Orth)



Michael Grevitt
Consultant Spinal Surgeon,

Introduction – why bother?

- ‘Common problem in community
- Interface’ topic in FRCS (Orth)
- Transportable, ‘user-friendly’ cases
- More spinal examiners!



Centre for Spinal Studies & Surgery, Nottingham



Outline

- **Background**
- **Definitions, classification**
- **Aetiology & natural history**



Paediatric	Adult	Older adult
Spondylolysis Isthmic s'listhesis	Spondylolysis Isthmic s'listhesis	Degenerative s'listhesis

- symptoms, physical examination
- Imaging,
- conservative & surgical management
- **Summary**

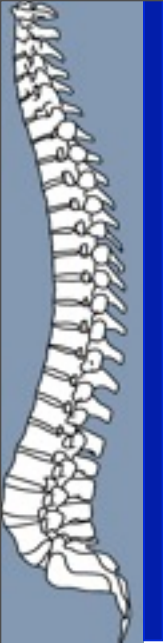



Background

- 1782 Belgian obstetrician Herbinaux.
 - He reported a bony prominence anterior to the sacrum that obstructed labour
- 1854 σπονδυλος = "vertebra" "όλισθος" = "a slip"
- Prevalence 5-7% Caucasian population
 - >50% Inuit Indians!
- Not present at birth & never occurs in non-walkers

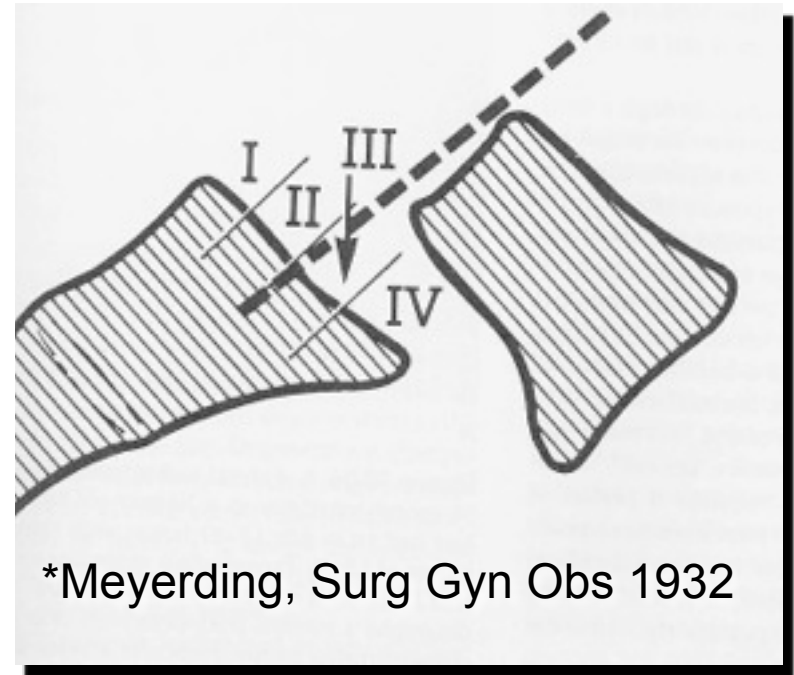




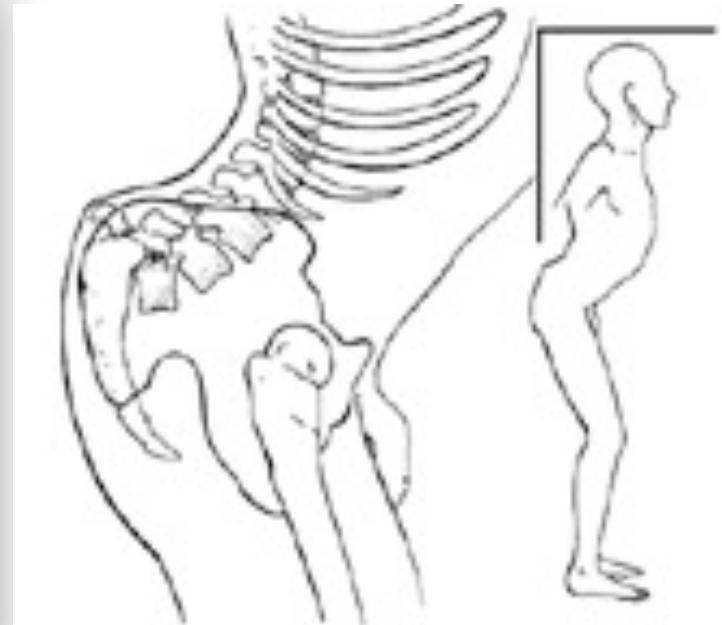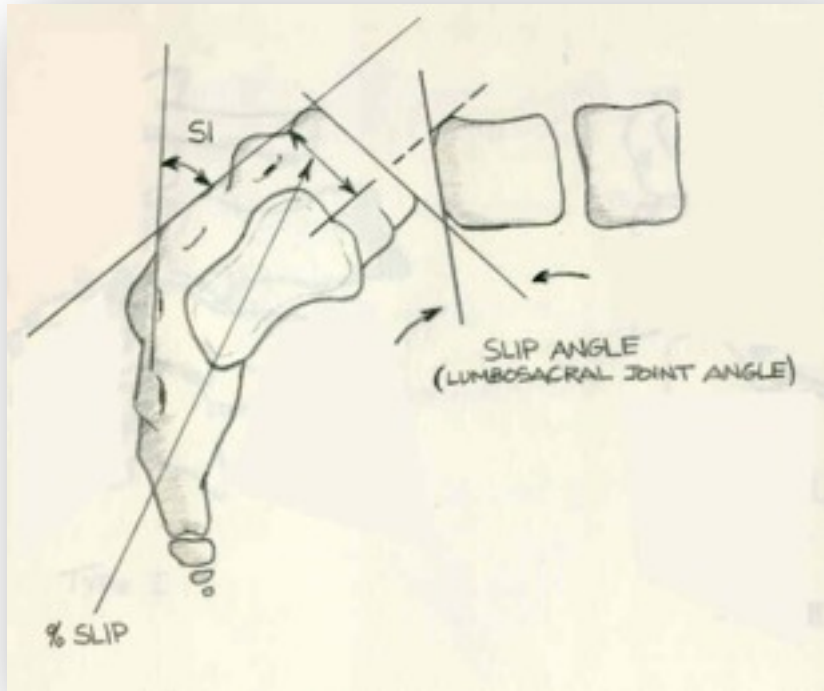
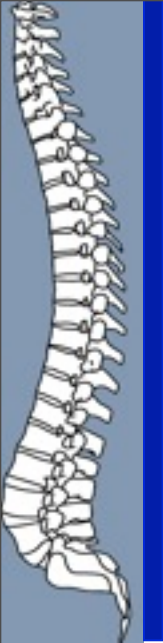Definitions -

Grade of slip*

- I 0-25%
- II 25-50%
- III 50-75%
- IV 75-100%
- 'V' >100%
'spondyloptosis'



Definitions – ‘slip angle’ & lumbosacral kyphosis



Centre for Spinal Studies & Surgery, Nottingham





Classification*

Patho-anatomical

- Congenital / dysplastic
- Isthmic
 - A. lytic (fatigue #) pars
 - B. elongated, attenuated pars
 - C. acute pars #
- Degenerative
- Pathological
- Traumatic

* Newman JBJS[Br] 1963



Classification*

Patho-anatomical

- Congenital / dysplastic
- Isthmic
 - A. lytic (fatigue #) pars
 - B. elongated, attenuated pars
 - C. acute pars #
- Degenerative
- Pathological
- Traumatic

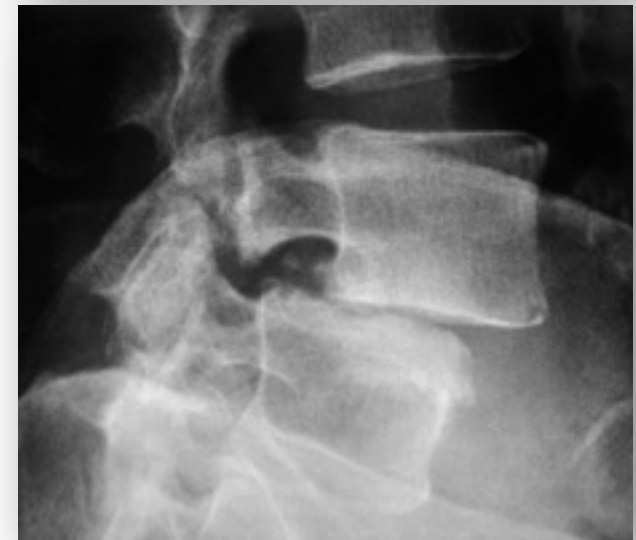* Newman JBJS[Br] 1963



Aetiology & natural history

Isthmic s'listhesis

- High prevalence gymnasts etc.
- High pelvic 'incidence'
- Repeated extension
 - Impaction upper articular process on pars ('nutcracker')
 - Stress #
 - Eventual disc failure
 - Olisthesis



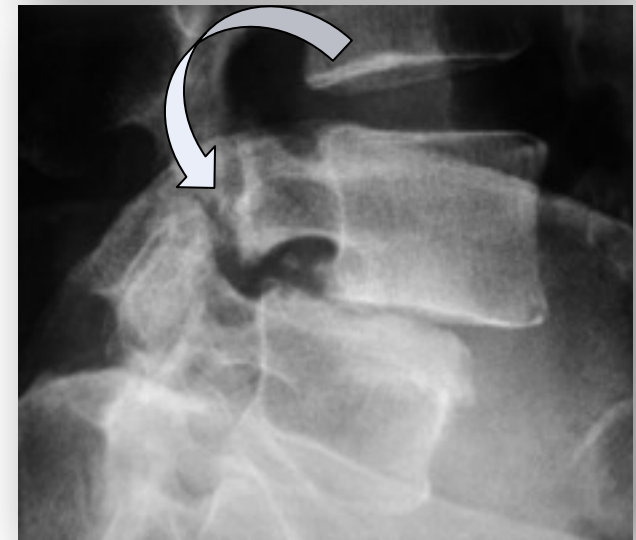Centre for Spinal Studies & Surgery, Nottingham



Aetiology & natural history

Isthmic s'listhesis

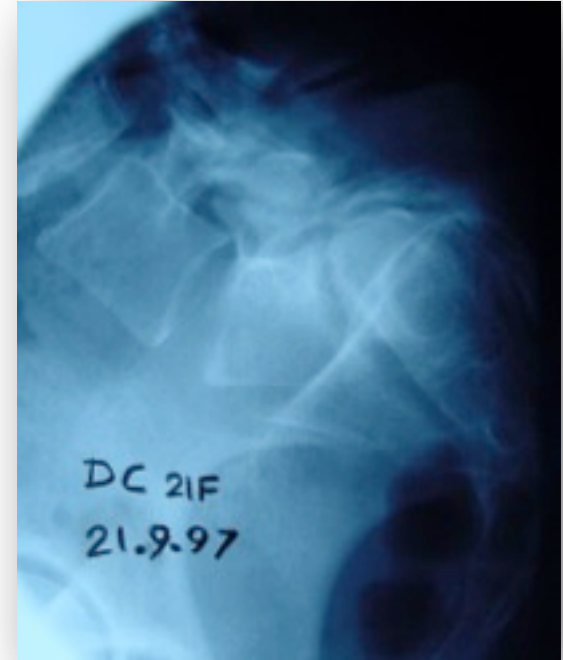
- High prevalence gymnasts etc.
- High pelvic 'incidence'
- Repeated extension
 - Impaction upper articular process on pars ('nutcracker')
 - Stress #
 - Eventual disc failure
 - Olisthesis



Aetiology & natural history

Dysplastic s'listhesis

- as previous plus....
- Progression potential
 - large slip angle
 - dome sacrum
 - hypoplastic facets
 - significant growth potential
- Repeated fractures & healing
 - no lysis





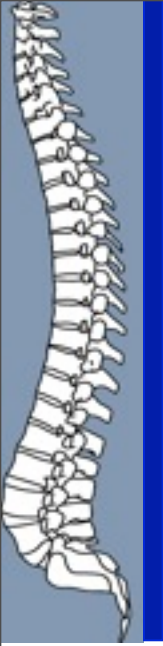Aetiology & natural history

The 'classic' paper

The natural history of spondylolysis and spondylolisthesis
Frederickson JBJA [Am] 1984

- 500 unselected first-grade children from 1955 -57
families of the children with s'lysis
- Aged 6 years - 4.4%
- Adults - 6.0%
- Hereditary pre-disposition
- Strong association with spina bifida occulta.
- Progression of a slip was unlikely after adolescence





Paediatric spondylolysis & spondylolisthesis

Centre for Spinal Studies & Surgery, Nottingham



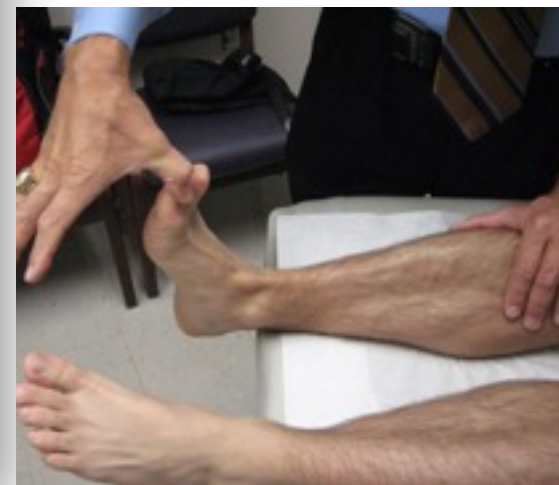
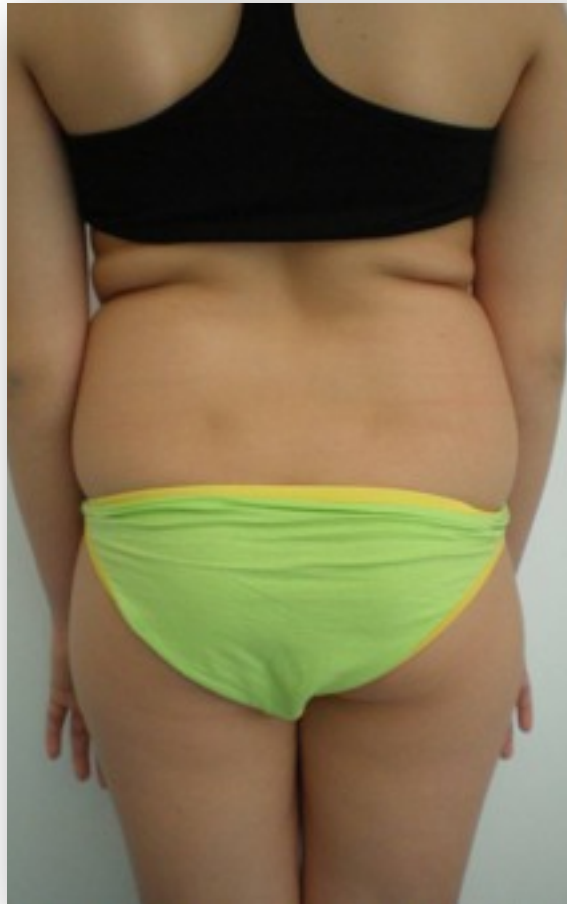
Symptoms

- Activity related back pain and/or buttock pain
- Radicular pain (L5 nerve root)
- Cauda equina syndrome (rare)
- Listhetic crisis
 - severe back pain
 - hamstring spasm
 - crouched gait



Physical examination

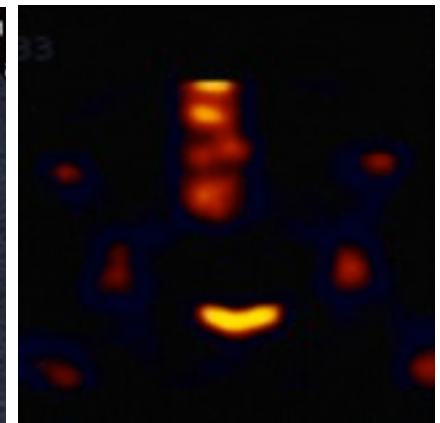
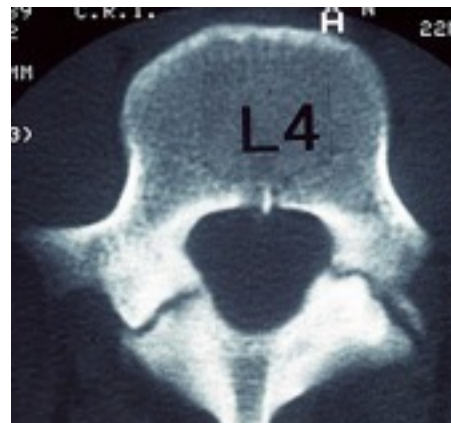
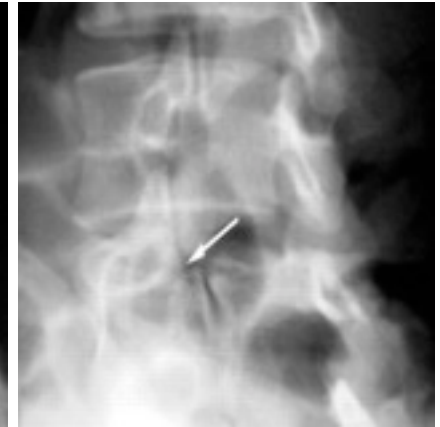
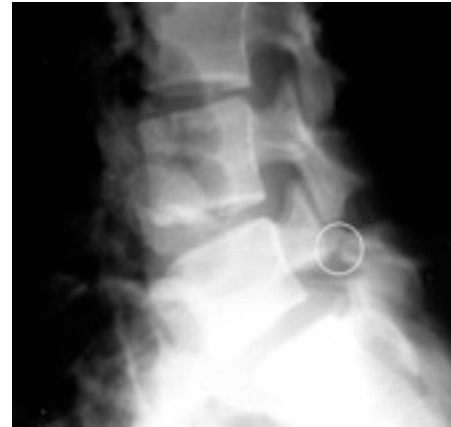
Centre for Spinal Studies & Surgery, Nottingham



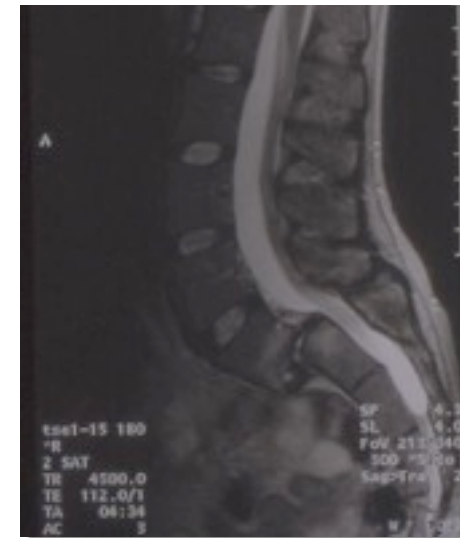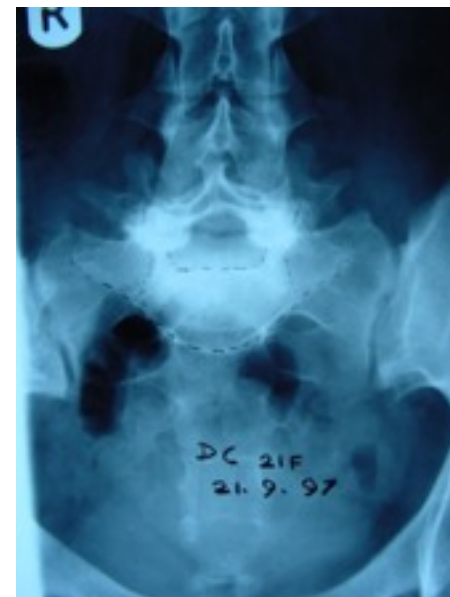Imaging – S'lysis & stress reaction

- Radiographs
 - Plain lateral
 - 'Scotty Dog' oblique
- CT
 - Size of gap
 - Sclerosis
 - Thickening ' stress reaction
 - Preop. planning
- Bone scan / SPECT
- MRI
 - High signal intensity pedicle



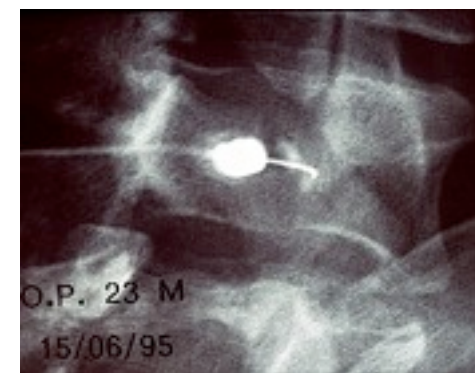Imaging – S'listhesis

- Plain x-rays
 - Degree of slip, slip angle etc
 - Dynamic films 'instability'
 - 'Napoleon' hat' of dysplastic listhesis
- MRI
 - Integrity of the disc
 - Associated foraminal stenosis



Conservative management

- Acute lysis, listhestic 'crisis'
 - Rest, analgesia
 - Lysis block
 - TLSO / hip spica cast
- Spondylolisthesis
 - Core stability regimen
 - Reappraisal of sports technique

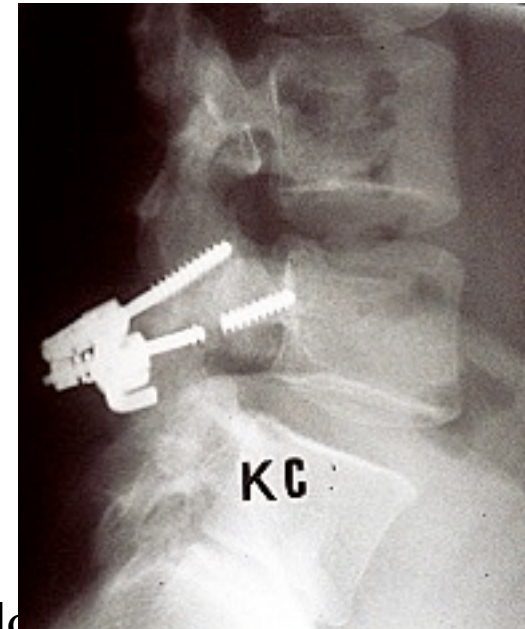
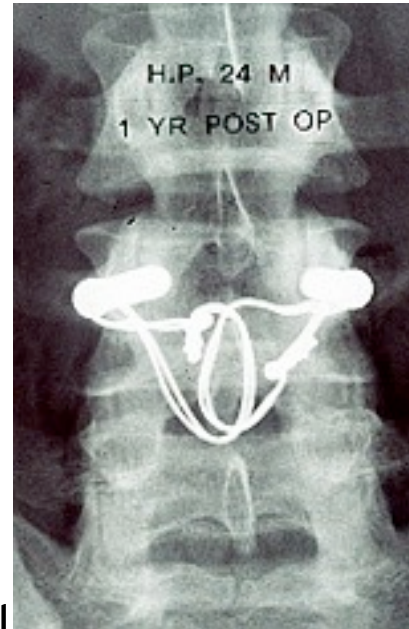
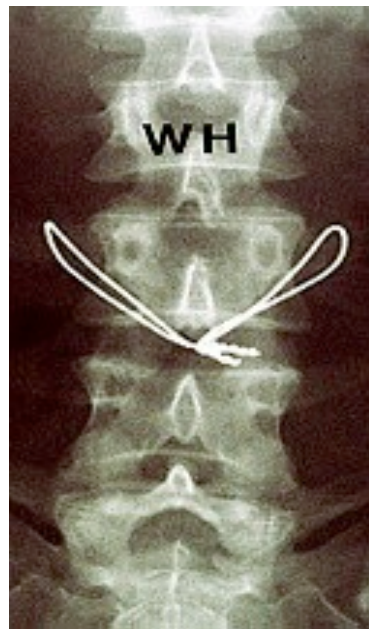
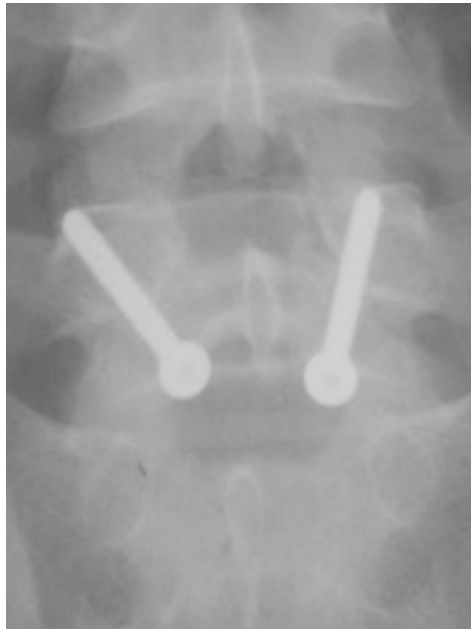Centre for Spinal Studies & Surgery, Nottingham



Pars repair

- Indications
 - Chronic defect, minimal gap / slip, normal disc
 - Failed conservative therapy
- Buck's repair, Scott & modified Scott techniques, Morscher Hook-screw device





L5-S1 in-situ posterolateral fusion

- Lysis
- Low grade s'listhesis
- Failed pars repair
- Indications
 - has failed non-operative treatment
 - is progressive
 - has neurologic deficits
 - is dysplastic due to high propensity for progression

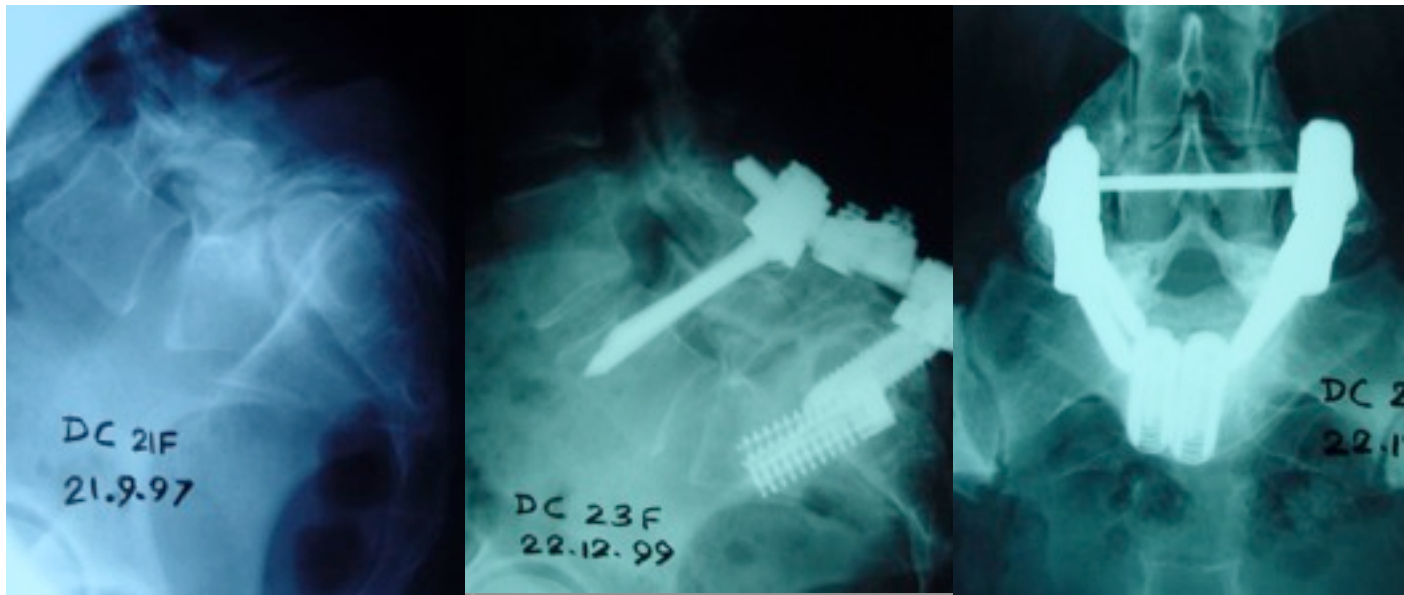
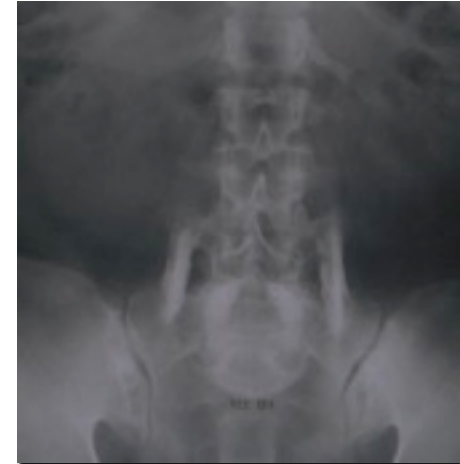

L4-S1 posterolateral fusion (+/- ALIF)

High grade isthmic slip (III-V)

Techniques:

- Uninstrumented fusion
- Bohlmann technique(s)



Centre for Spinal Studies & Surgery, Nottingham





Reduction of high grade slips

Pros:

- Restores sagittal profile
- Reduces lumbo-sacral kyphosis
- Fusion under compression

Cons:

- High neurological complication rate (10-30%)
- Technically demanding
- Evidence base poor (*Poussa Spine 2006*)





Treatment of L5-S1 Spondyloptosis by Staged L5 Resection With Reduction and Fusion of L4 Onto S1 (Gaines procedure)

M Lehmer, A Steffee, R Gaines SPINE 1994

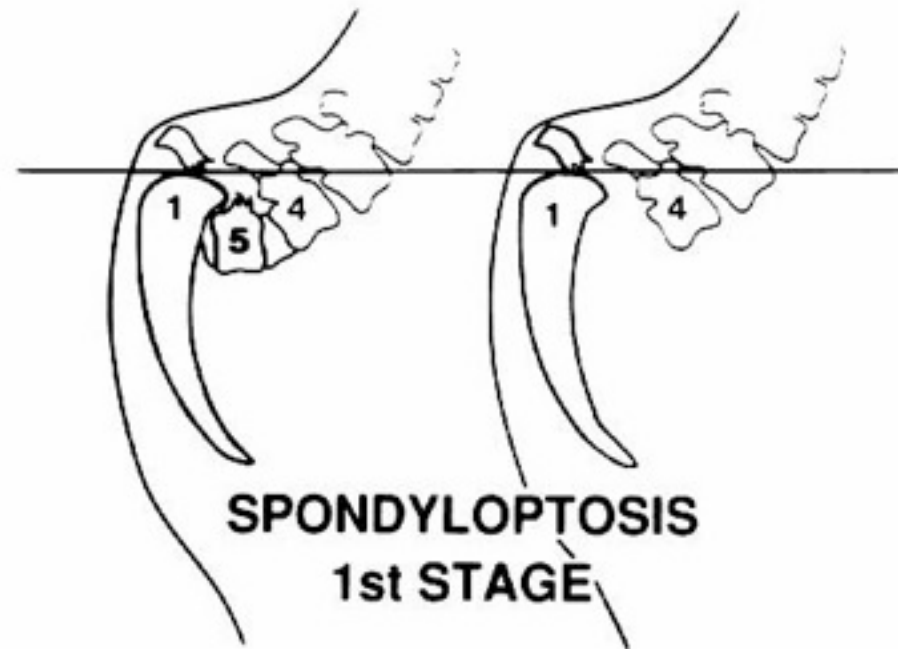
Centre for Spinal Studies & Surgery, Nottingham





Treatment of L5-S1 Spondyloptosis by Staged L5 Resection With Reduction and Fusion of L4 Onto S1 (Gaines procedure)

M Lehmer, A Steffee, R Gaines SPINE 1994



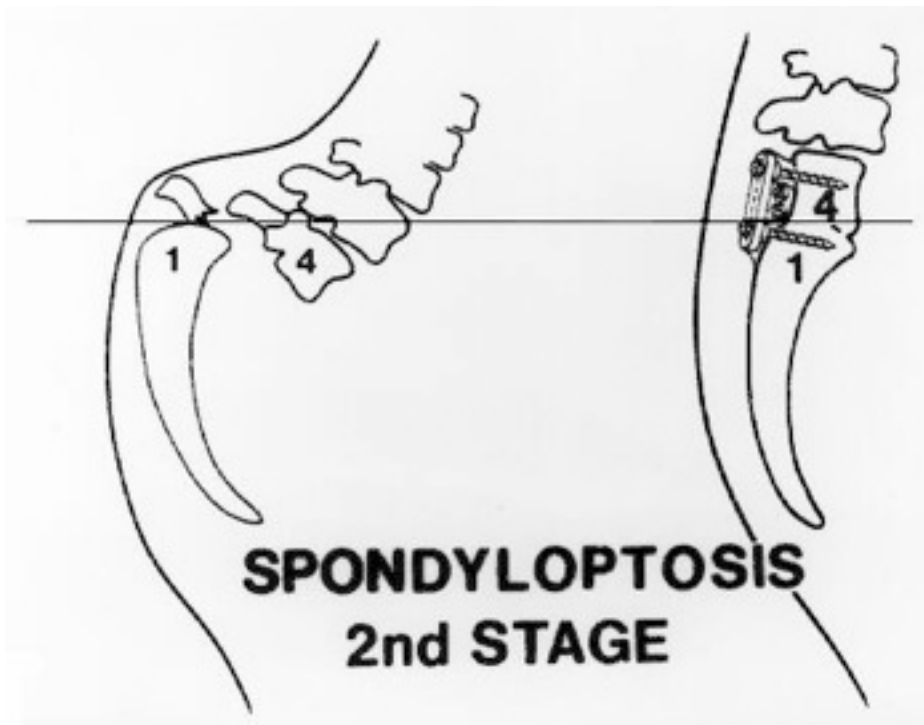
Centre for Spinal Studies & Surgery, Nottingham





Treatment of L5-S1 Spondyloptosis by Staged L5 Resection With Reduction and Fusion of L4 Onto S1 (Gaines procedure)

M Lehmer, A Steffee, R Gaines SPINE 1994



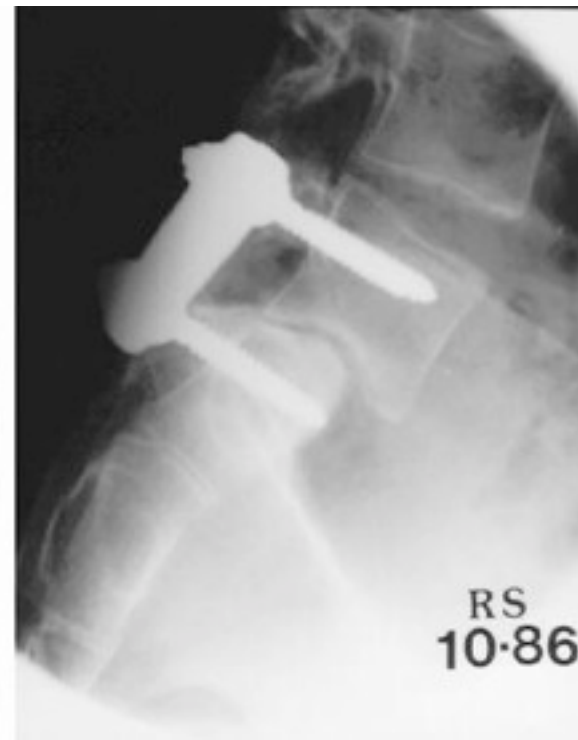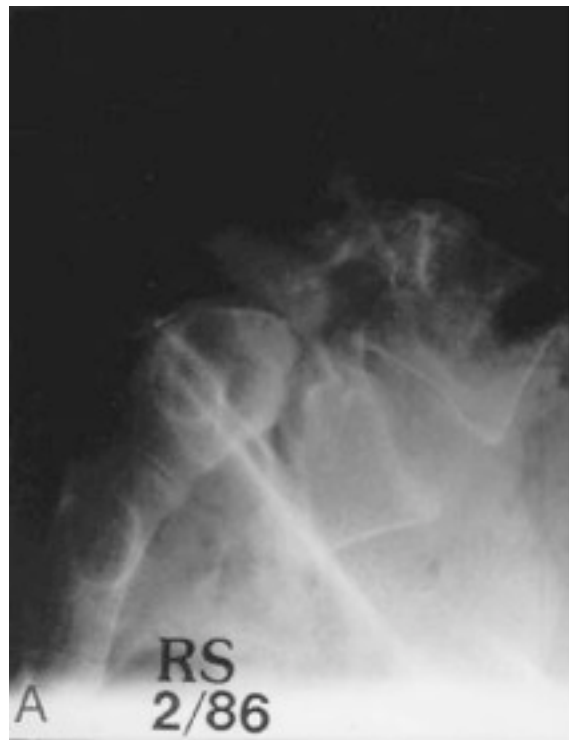Centre for Spinal Studies & Surgery, Nottingham





Treatment of L5-S1 Spondyloptosis by Staged L5 Resection With Reduction and Fusion of L4 Onto S1 (Gaines procedure)

M Lehmer, A Steffee, R Gaines SPINE 1994



Centre for Spinal Studies & Surgery, Nottingham



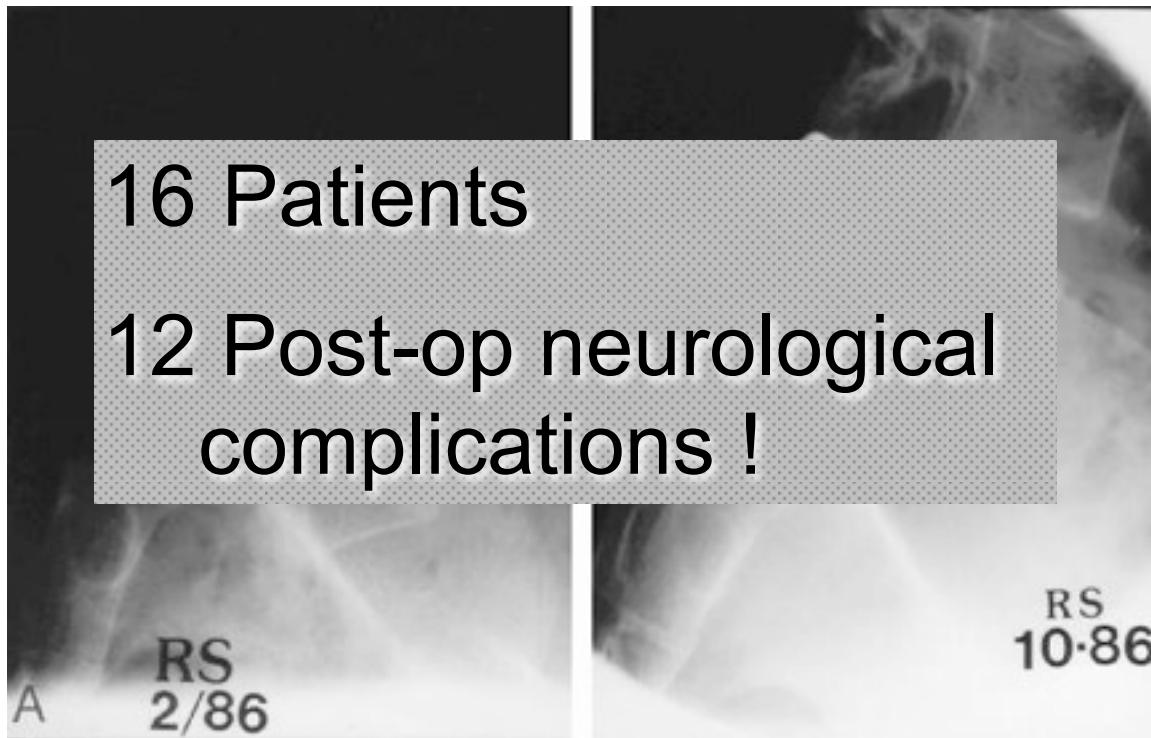

Treatment of L5-S1 Spondyloptosis by Staged L5 Resection With Reduction and Fusion of L4 Onto S1 (Gaines procedure)

M Lehmer, A Steffee, R Gaines SPINE 1994

16 Patients

12 Post-op neurological complications !

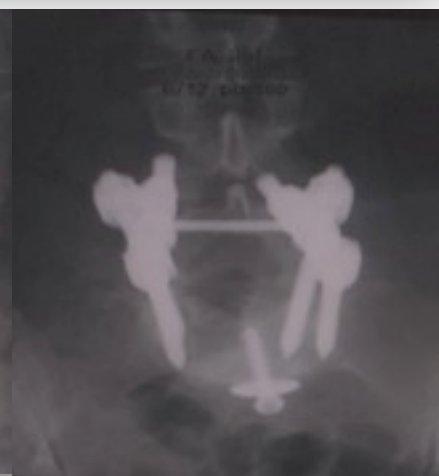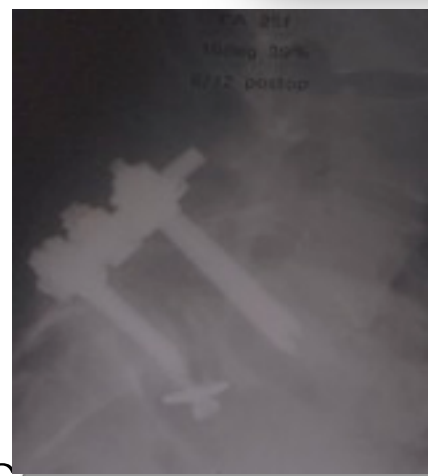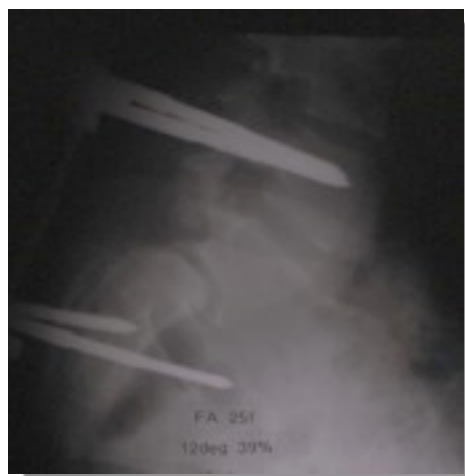
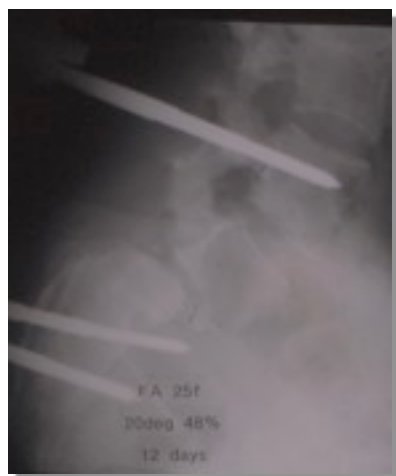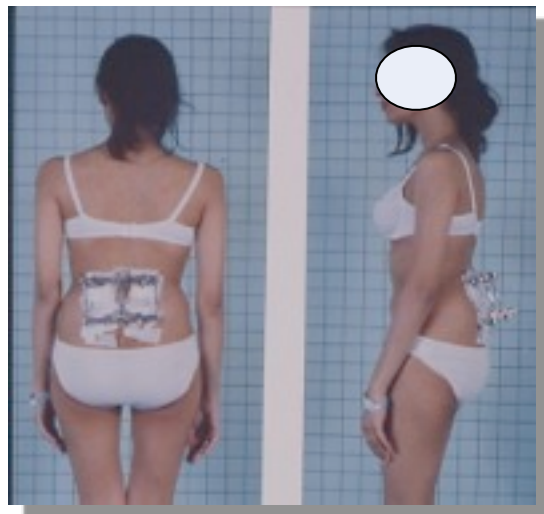


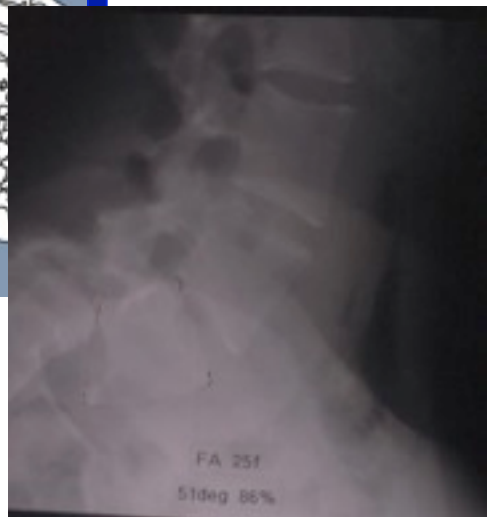Centre for Spinal Studies & Surgery, Nottingham



Nottingham technique*

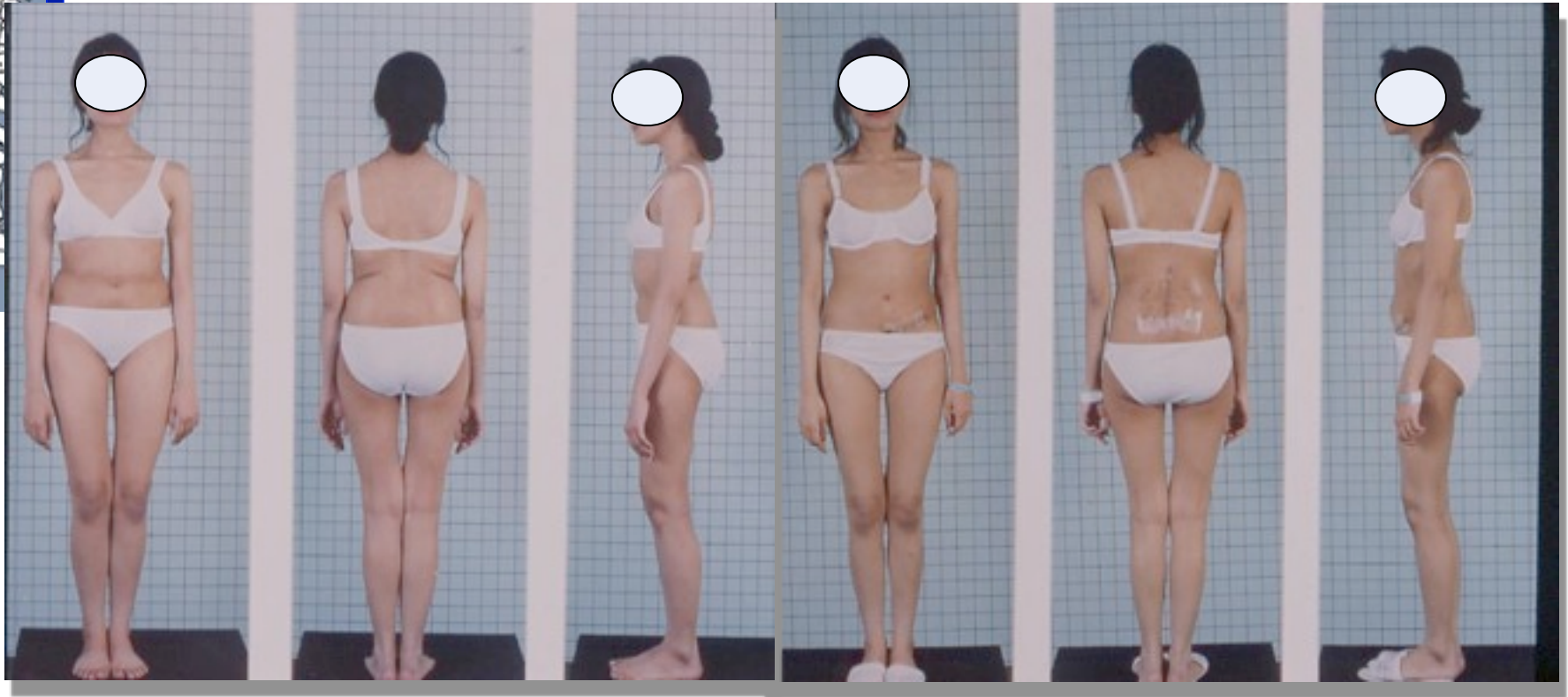- Magerl external fixator for gradual reduction
- L5/S1 circumferential fusion



Centre for Spinal Studies & Surgery, Nottingham



Nottingham technique*



*Karampalis Eur Spine J 2012 (in press)

Centre for Spinal Studies & Surgery, Nottingham





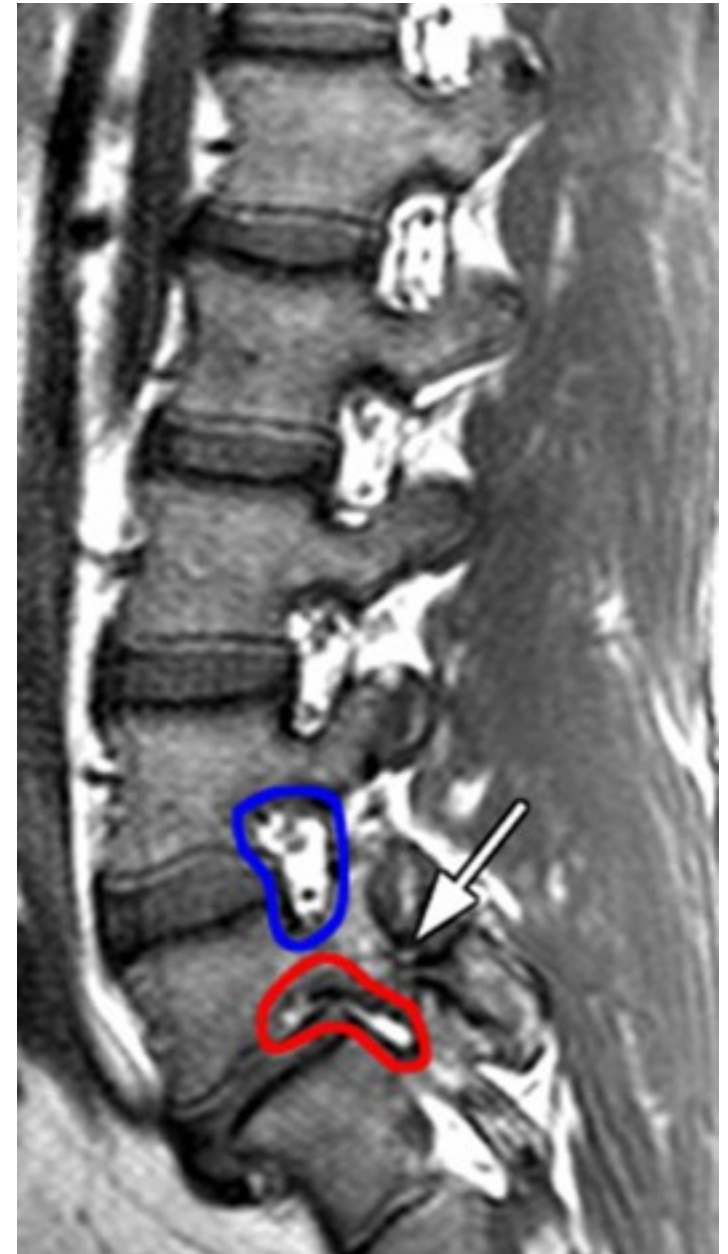
Adult spondylolisthesis

Centre for Spinal Studies & Surgery, Nottingham



Symptoms

- Mechanical back pain
 - most common presentation
 - pain usually has a long history with periodic exacerbations
- L5 radiculopathy
 - usually caused by foraminal stenosis at the L5-S1 level

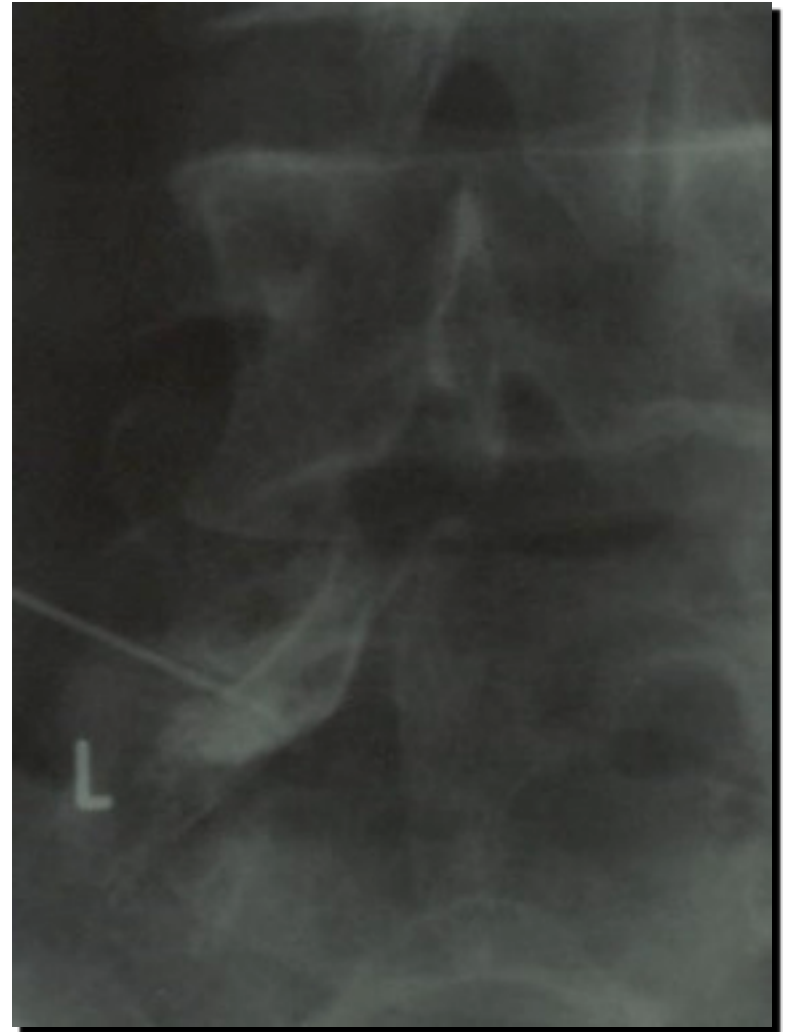

Centre for Spinal Studies & Surgery, Nottingham



Conservative management

- Activity restriction
- NSAIDS
- Physiotherapy
 - Core stability regimen
 - Sports technique
- Nerve root block
 - radicular symptoms



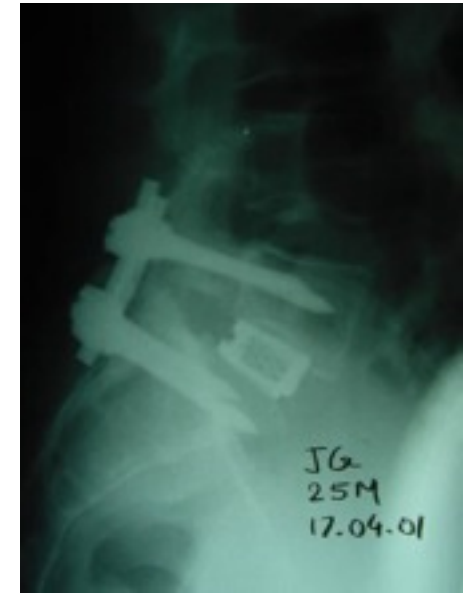Decompression & Posterolateral fusion

- Decompression
 - radiculopathy
 - Gill laminectomy and foraminal decompression
 - removal of loose lamina and scarred pars defect allows decompression of nerve root
 - a Gill decompression is destabilizing and should be combined with fusion
- Fusion
 - posterolateral fusion is standard
 - controversy re: use of instrumentation



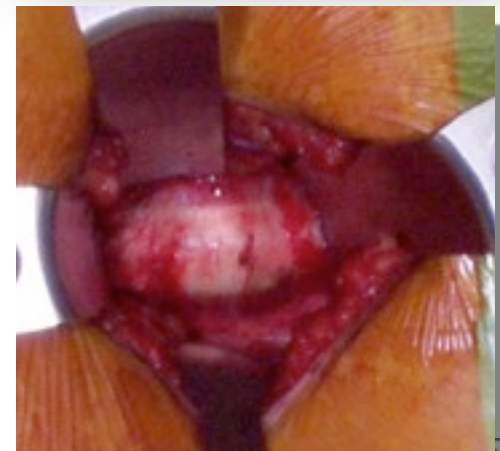
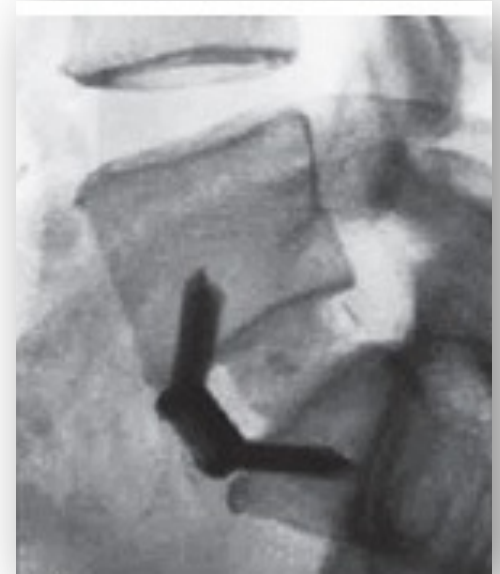Posterior Lumbar Interbody Fusion (PLIF)

- Circumferential (360°) fusion
- technique
 - insertion of interbody spacer medial to facets
 - transforaminal lumbar interbody fusion (TLIF)
- pros
 - greater fusion rate
 - better lordosis
- cons
 - higher complication rate
 - little evidence that functional results better



Anterior Lumbar Interbody Fusion (ALIF)

- indications
 - Low-grade isthmic spondylolisthesis
- technique
 - trans- or retroperitoneal approach
 - Indirect decompression by foraminal distraction via restoration of disc height
- pros
 - higher fusion rates
 - better restoration of lordosis
- cons
 - technically demanding
 - vascular injury
 - retrograde ejaculation & sexual dysfunction



Centre for Spinal Studies & Surgery, Nottingham





Degenerative spondylolisthesis

Centre for Spinal Studies & Surgery, Nottingham





Introduction

- Commonest at L4/5
- Higher prevalence in women
- Patho-anatomy
 - intervertebral disc degeneration
 - facet joint degeneration & sagittal orientation
 - buckling of ligamentum flavum
 - instability and anterolisthesis



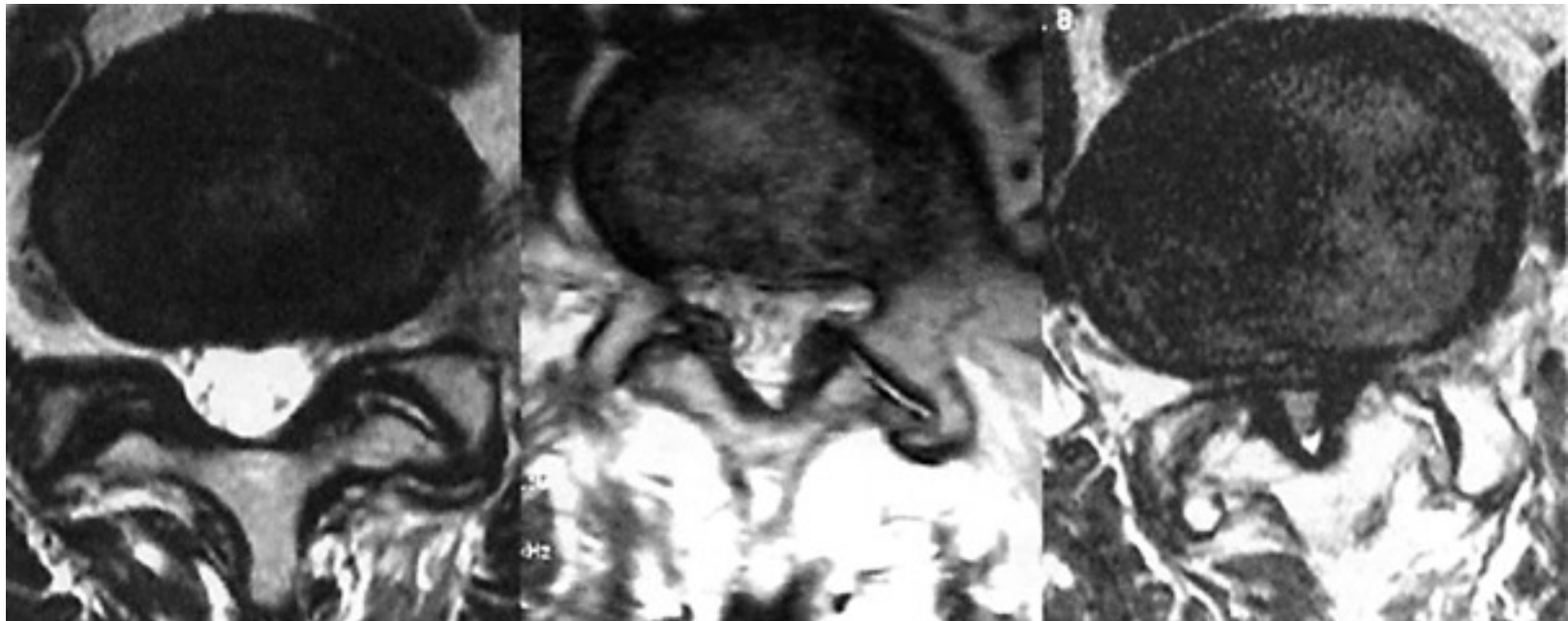


Central / lateral recess stenosis

- L5 root compressed between the hypertrophic and subluxed inferior facet of L4 and disc +the posterior superior L5 body

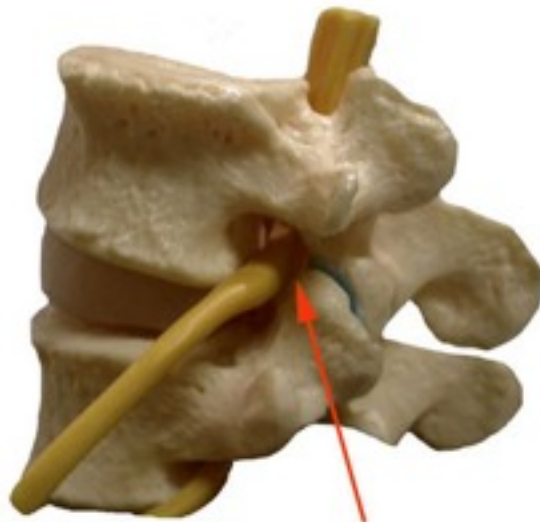
Later-

- ligamentum flavum hypertrophy
- facetal osteophytes & hypertrophy

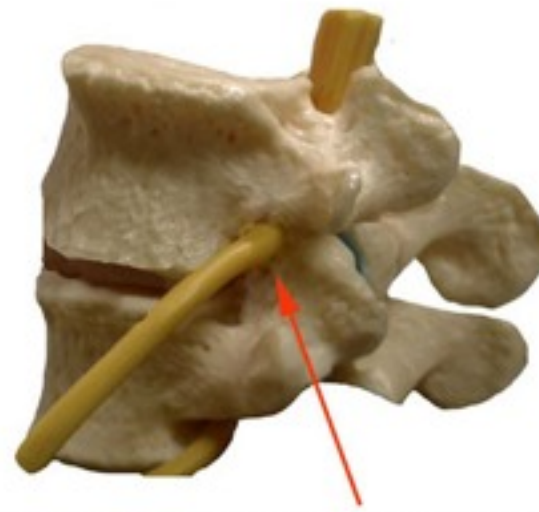


Foraminal stenosis

- vertical stenosis (loss of height of foramen)
 - caused by loss of disk height
 - Superior articular process riding up against pedicle
 - osteophytes from posterolateral corner of vertebral body
- anteroposterior stenosis (loss of anterior to posterior depth)
 - caused by degenerative changes of the superior articular facet and posterior vertebral body



NORMAL FORAMINAL SPACE



FORAMINAL STENOSIS AND DISC DEGENERATION



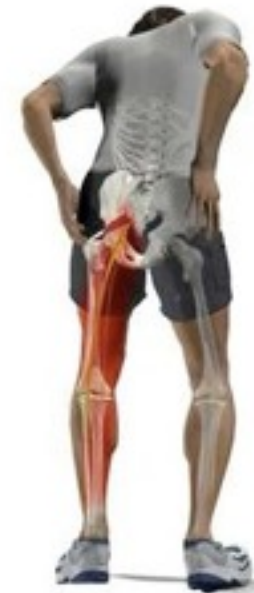Symptoms – Claudication pain

- Neurogenic

- Buttock to calf radiation
- Eased with sitting
- Relief within 15 minutes
- Flexed posture eases
'supermarket trolley 'test
- Dermatomal paraesthesiae

- Vascular

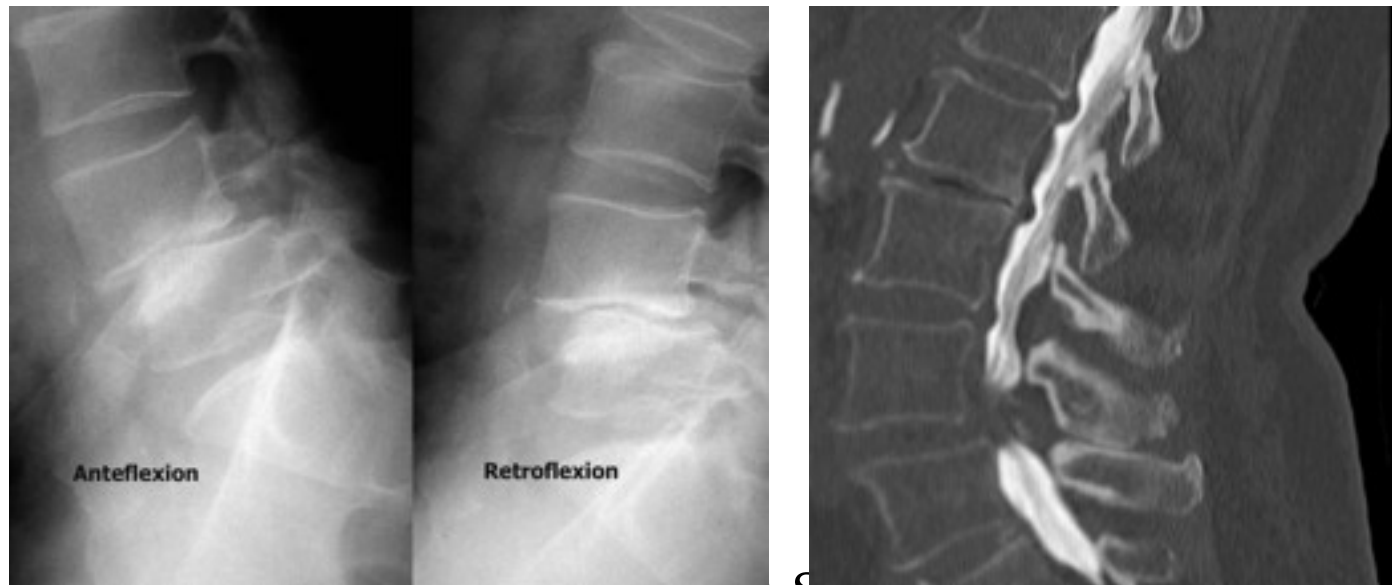
- Calf to buttock
- Standing
- Longer than 15 minutes





Imaging

- Plain radiographs
- Dynamic x-rays – instability (4mm translation/ 10° angulation)
- MRI
 - best study to evaluate impingement of neural elements
- CT myelogram
 - patients in which a MRI is contraindicated



Centre for Spinal Studies & Surgery, Nottingham





Conservative management

- Benign condition
 - 70% mild claudication symptoms same at 5 years
- Lateral recess / foraminal stenosis
 - Nerve root blocks
- Central stenosis
 - Epidural steroids poor efficacy & ‘NNT’
 - Physiotherapy little evidence base





Surgical management

- **Lumbar decompression**
 - Older, frail patient, loss of disc height, facet OA+
 - Laminotomies vs. laminectomies vs. MISS debate
- **Decompression + fusion**
 - Some RCTs suggest better result in younger pt. with LBP
- **Decompression + fusion + instrumentation**
 - RCTs suggest higher fusion rate with metalwork
 - No additional functional advantage & higher complication rate

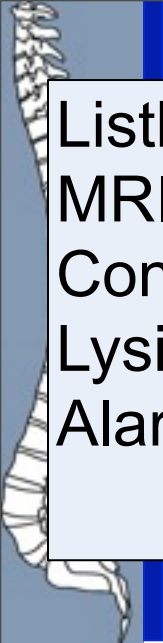




SUMMARY

Paediatric	Adult	Older adult
Spondylolysis Isthmic s'listhesis	Spondylolysis Isthmic s'listhesis	Degenerative s'listhesis





Listhetic crisis
MRI/ CT imaging
Conservative Rx
Lysis (Buck's) repair
Alar-transverse fusion

Pediatric	Adult	Older adult
Spondylolysis Isthmic s'listhesis	Spondylolysis Isthmic s'listhesis	Degenerative s'listhesis



Listhetic crisis
 MRI/ CT imaging
 Conservative Rx
 Lysis (Buck's) repair
 Alar-transverse fusion

Pediatric	Adult	Older adult
Spondylolysis Isthmic s'listhesis	Spondylolysis Isthmic s'listhesis	Degenerative s'listhesis

Progression potential
 Reduction vs. in-situ fusion
 debate
 Bohlmann technique
 Gaines procedure vs,
 Nottingham technique



Listhetic crisis
 MRI/ CT imaging
 Conservative Rx
 Lysis (Buck's) repair
 Alar-transverse fusion

LBP & radiculopathy
 Nerve root blocks
 Decompression & fusion
 (all types)

Pediatric

Adult

Older adult

Spondylolysis
 Isthmic s'listhesis

Spondylolysis
 Isthmic s'listhesis

Degenerative s'listhesis

Progression potential
 Reduction vs. in-situ fusion
 debate
 Bohlmann technique
 Gaines procedure vs,
 Nottingham technique



Listhetic crisis
MRI/ CT imaging
Conservative Rx
Lysis (Buck's) repair
Alar-transverse fusion

LBP & radiculopathy
Nerve root blocks
Decompression & fusion
(all types)

Pediatric

Adult

Older adult

Spondylolysis
Isthmic s'listhesis

Spondylolysis
Isthmic s'listhesis

Degenerative s'listhesis

Progression potential
Reduction vs. in-situ fusion
debate
Bohlmann technique
Gaines procedure vs,
Nottingham technique

Central / lateral / foraminal
stenosis
Claudication symptoms
Benign course – conservative
treatment
Decompression +/- fusion

al St



**Thank
you!**

