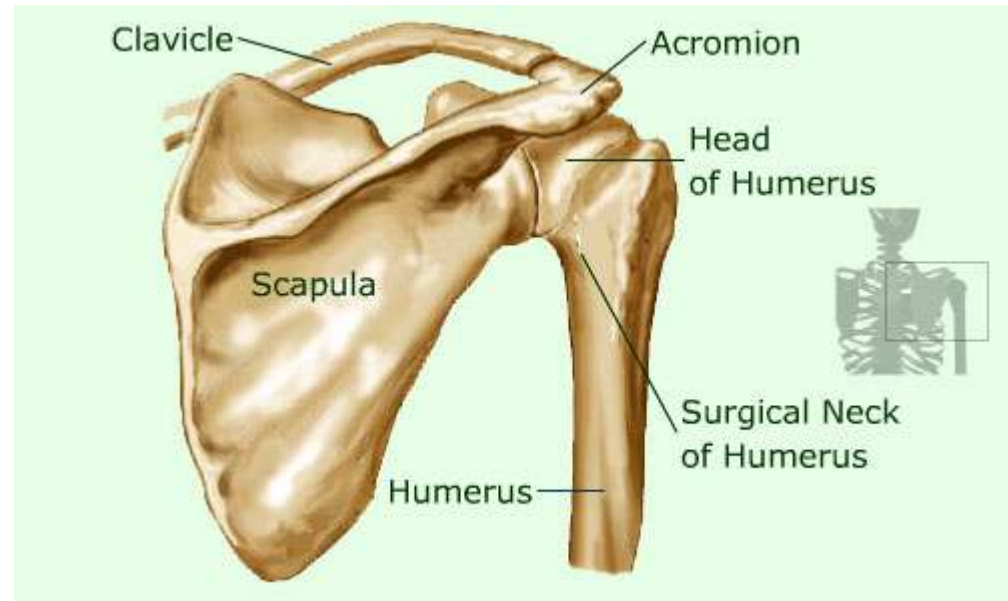
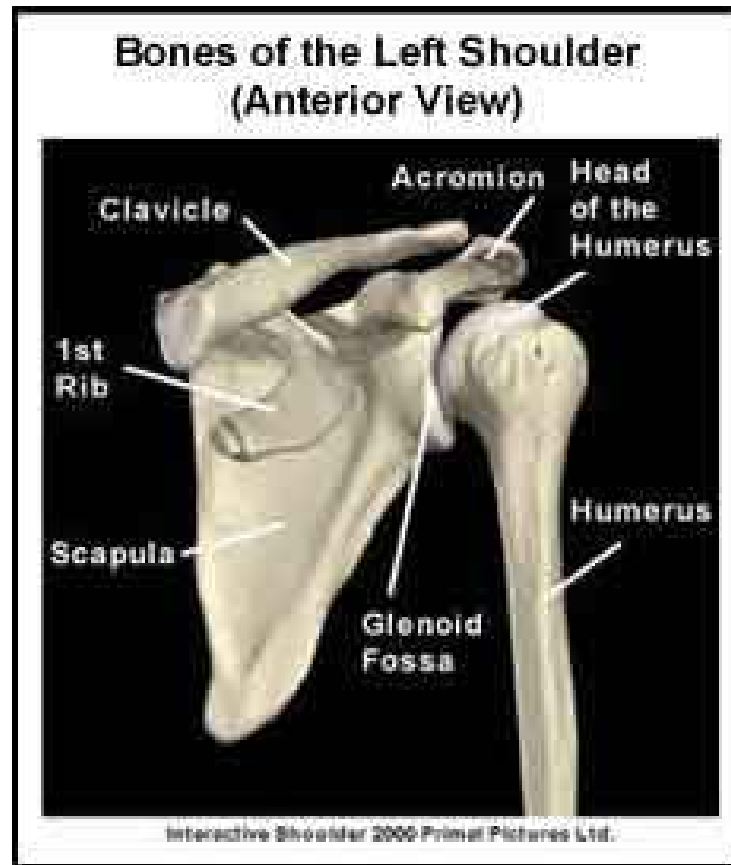


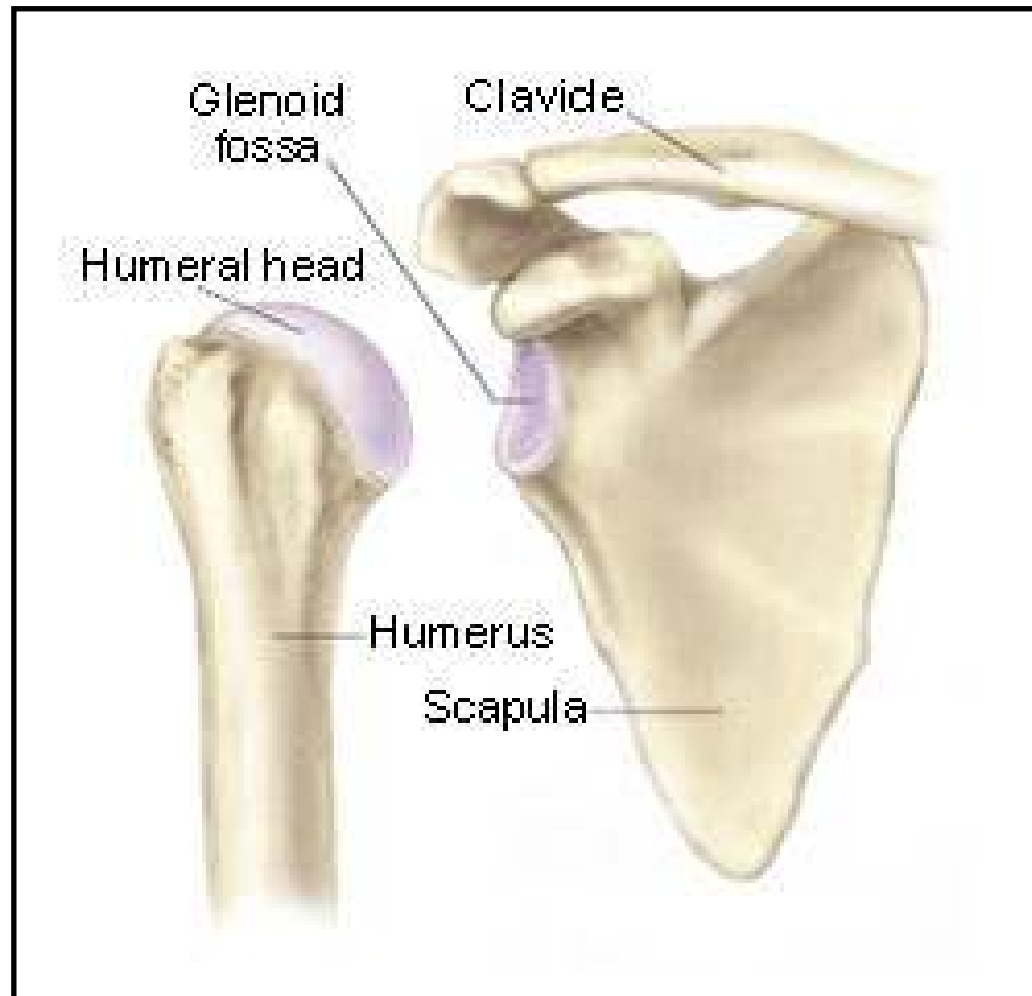
# Shoulder Anatomy

Sarah Johnson-Lynn

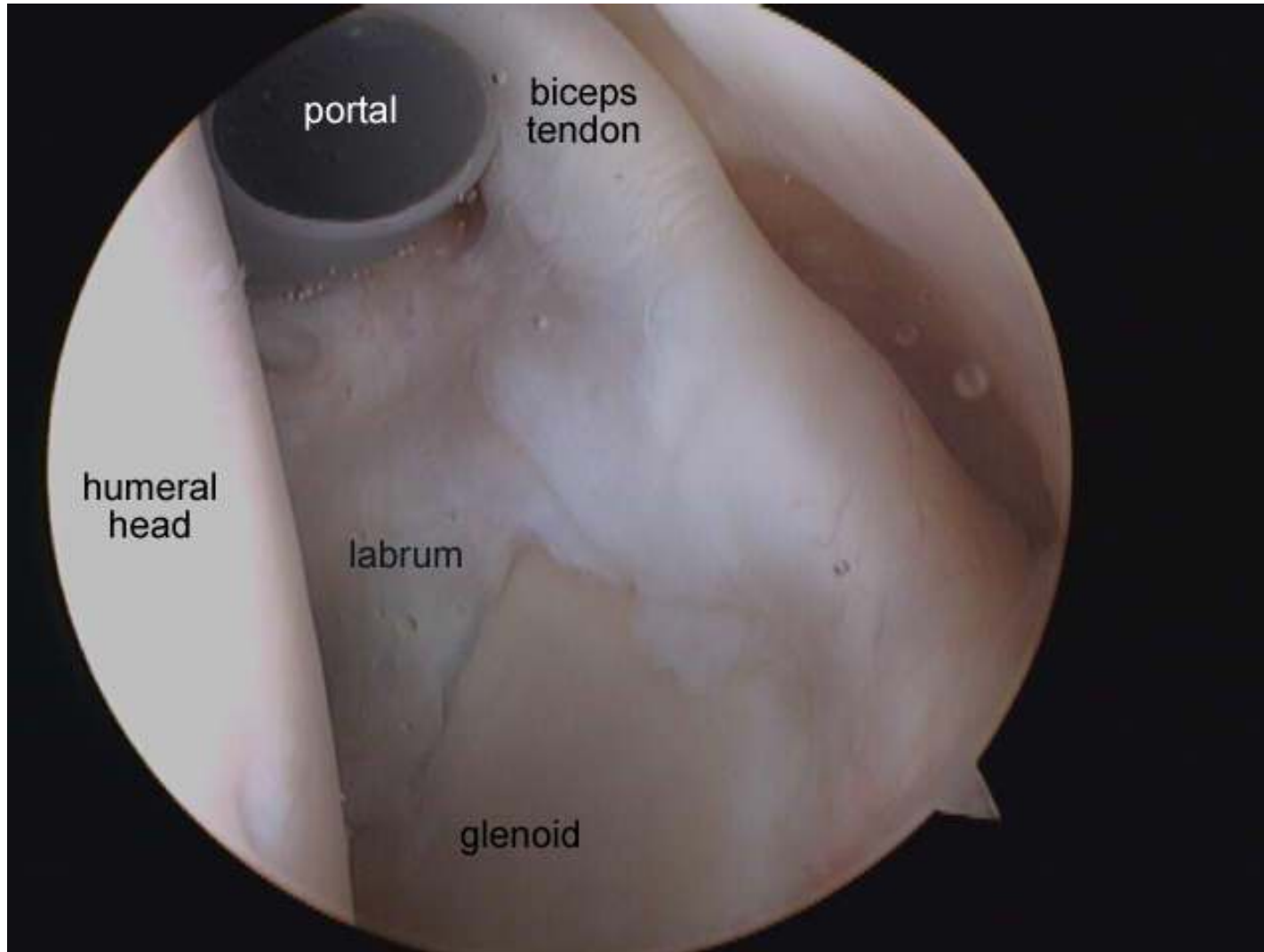
# Osteology



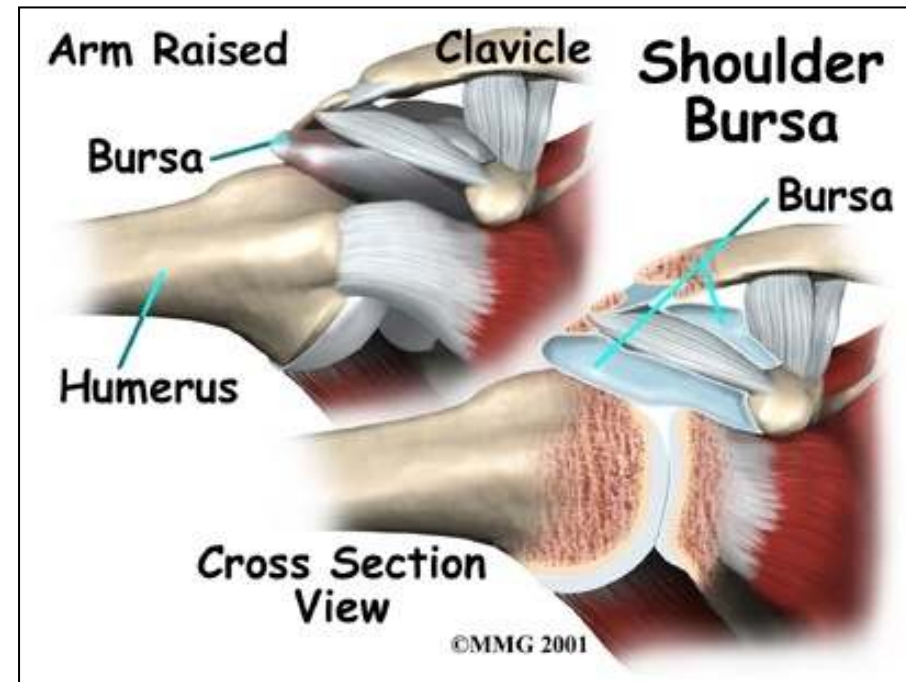
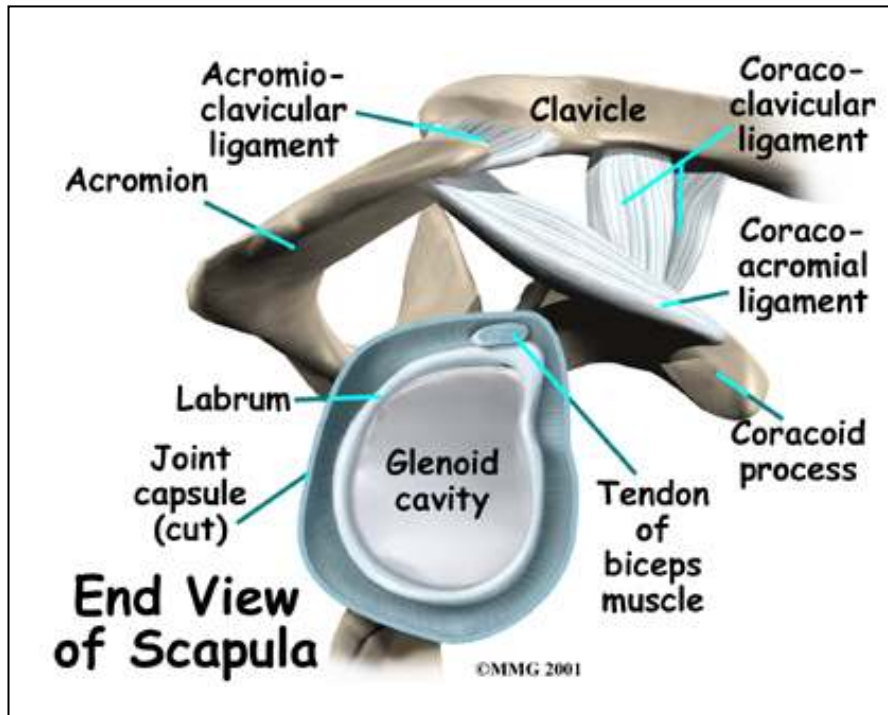
# Glenohumeral Joint



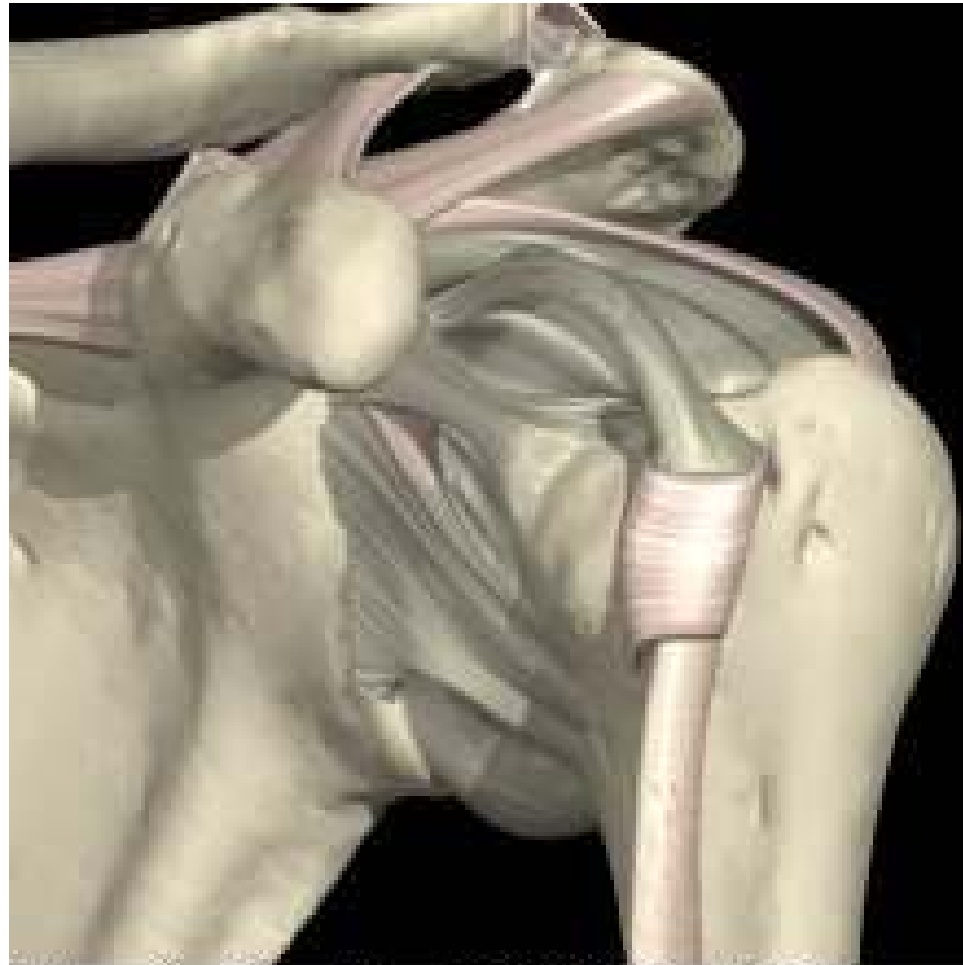# Labrum



# Ligaments and bursae

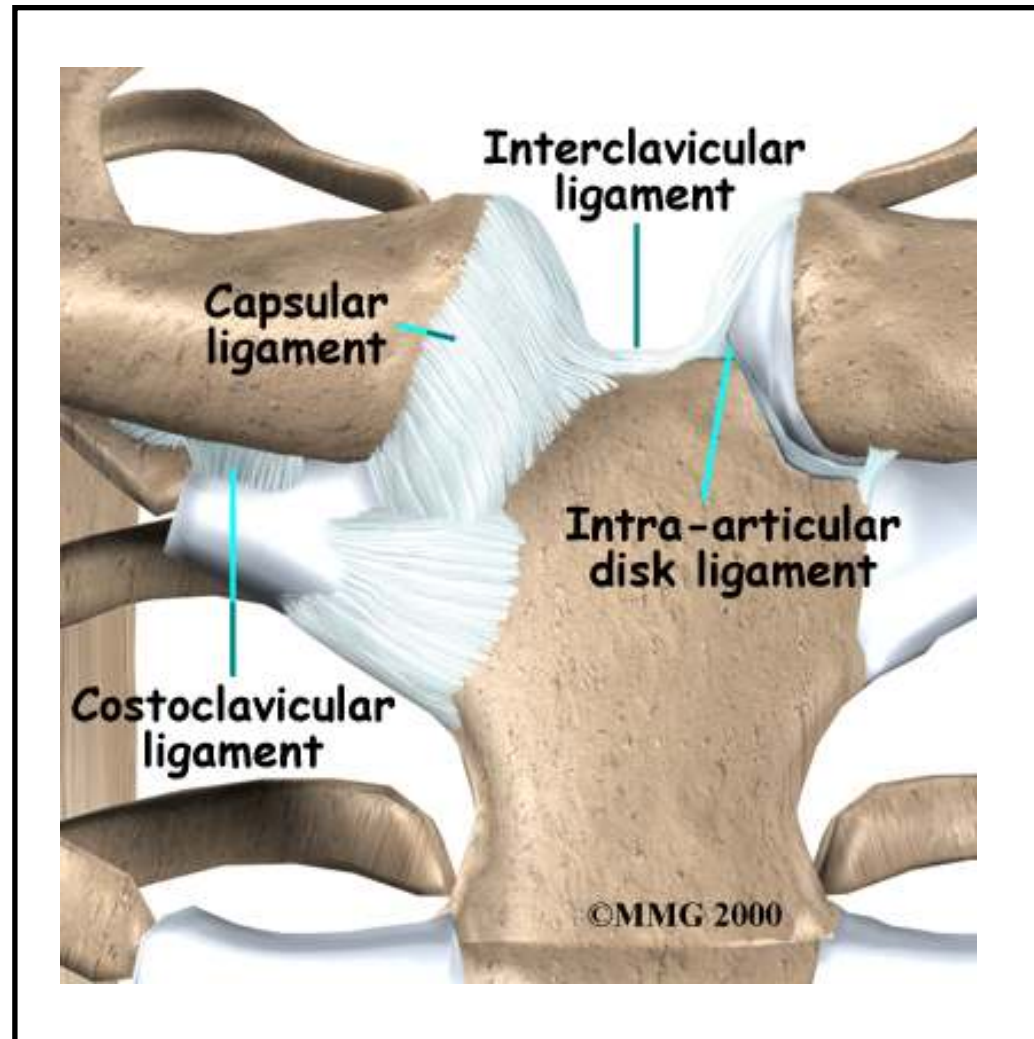


# Glenohumeral ligaments

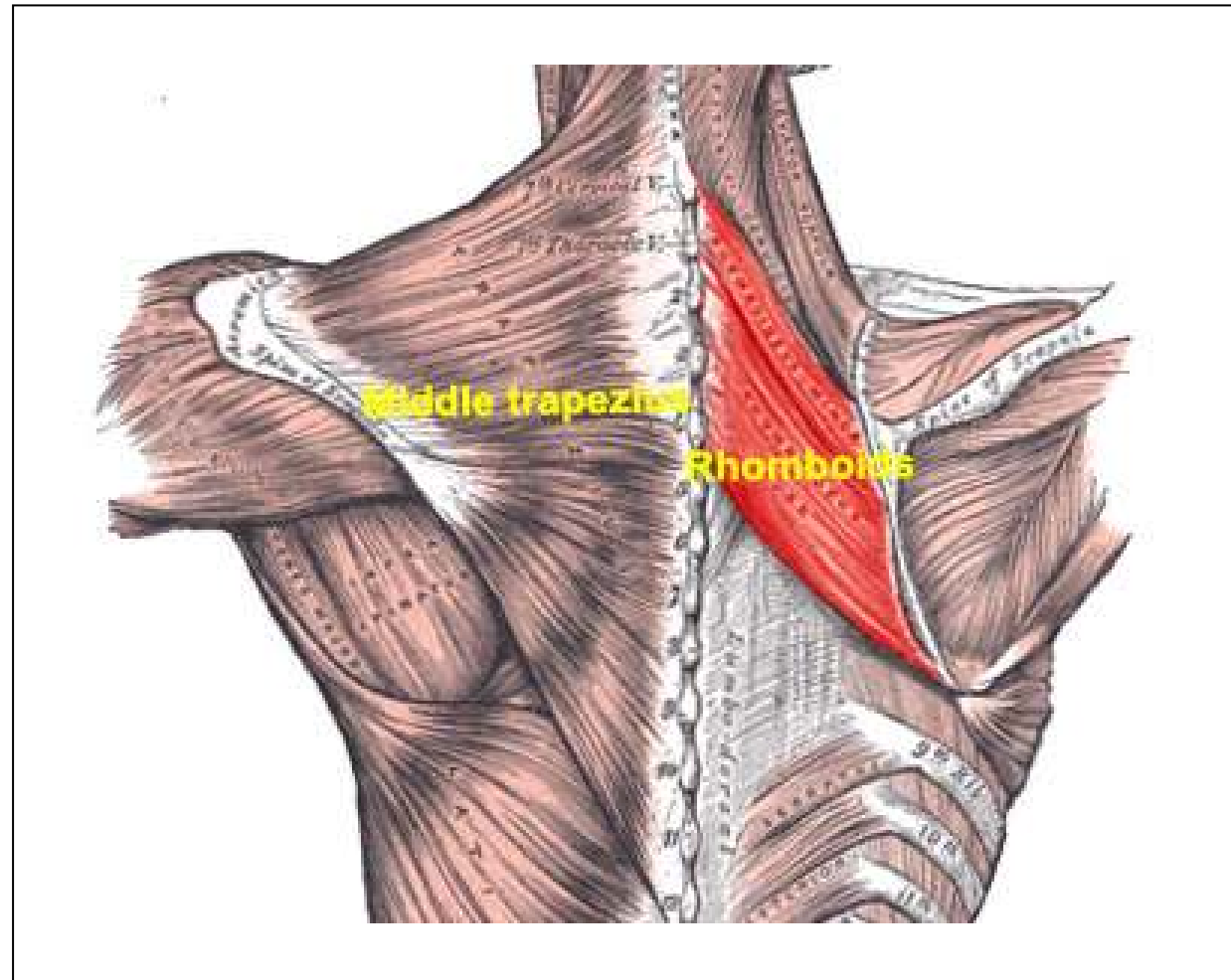


Interactive Shoulder © 2000 Primal Pictures Ltd.

# Sternoclavicular joint

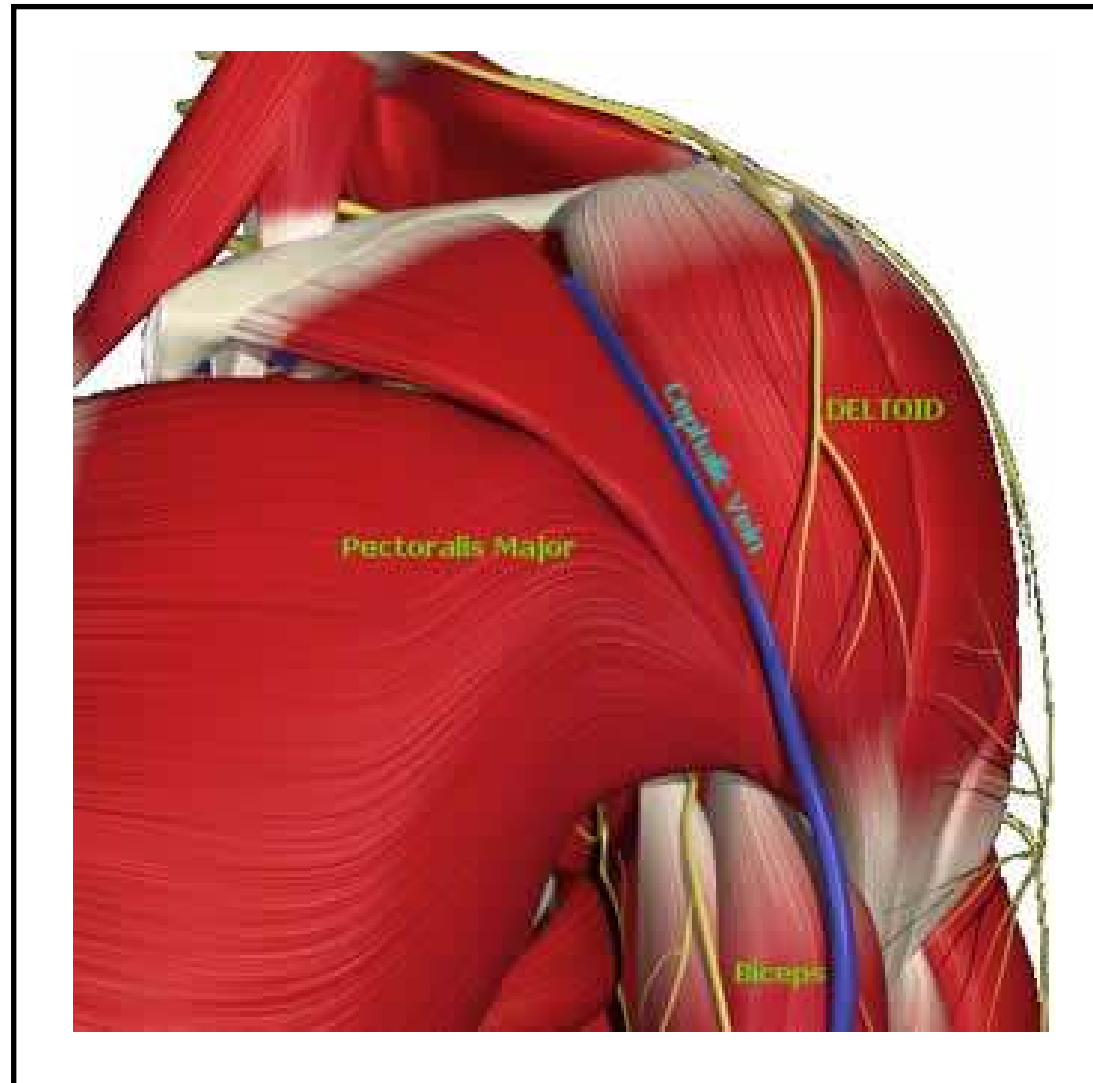


# Muscles - Posterior

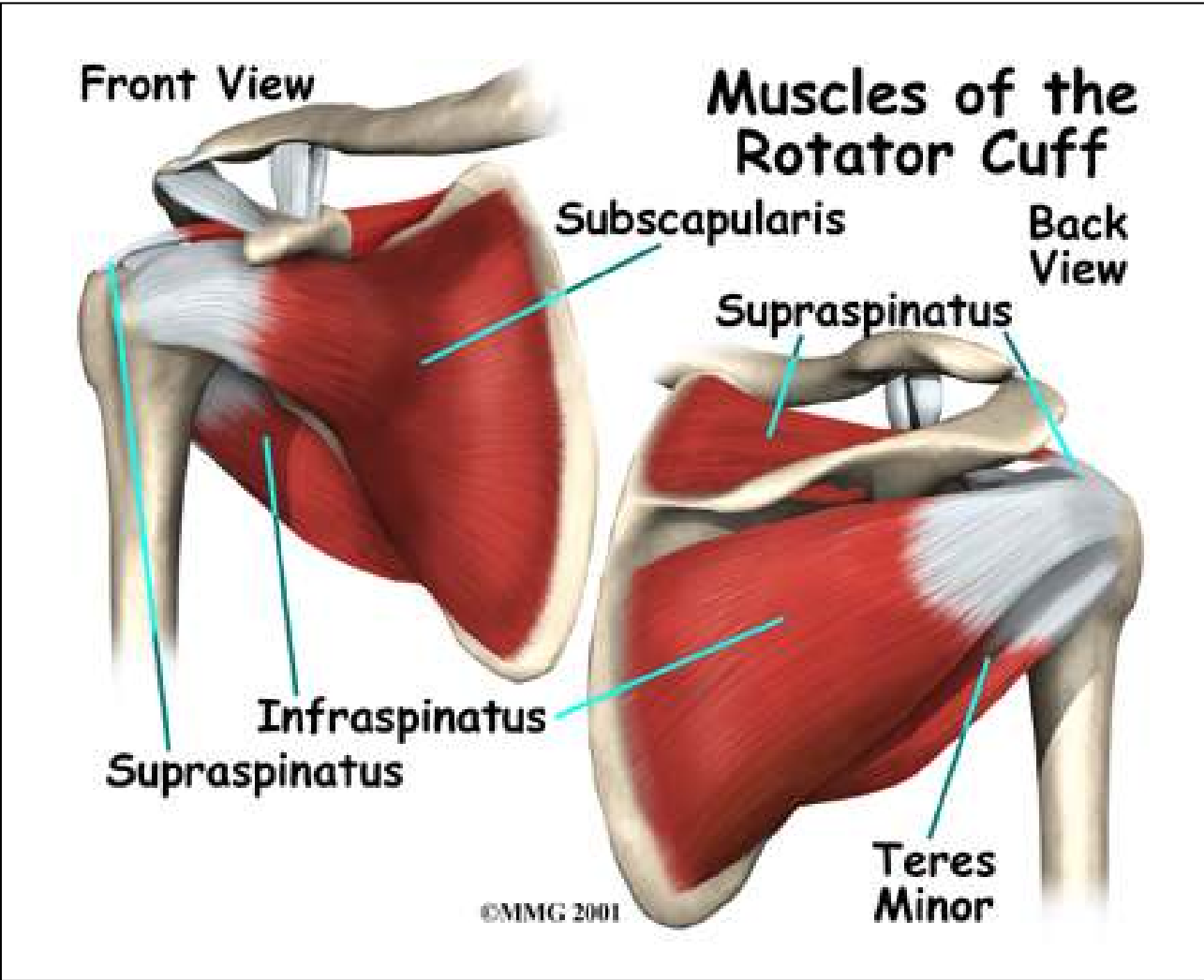




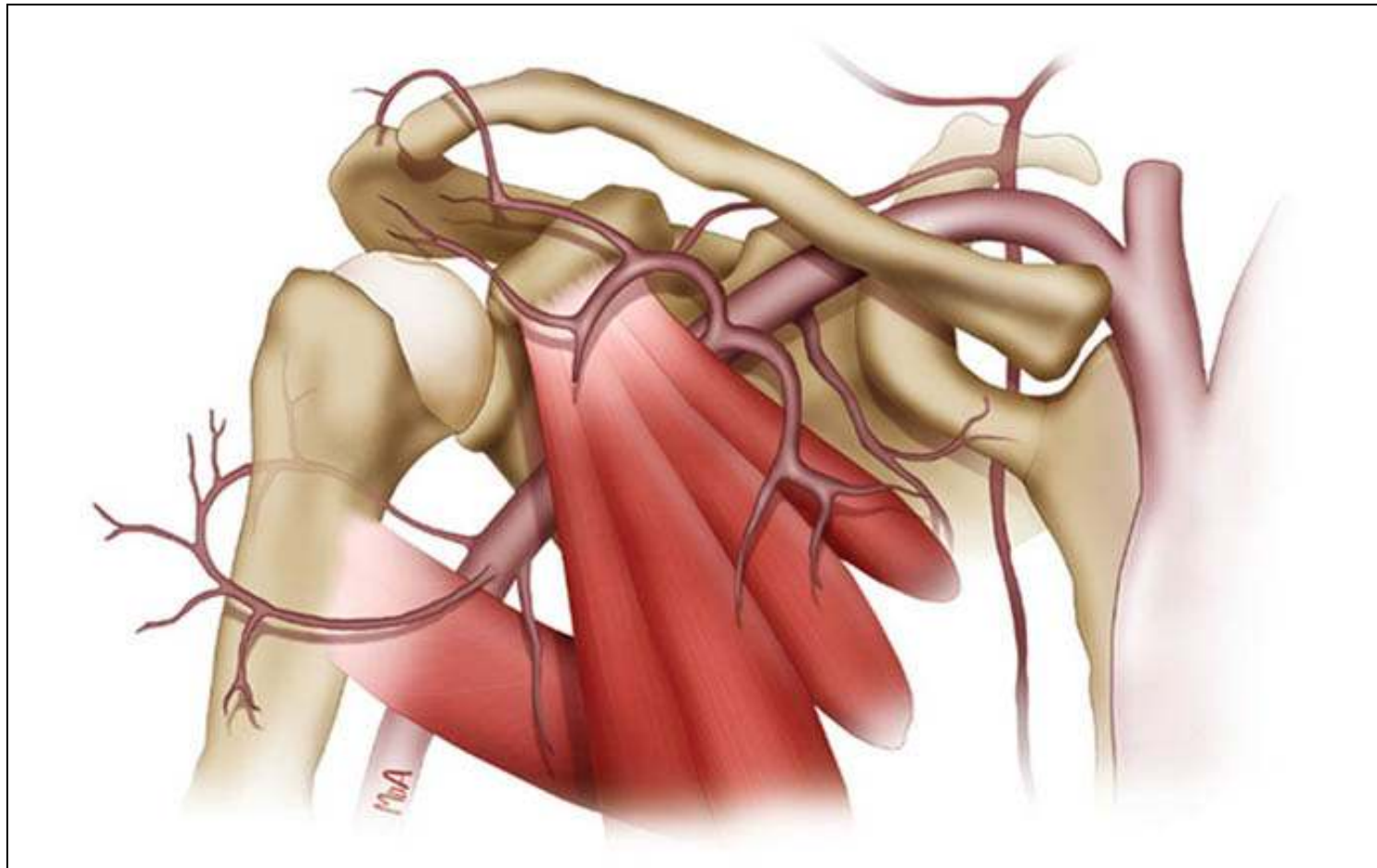
# Muscles - Anterior



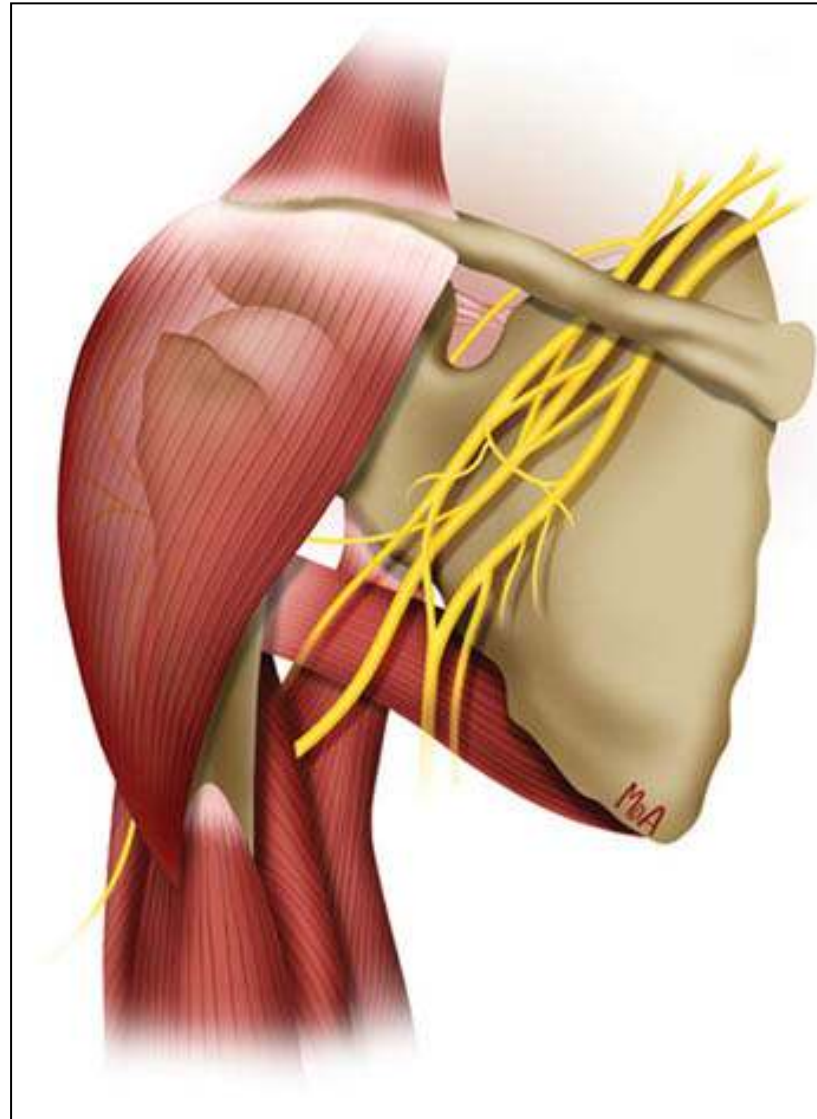
# Rotator cuff



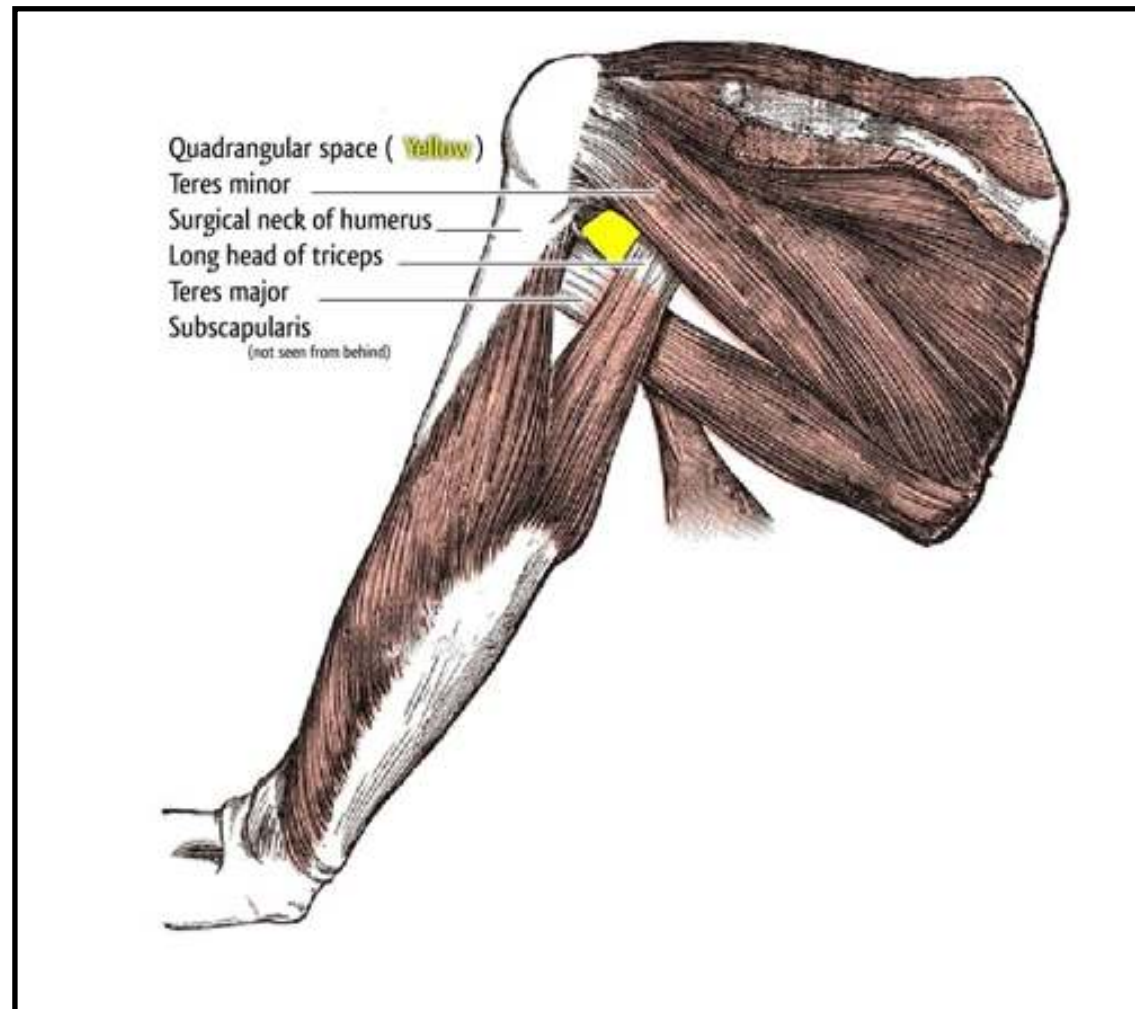
# Vascular anatomy



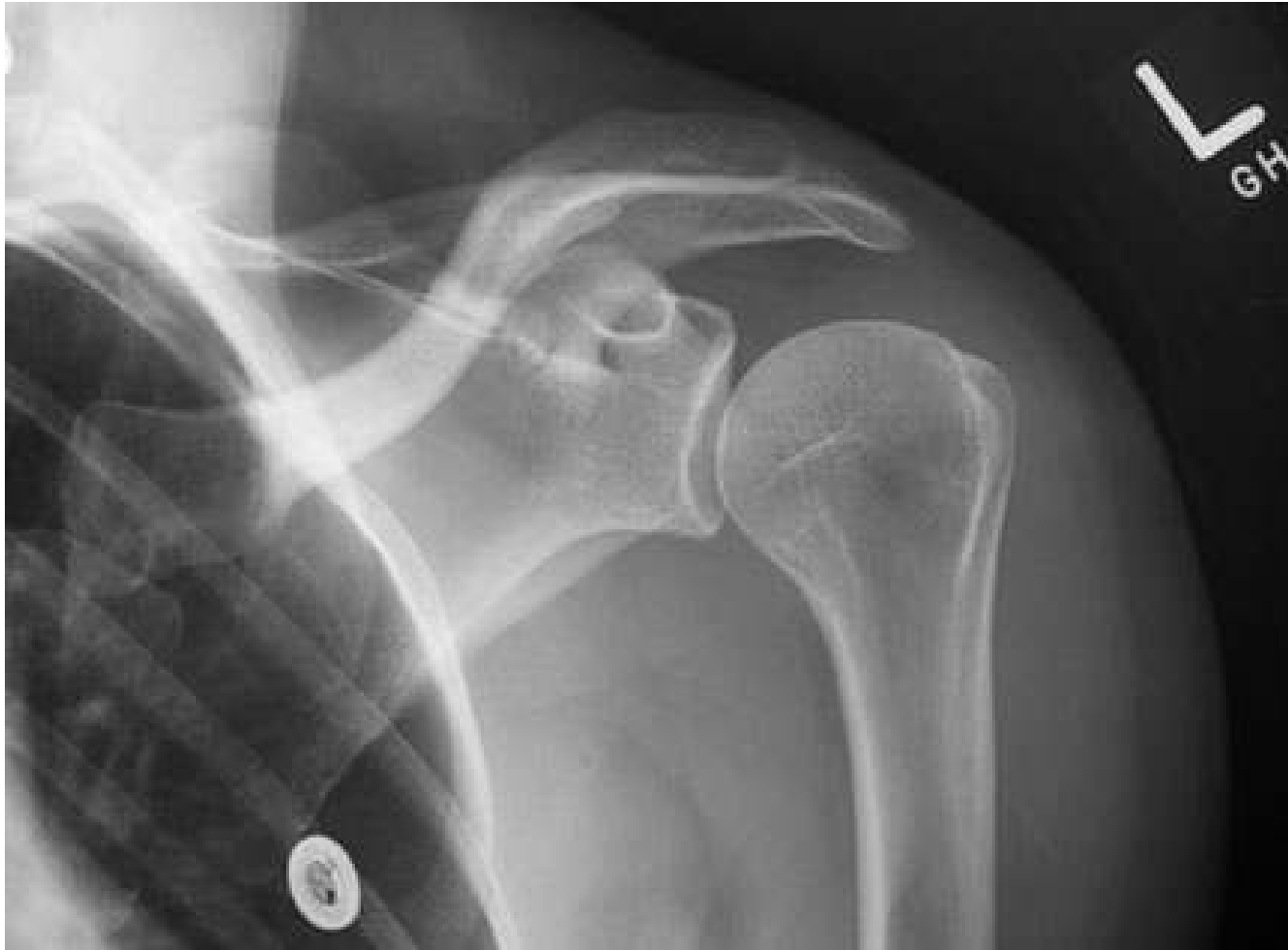# Brachial plexus



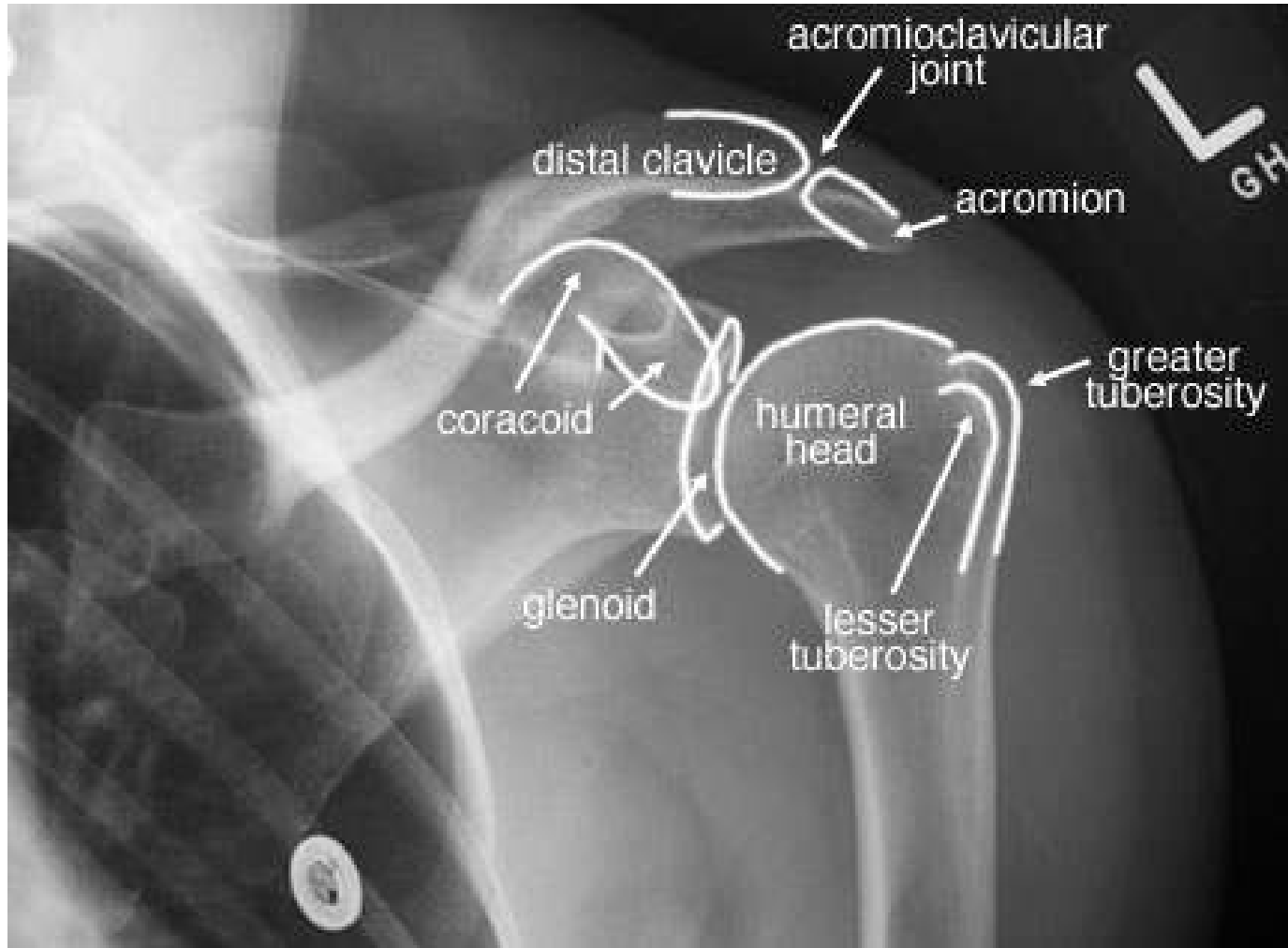
# Triangular and Quadrilateral Spaces



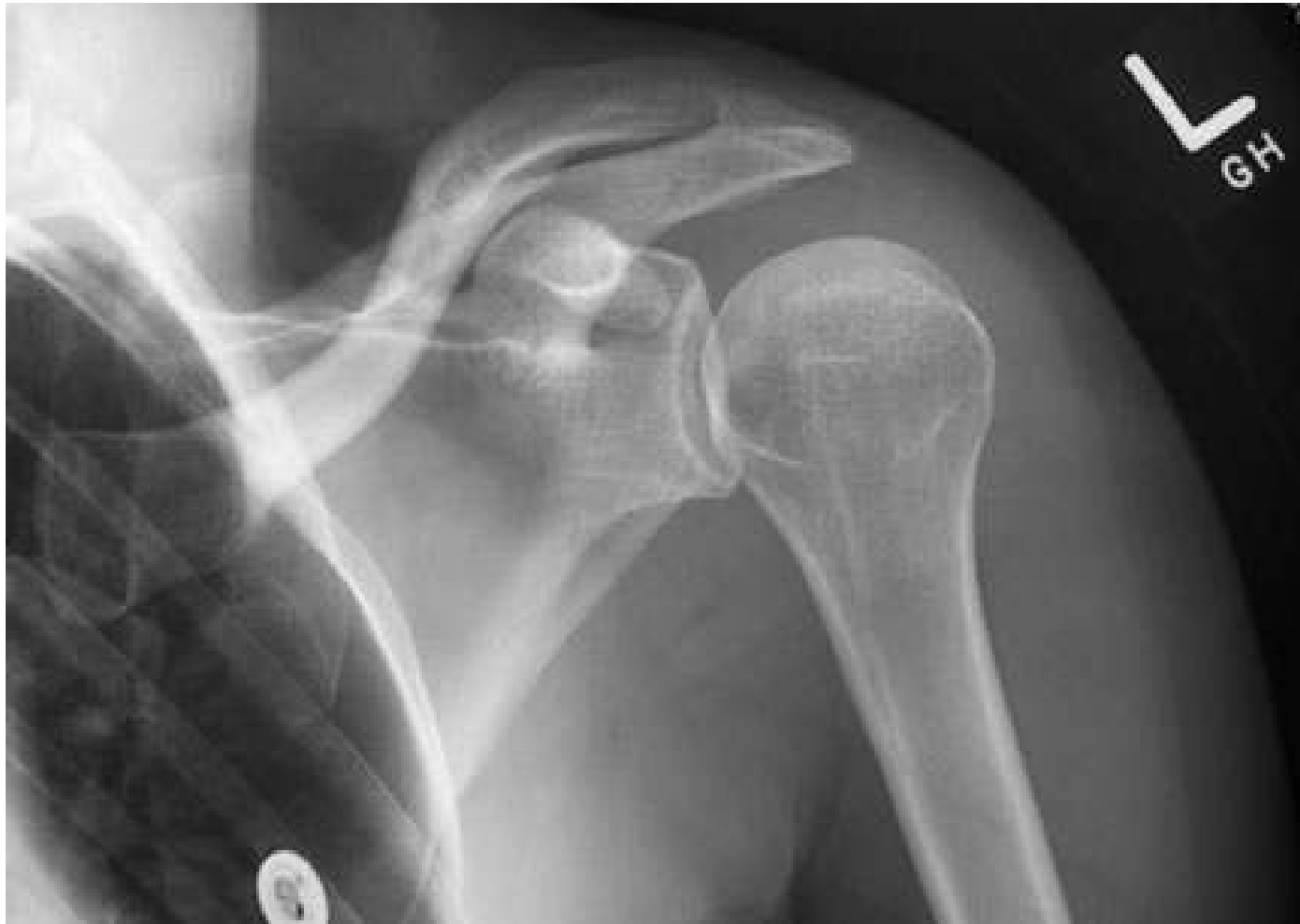# X-ray External Rotation



# X-ray External Rotation

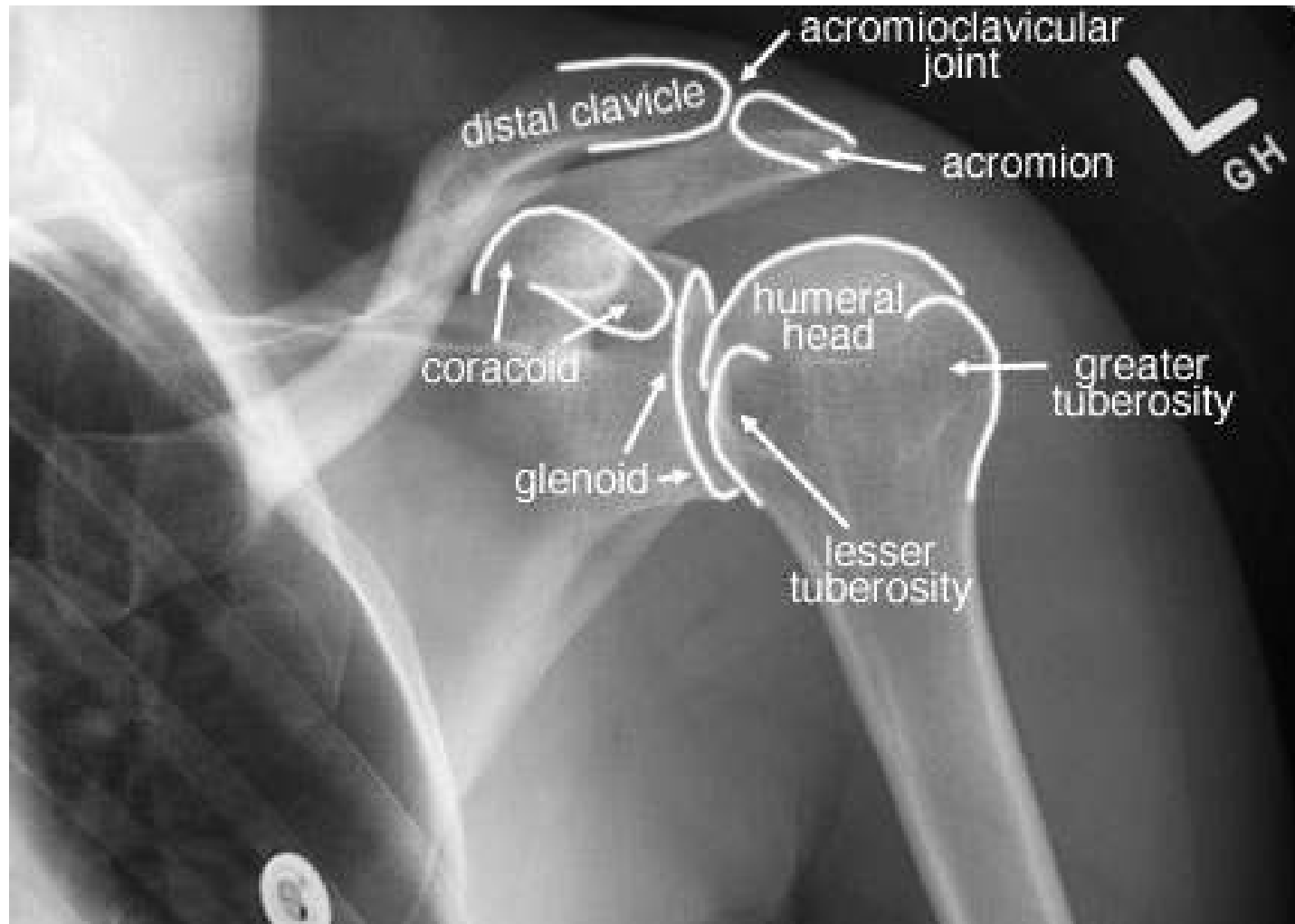


# X-ray Internal Rotation

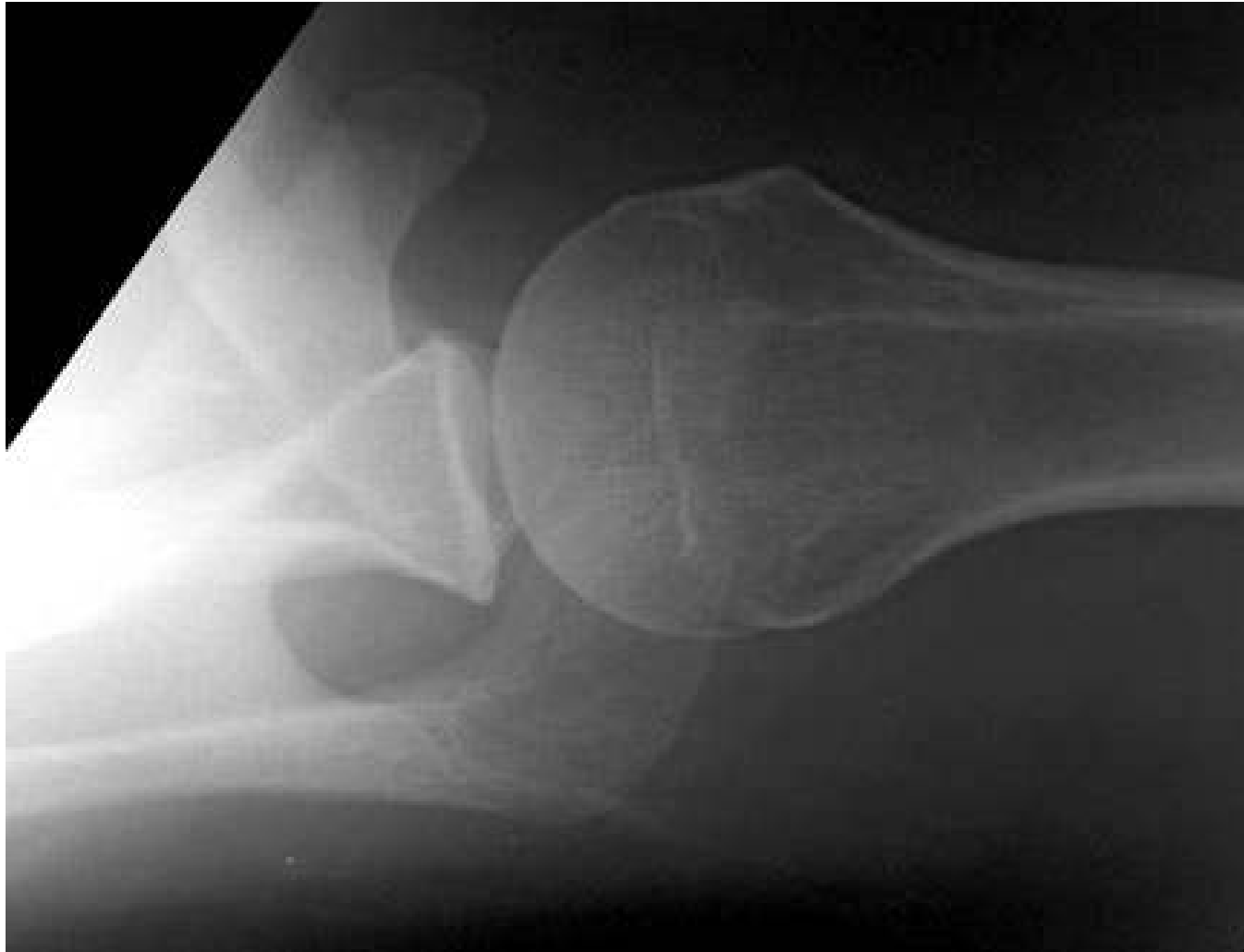



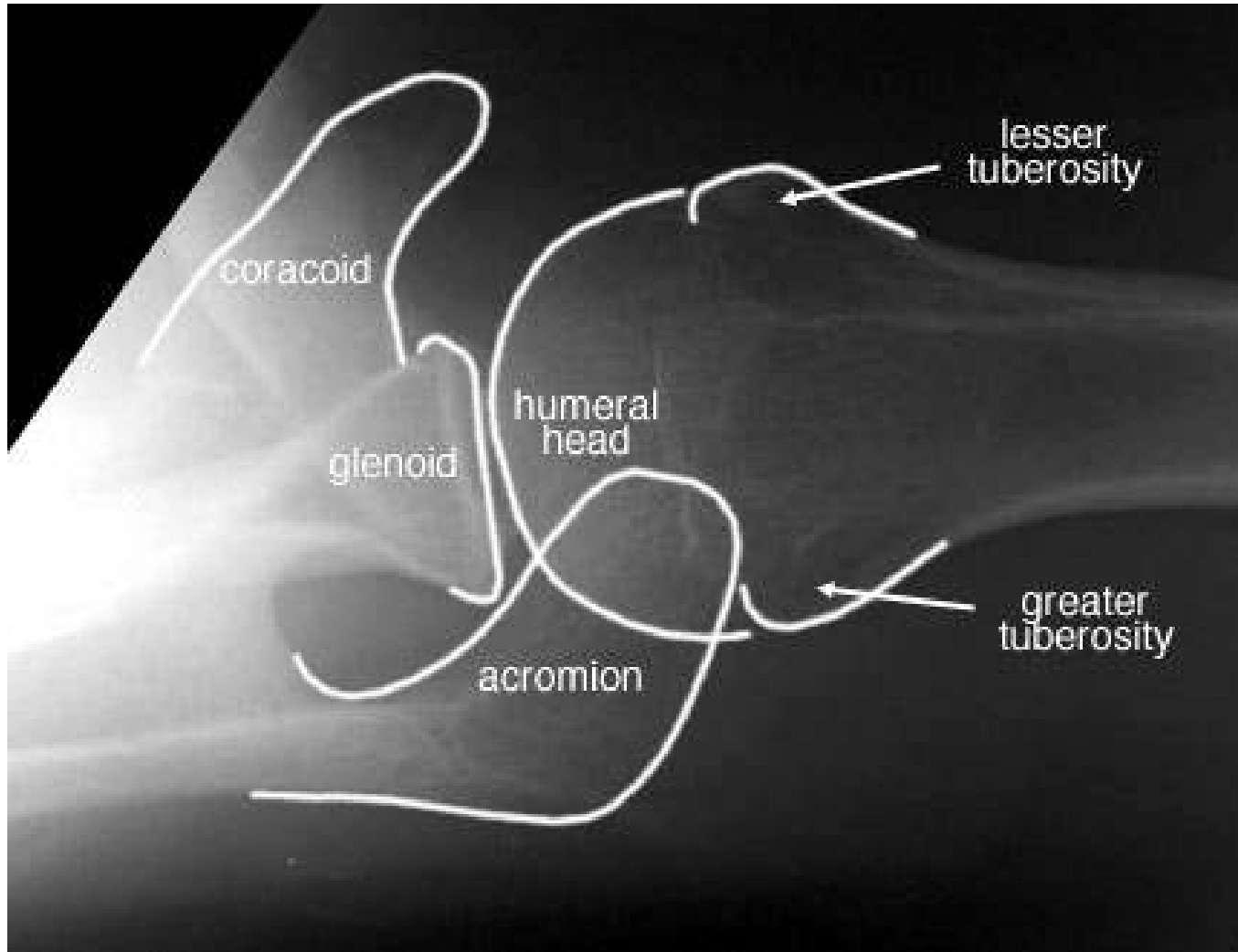
# X-ray Internal Rotation



# X-ray Axillary view



# X-ray Axillary view



# References

- Surgical Anatomy of the Rotator Cuff and the Natural History of Degenerative Periarthritis. A F DePalma. Clin Orthop Relat Res. 2008; 466:543–551.
- Humeral Insertion of the Supraspinatus and Infraspinatus. New Anatomical Findings Regarding the Footprint of the Rotator Cuff. T Mochizuki, et al. J Bone Joint Surg Am. 2009;91 Suppl 2 (Part 1):1-7.
- A cadaveric study on the anatomy of the deltoid insertion and its relationship to the deltopectoral approach to the proximal humerus. S Klepps. J Shoulder Elbow Surg. 2004; 13 (3): 322-7.
- An Anatomic Study of the Cephalic Vein in the Deltopectoral Shoulder Approach. C Radkowski. Clin Orthop Relat Res. 2006; 442: 139-142.
- MR Imaging Assessment of the Pectoralis Major Myotendinous Unit: An MR Imaging–Anatomic Correlative Study with Surgical Correlation. J Lee. Am J Rad. 2000; 174: 1371-1375.
- Collagenous microstructure of the glenoid labrum and biceps anchor. A Hill. J Anatomy. 2008; 212 (6): 853-862.