

Elbow Examination

Mr N.C.Bayliss
University Hospital North Tees

Elbow Examination. Mr. Ian Trail
Introduction

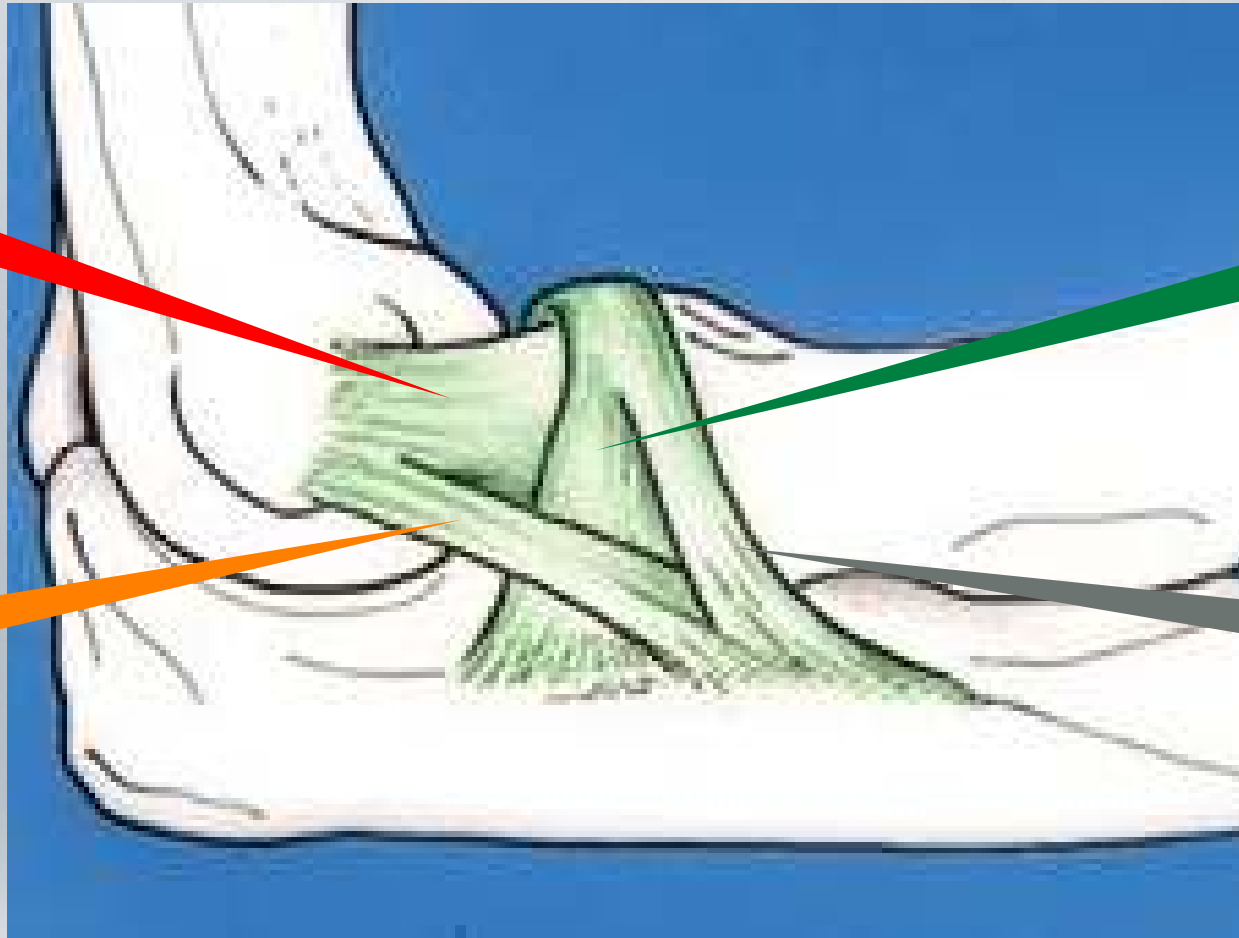
Elbow Examination

Lateral
(Radial)
Collateral

Annular
Ligament

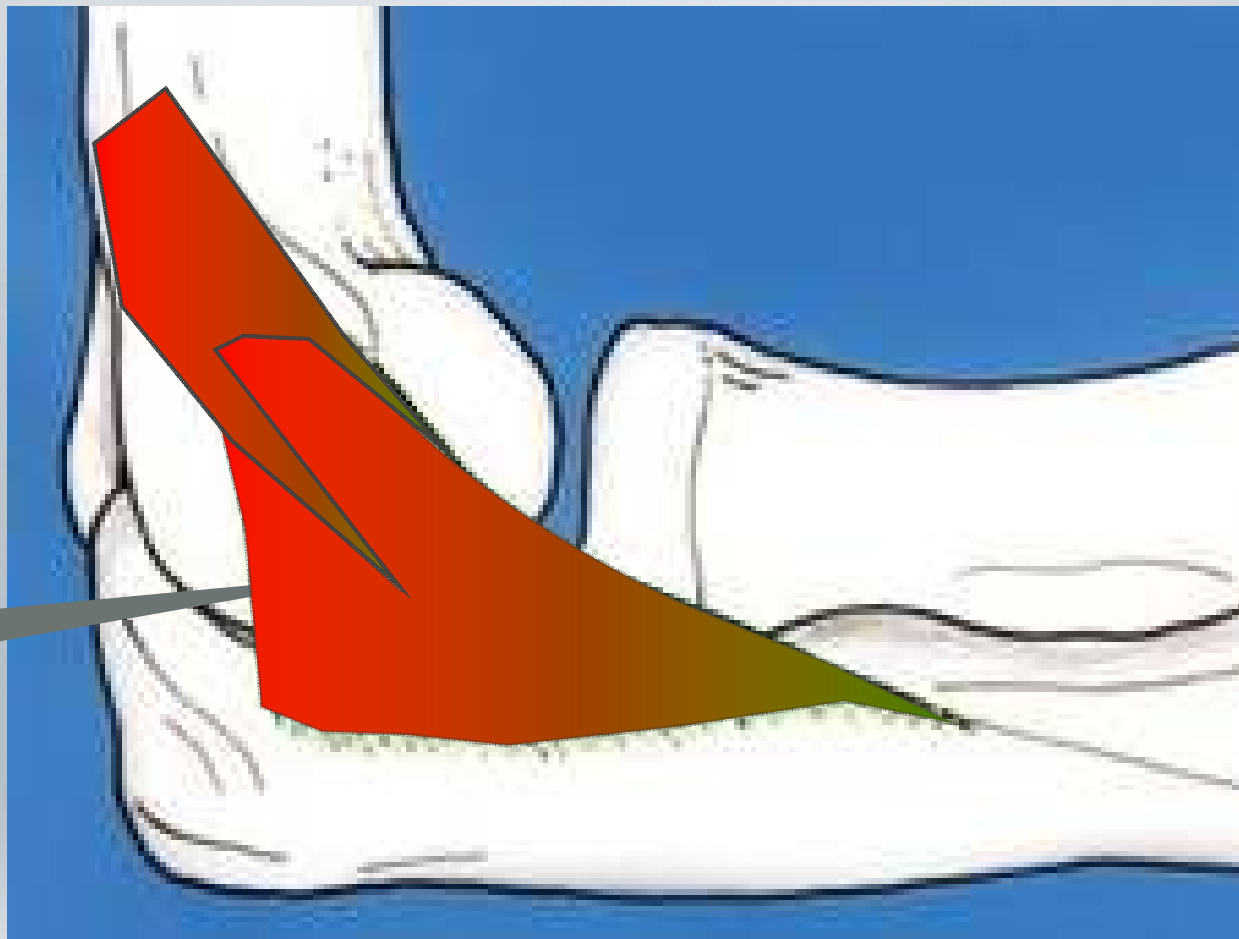Ulna
Collateral
Ligament

Accessory
Collateral
Ligament



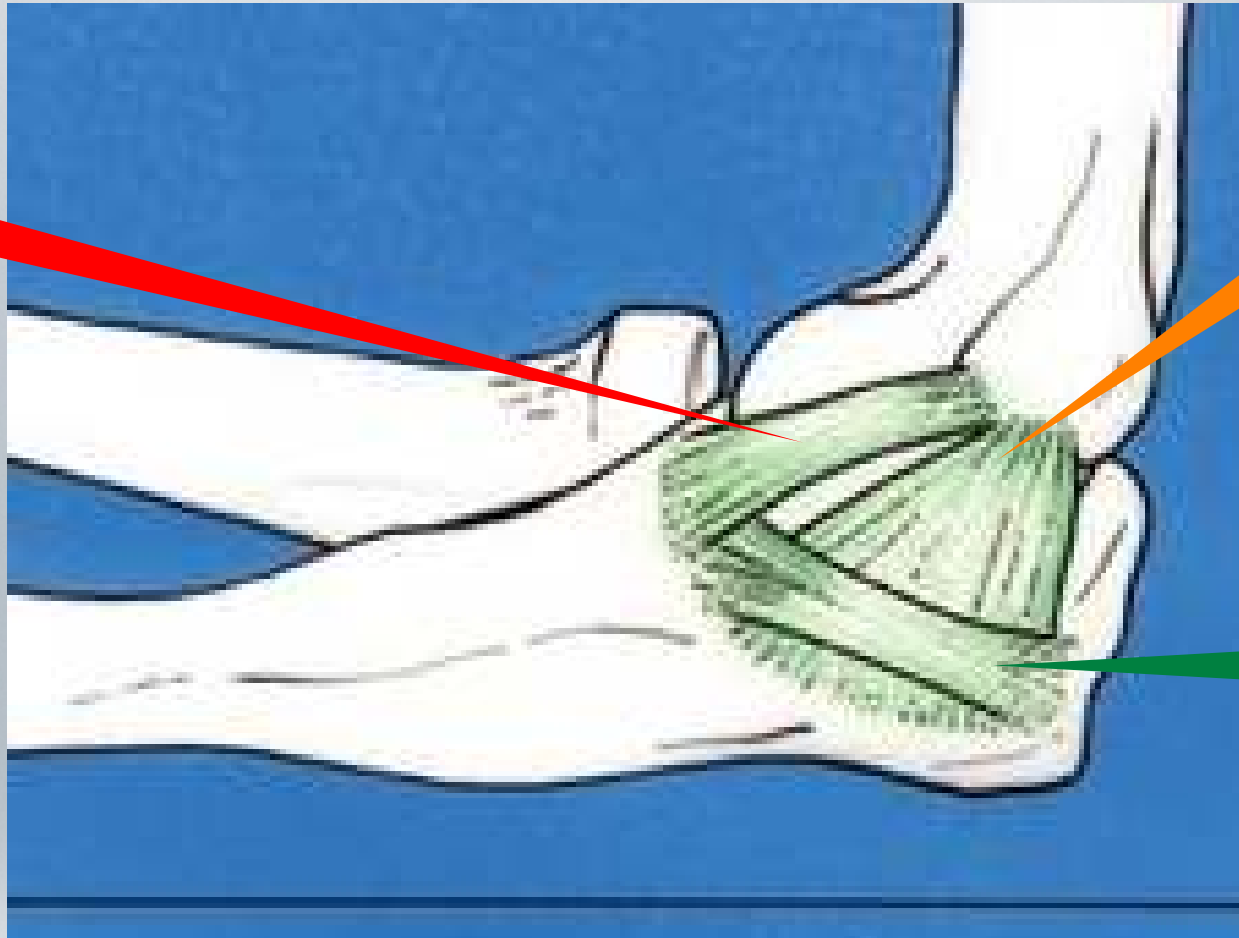Elbow Ligaments

Aconeus
Muscle



Elbow Ligaments


Anterior
Oblique
Bundle



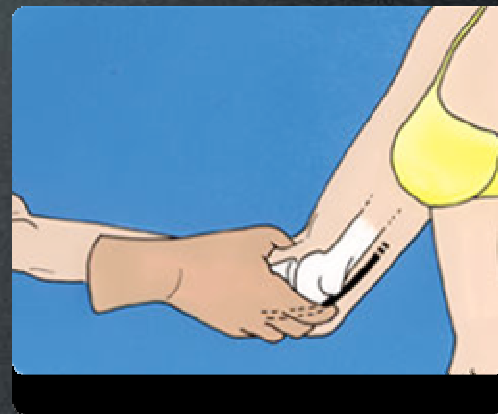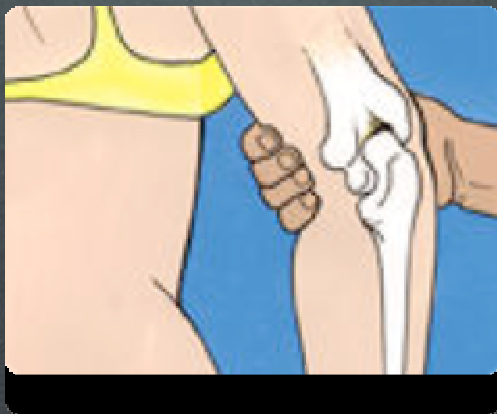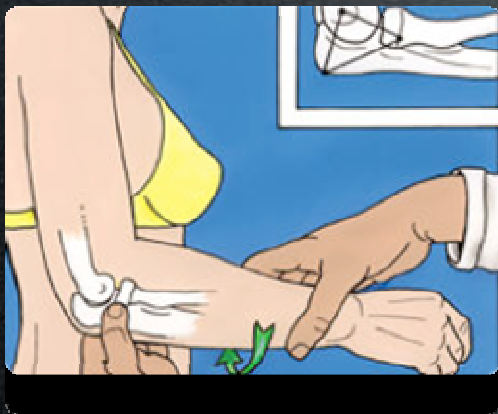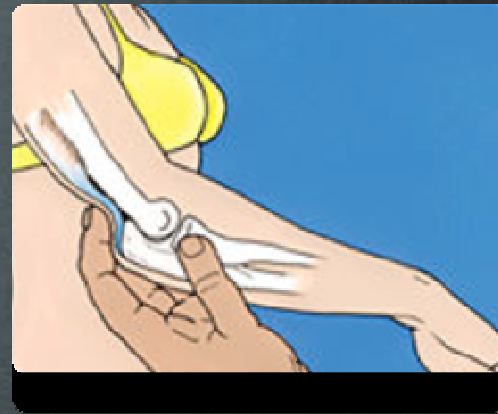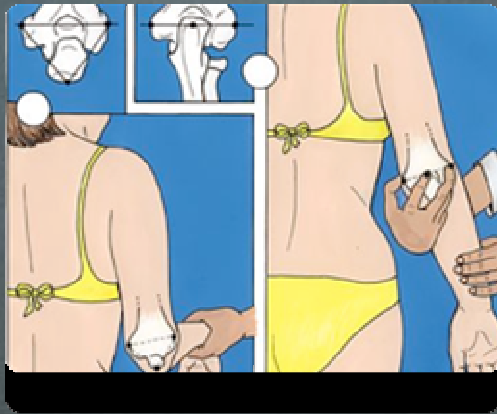
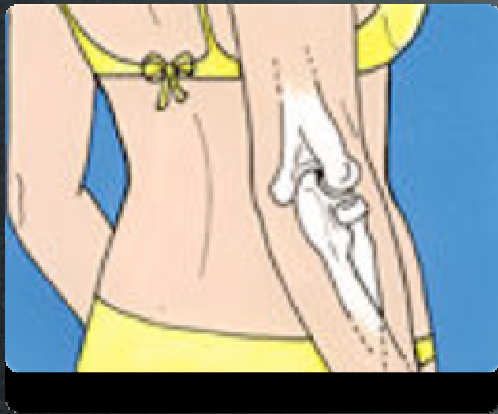
Posterior
Oblique
Bundle

Transverse
Oblique
Bundle

Elbow Ligaments



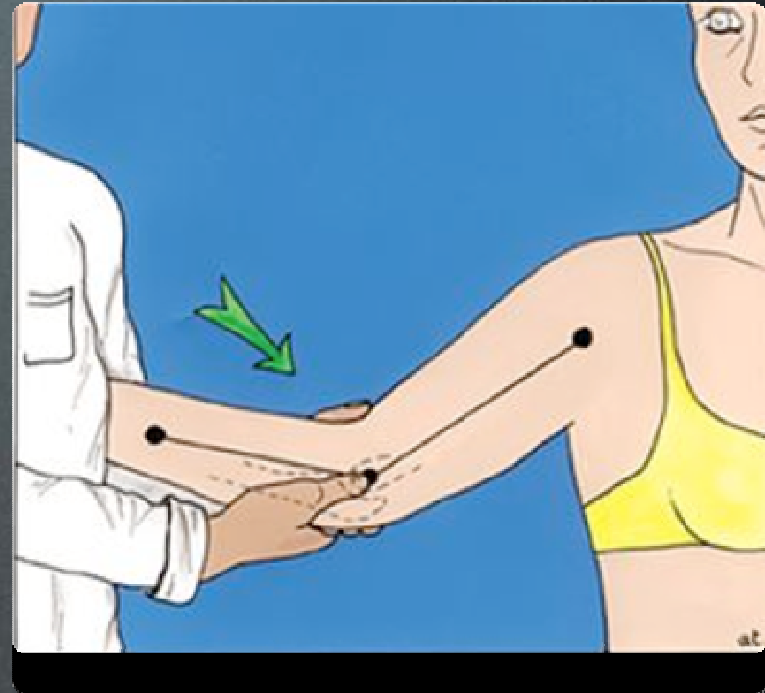
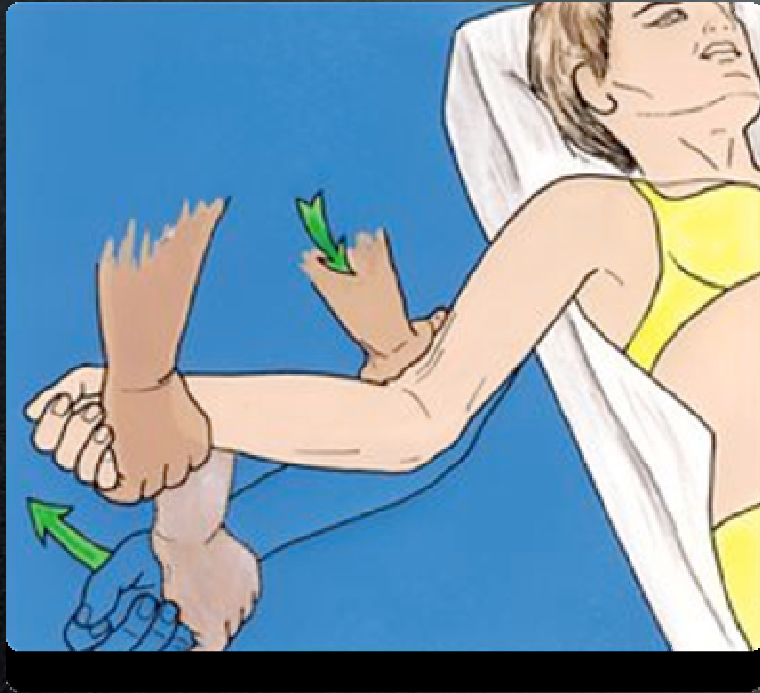
Look



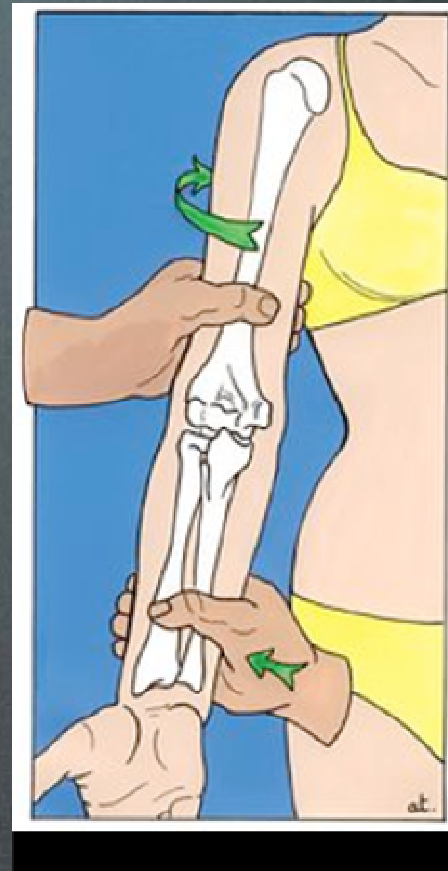
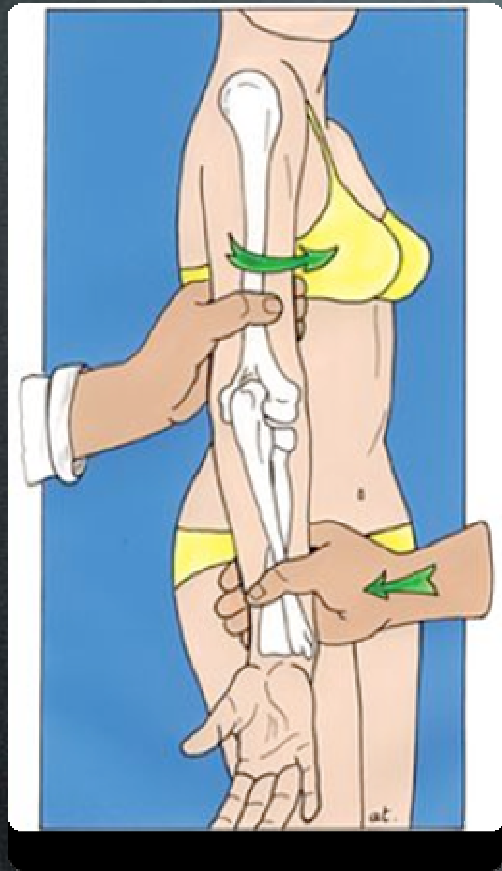
Feel

Move

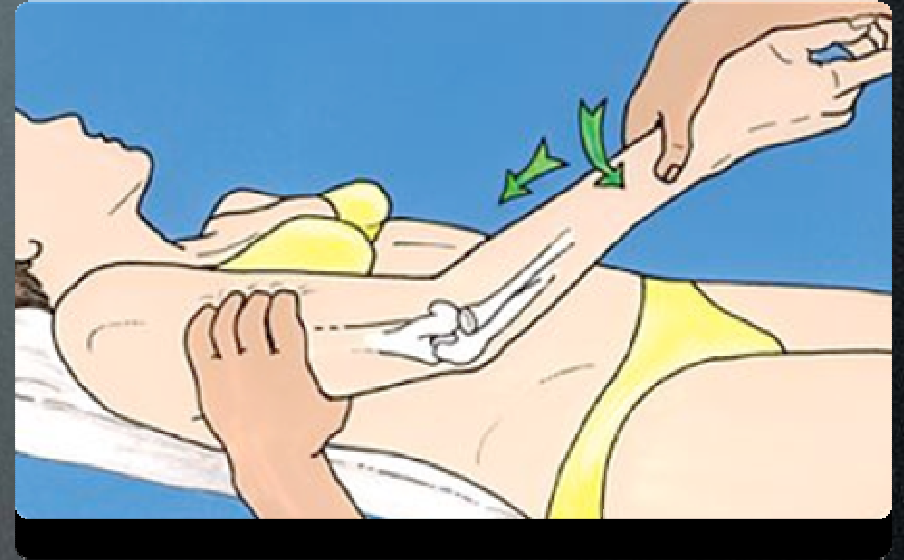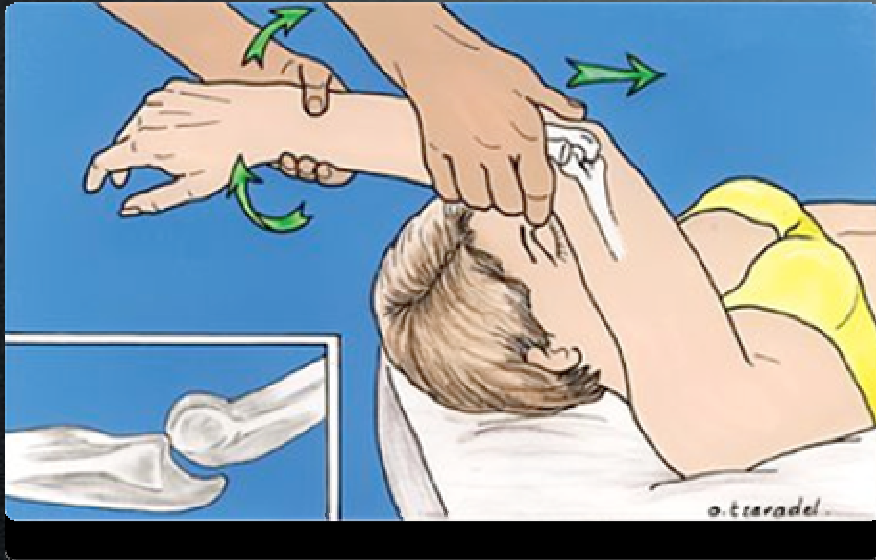- Flexion Normal : 0 - 140
 - Functional : 30- 120
- Pronation/Supination : 90/90
 - Functional : 50/50



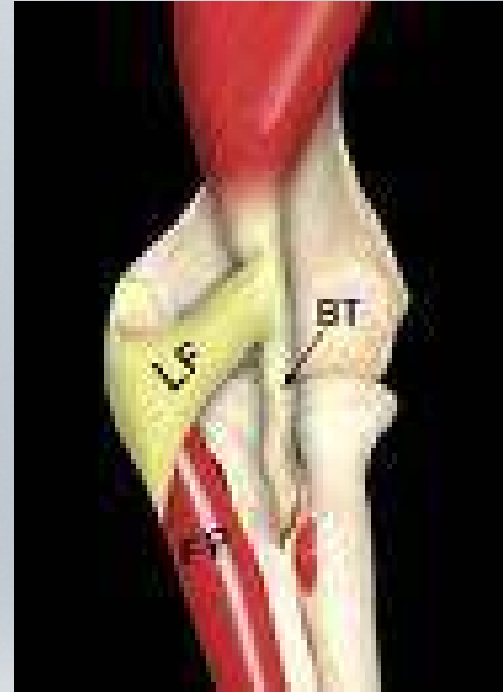
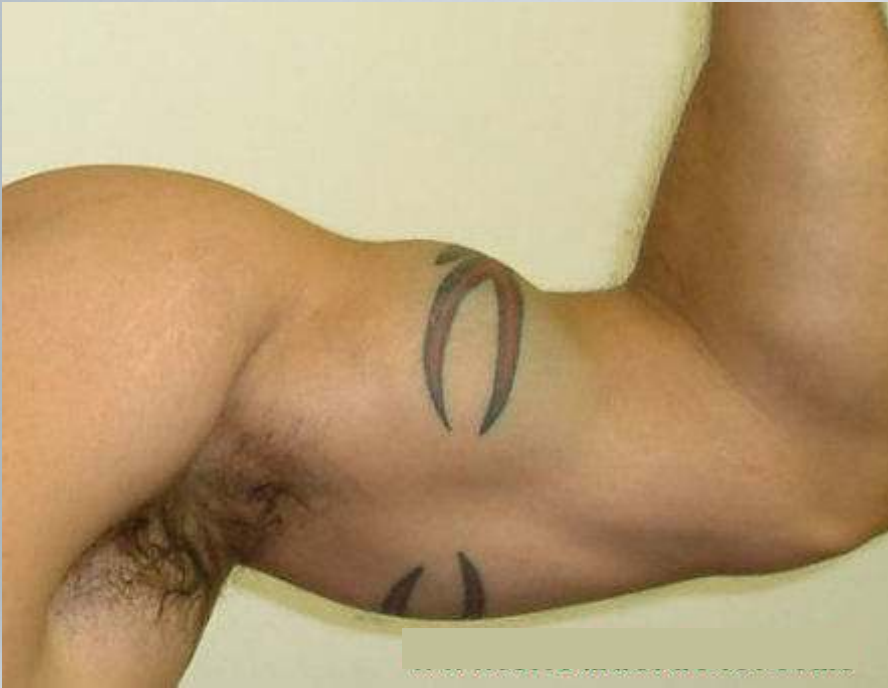Strain



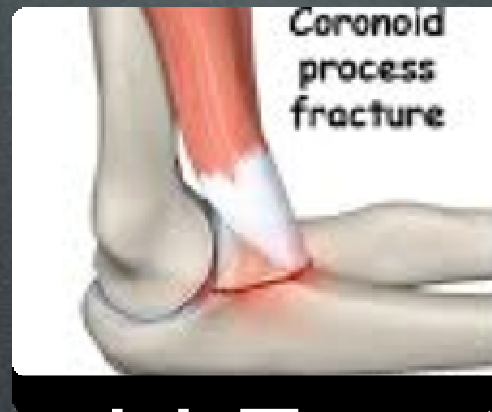Varus/Valgus Stability




Postero-lateral Instability



Distal Biceps Tear



Coronoid Fractures & Elbow Dislocation



And Finally....

THANKS

