

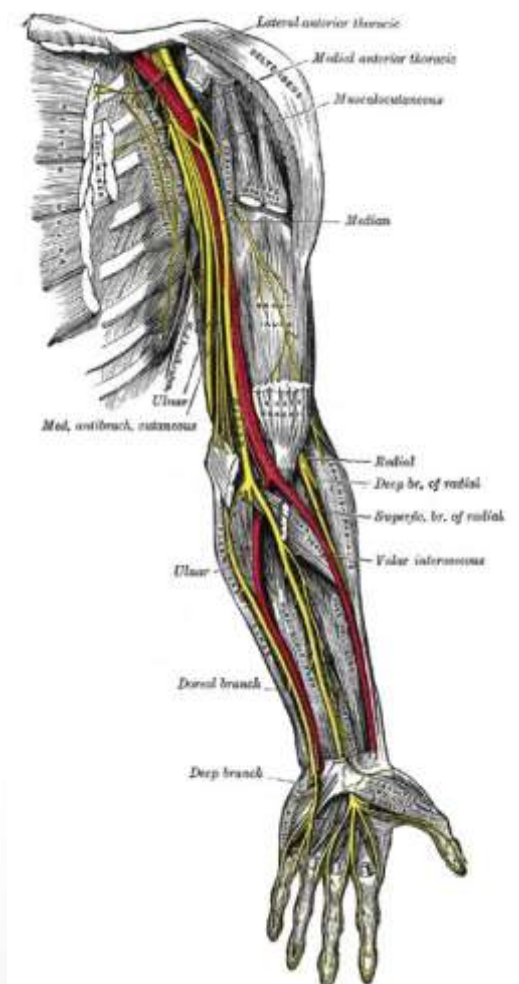
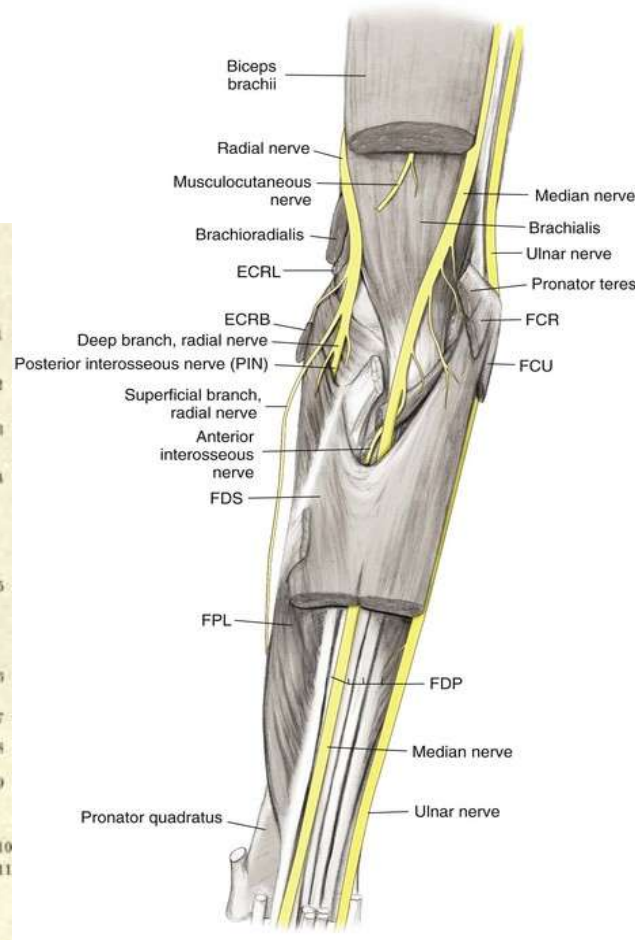
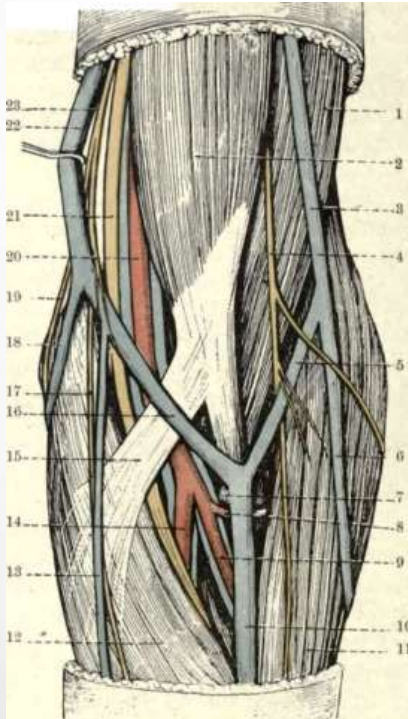
# Surgical approaches to the elbow

# Considerations

- Fracture fixation
  - ORIF distal humerus inc. surpacondylar fractures
  - ORIF olecranon
  - ORIF radial head
  - Terrible triad
- Radial head replacement
- NV exploration
- Biceps repair
- Total elbow replacement

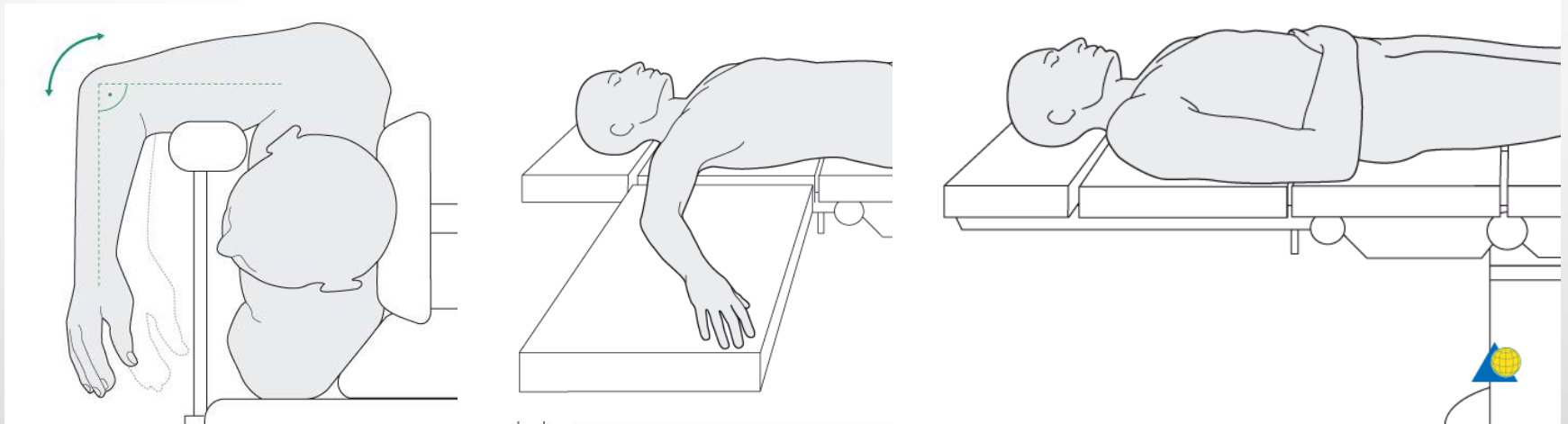
# Hazards

- Median n, Ulnar n, Radial n, Post interosseous n
- Brachial a
- “Safe Zones”



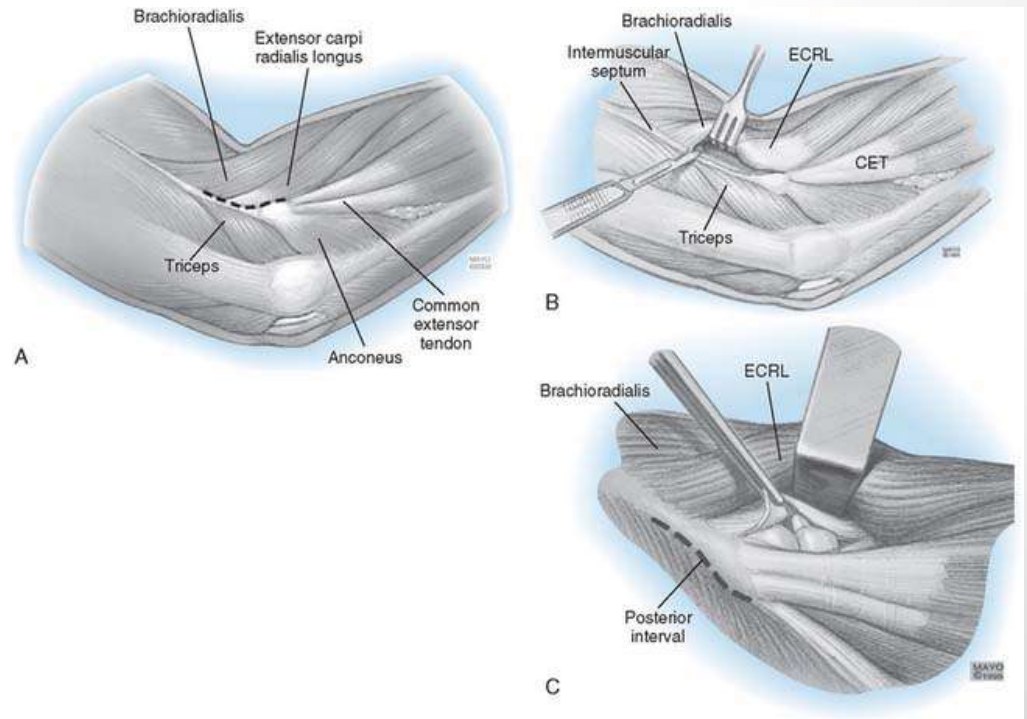
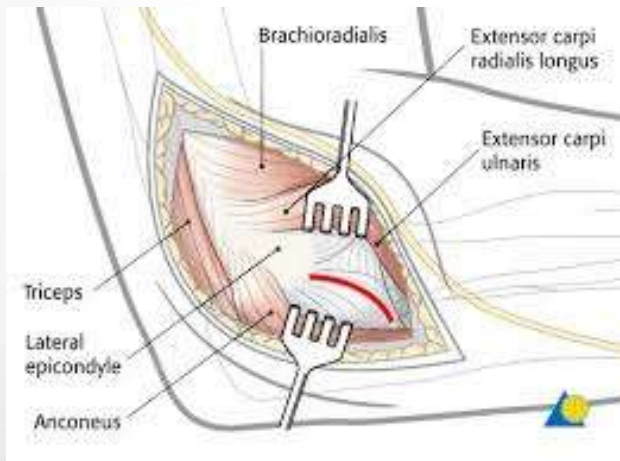
# Position

- Supine with arm board
- Prone arm over post
- Lateral decubitus, arm over post
- High arm tourniquet



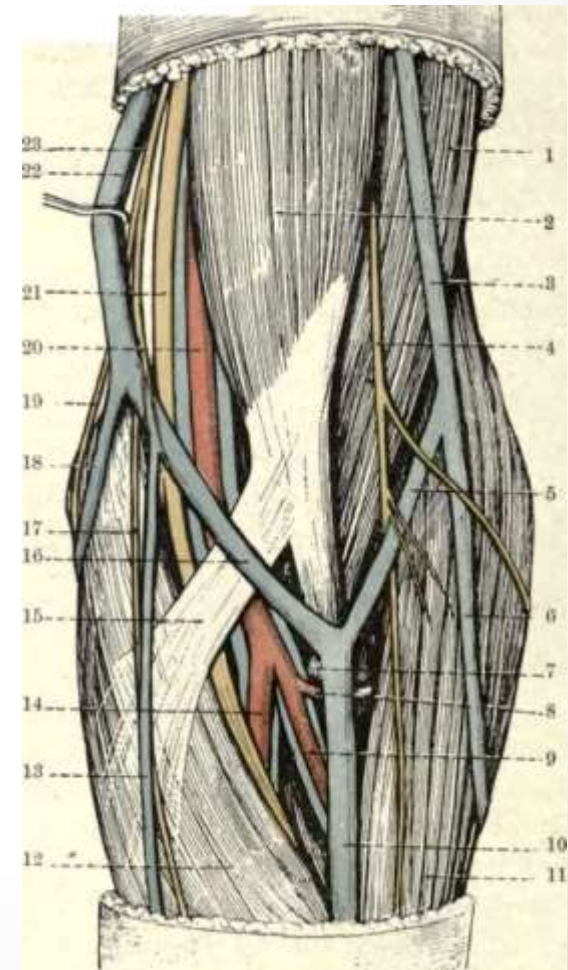
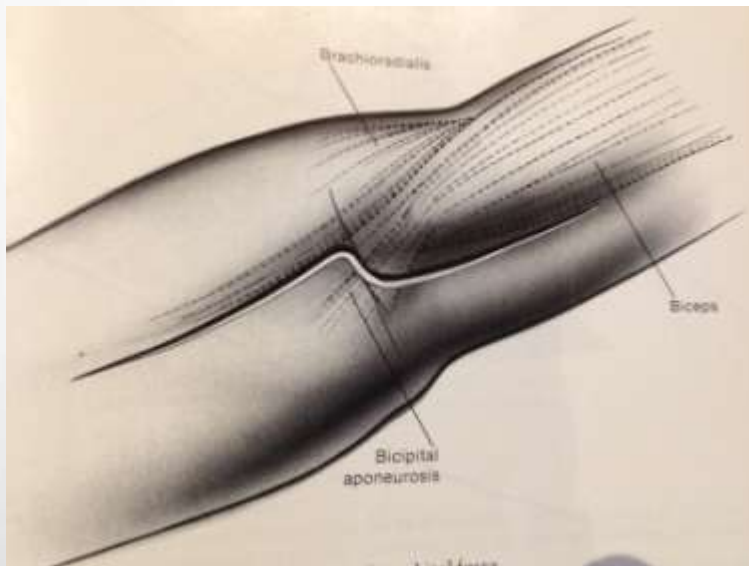
# Lateral approach

- Kocher's
- Anconeus and ECU
- Lat collateral, annular ligament – REPAIR!
- Supinator



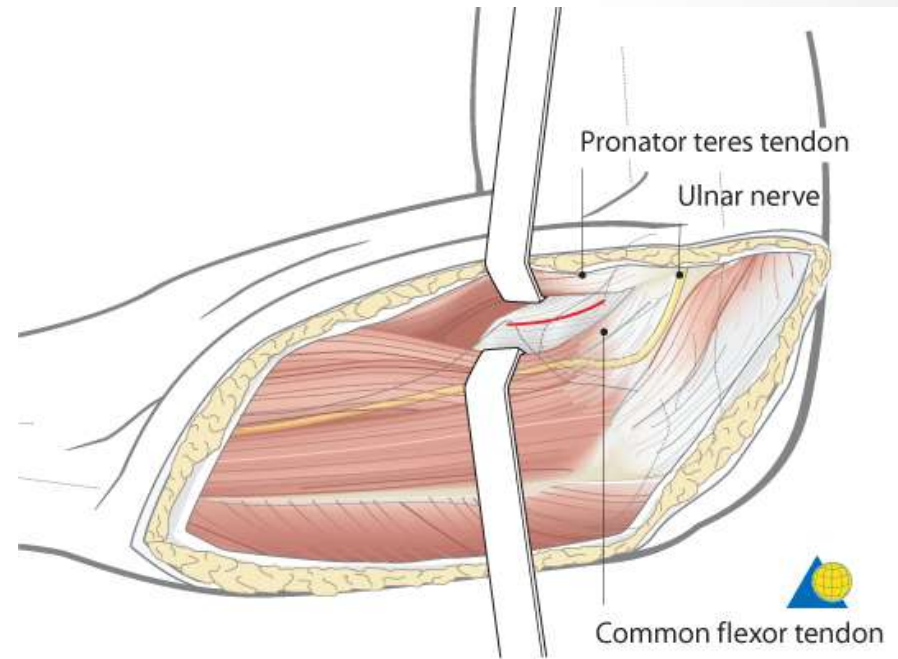
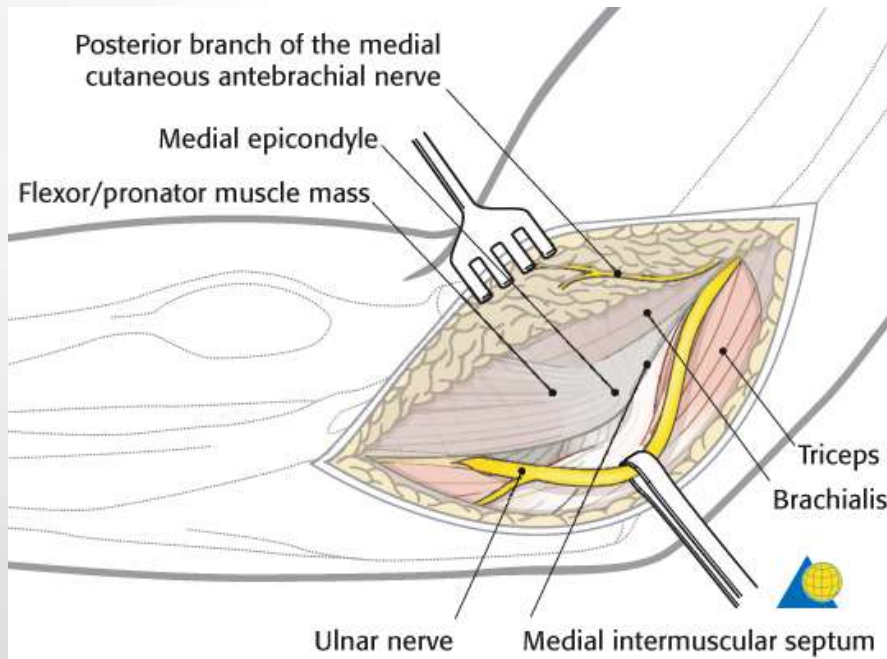
# Anterior approach

- Lazy “S”, medial proximal, lateral distal
- Antecubital v, lat cut n forearm
- Distal biceps
- Brachial a, median n
- Brachialis, ant capsule



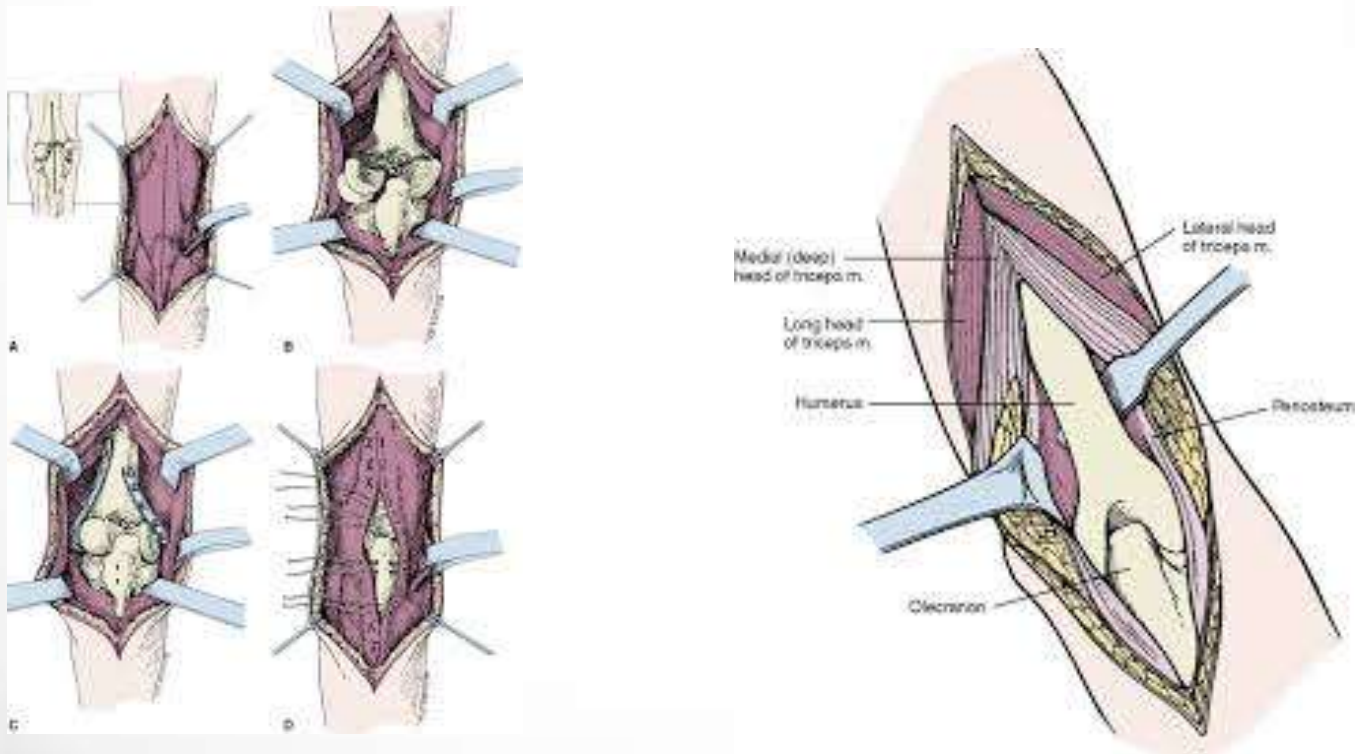
# Medial approach

- Ulnar n
- Pronator teres & brachialis
- Anterior capsule and coronoid



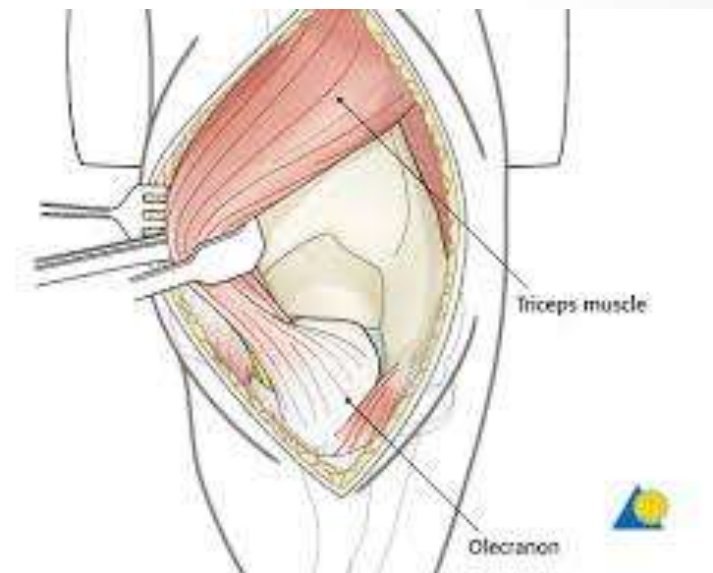
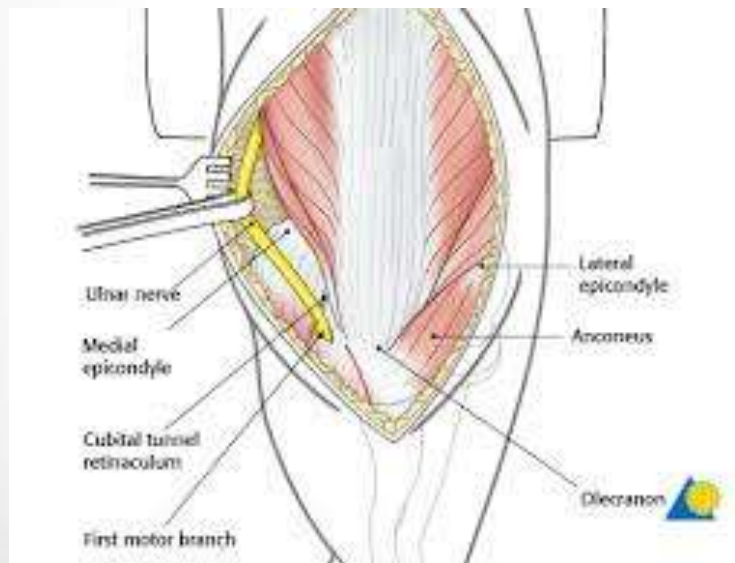
# Posterior approach

- Triceps
- Ulnar n, medial epicondyle
- Radial n proximally, lateral intermuscular septum



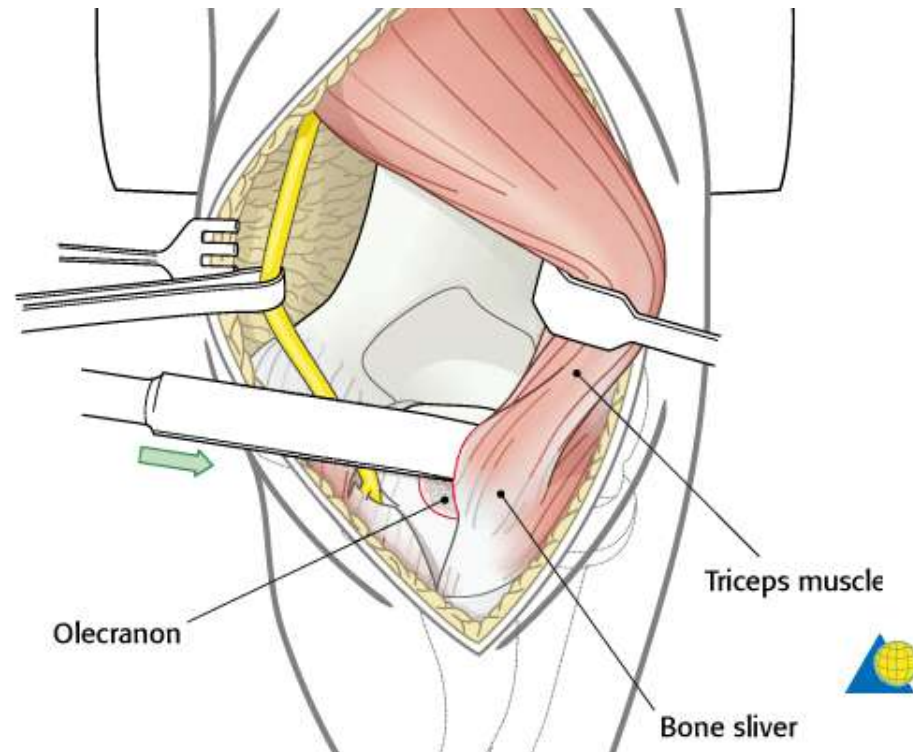
# “Triceps on”

- Create windows lateral or medial to triceps
- Beware ulnar n medially
- Supracondylar fracture



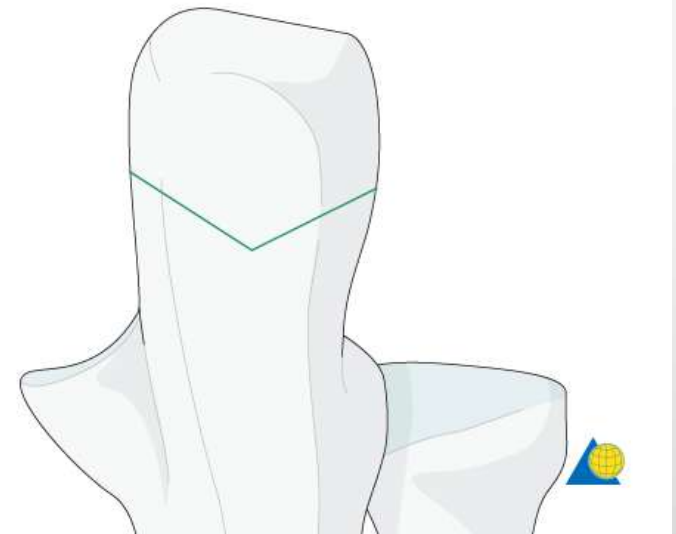
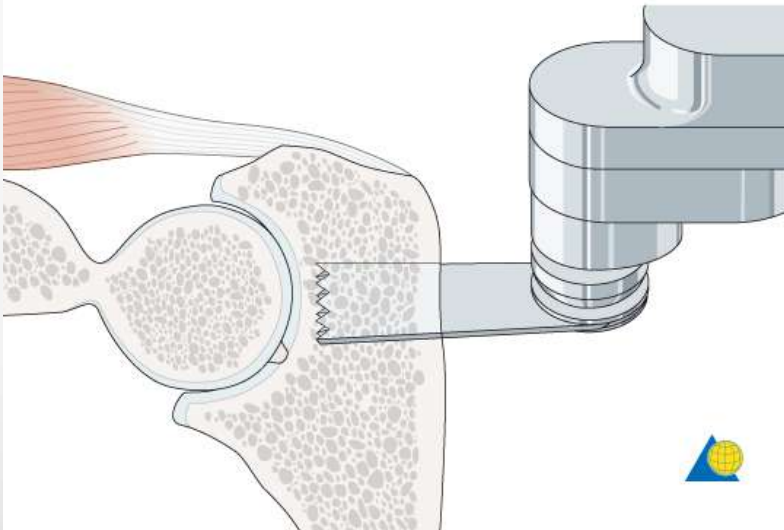
# “Triceps elevating”

- Slide triceps off to displace
- Exposure of elbow joint
- Transosseous suture for closure



# Transolecranon

- Chevron osteotomy, apex distal
- Saw cut of bone,
- Osteotome for completion
- ORIF closure – T band or Plate



# Boyd Thompson

- Both bone prox forearm approach
- Anconeus, ECU from ulna
- Supinator detachment, beware PIN
- Interosseous membrane and radius

