

# Periprosthetic Fractures of the Hip

Mr Paddy Duffy  
Darlington Memorial Hospital



County Durham and Darlington **NHS**  
NHS Foundation Trust



# Overview

- Aetiology
- Epidemiology
- Classification
- Management
- Results

# Aetiology

- Intraoperative
- Postoperative

# Intraoperative

- Occurs mainly during stem insertion
- Incidence (Primary)
  - Cemented 0.1-1% (Kavanagh Orthop Clin N Am 1992)
  - Uncemented 5.4% (Berry - Clin Orthop 1999)
- Incidence (Revision)
  - Cemented 3.6%
  - Uncemented 20.9% (Tsiridis – Injury 2003)

Lindahl - Injury. 2007 Jun;38(6):651-4.

# Avoid in the first place

- Pre operative Plan
  - Decreases chance of nasty surprises
  - Enables correct choice of weapon
- Careful Technique
  - Exposure
  - Osteotomise femur if necessary
  - Intraoperative radiographs

# Post Operative

- Incidence
  - NJR 4<sup>th</sup> annual report
    - 397 **hip revisions** for periprosthetic fractures (8% of all revisions, 5<sup>th</sup> commonest reason)
  - Doesn't include fixations
  - Likely to be a growing problem
    - Demographics
    - ? Reluctance of Trusts to undertake timely but loss making revision surgery

# Risk Factors

- Bone loss secondary to osteoporosis, loosening and osteolysis associated with low energy trauma (Cook et al, CORR 2008)
- High energy trauma (younger, better bone stock)
- Neuromuscular Conditions
- Multiply revised Hips
- Stress Risers
- ? Stem Design

# Classification

- Multiple – not all useful
- Ideally should help plan management
- Useful for research
- Low inter - and intra – observer variability

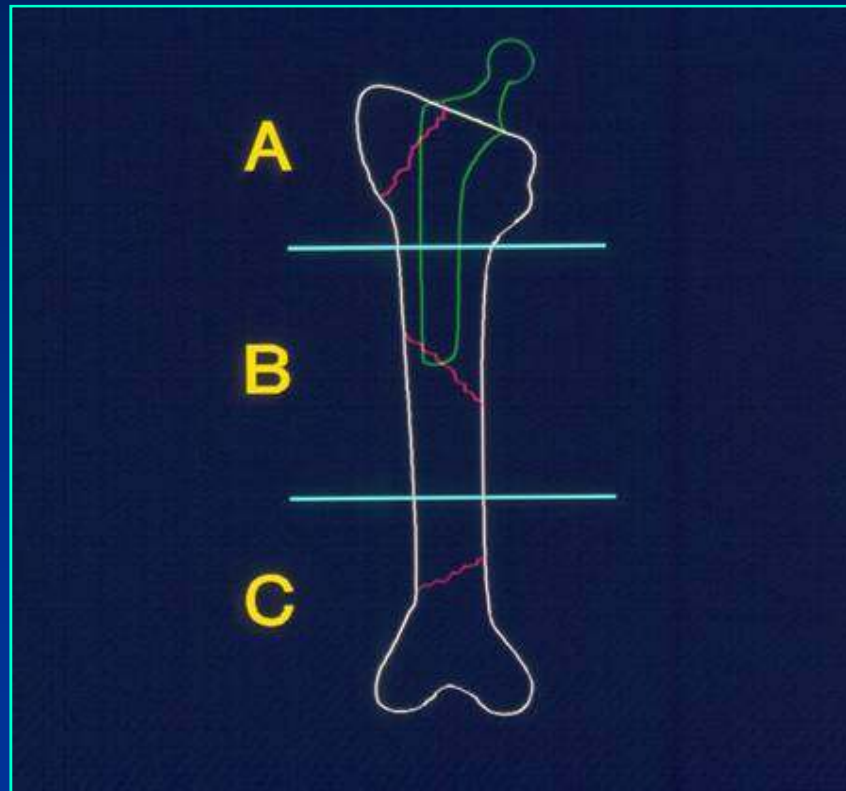
# Need to know

- Location
- Fixation
- Bone Stock

# Vancouver Classification

(Duncan and Masri Instr Course Lect. 1998; 47:237-42).

- Location



# Vancouver Classification

(Duncan and Masri Instr Course Lect. 1998; 47:237-42).

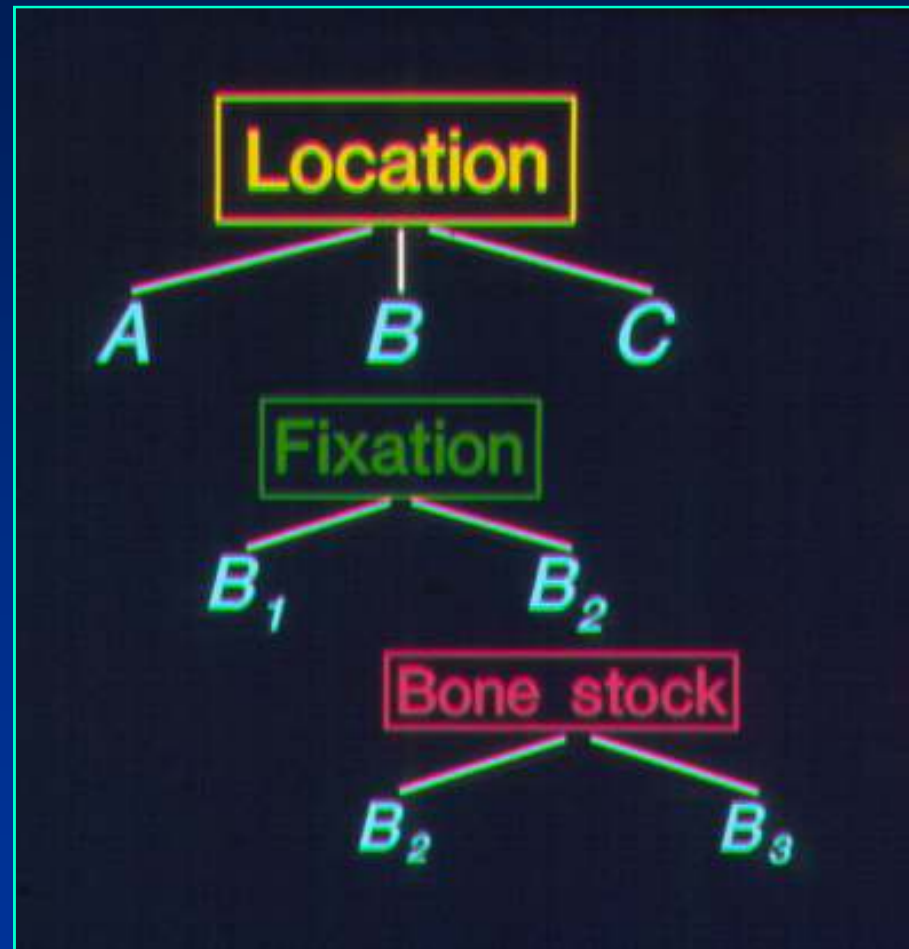
- Fixation
  - Applies to B type at +/- extending distal to stem
    - B1 well fixed
    - B2 and B3 loose

# Vancouver Classification

(Duncan and Masri Instr Course Lect. 1998; 47:237-42).

- Bone Stock
  - Applies to B2 and B3 Type
    - B2 adequate Bone Stock
    - B3 insufficient Bone Stock

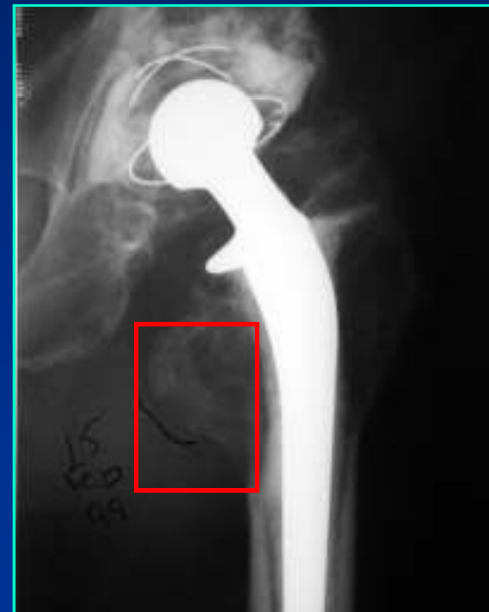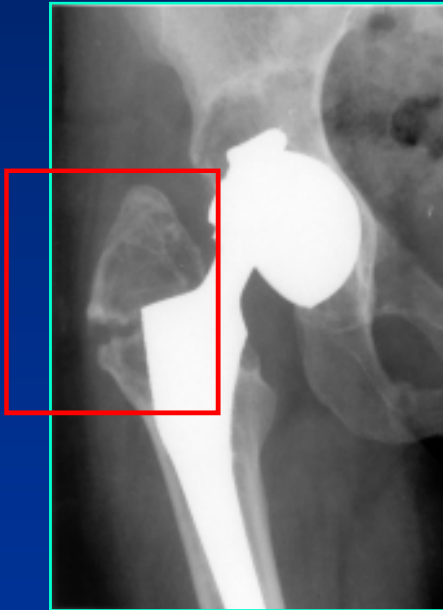
# Summary



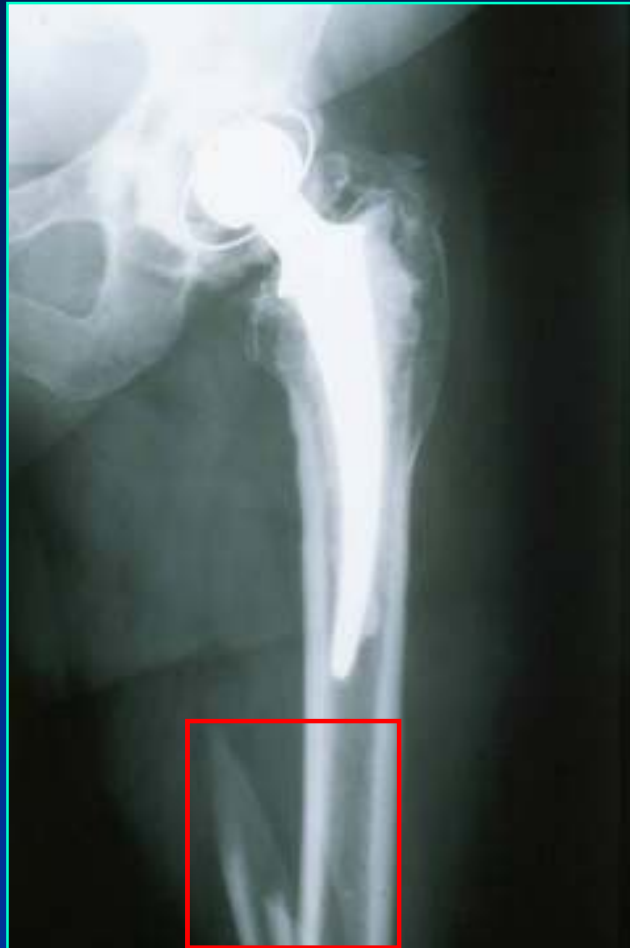# Type A

## – Sudivided

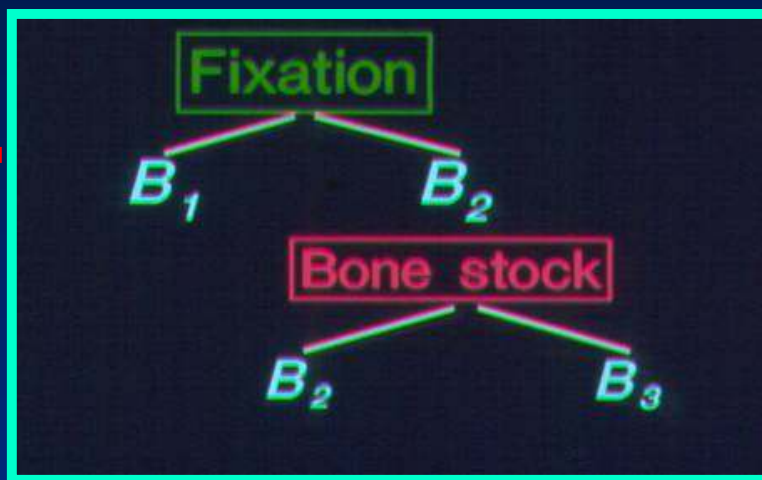
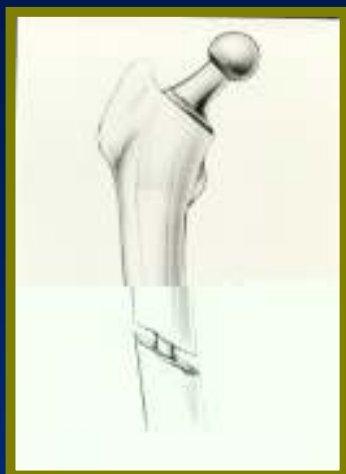- A<sub>G</sub> Greater Trochanter
- A<sub>L</sub> Lesser Trochanter



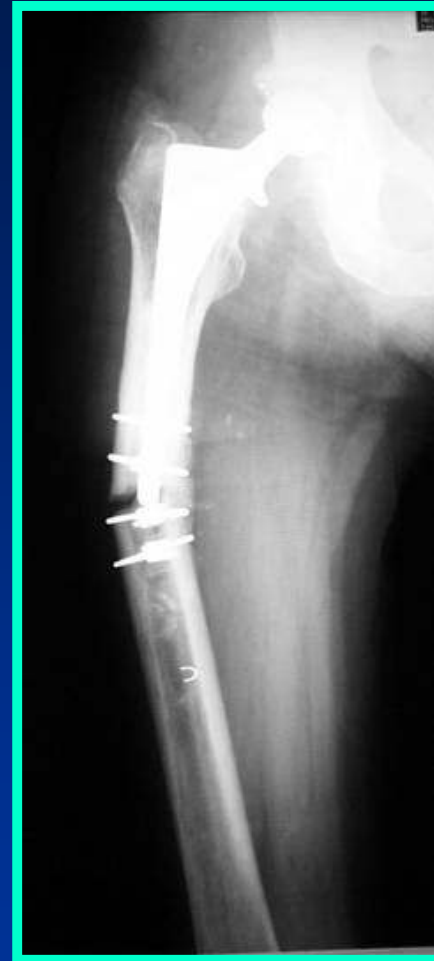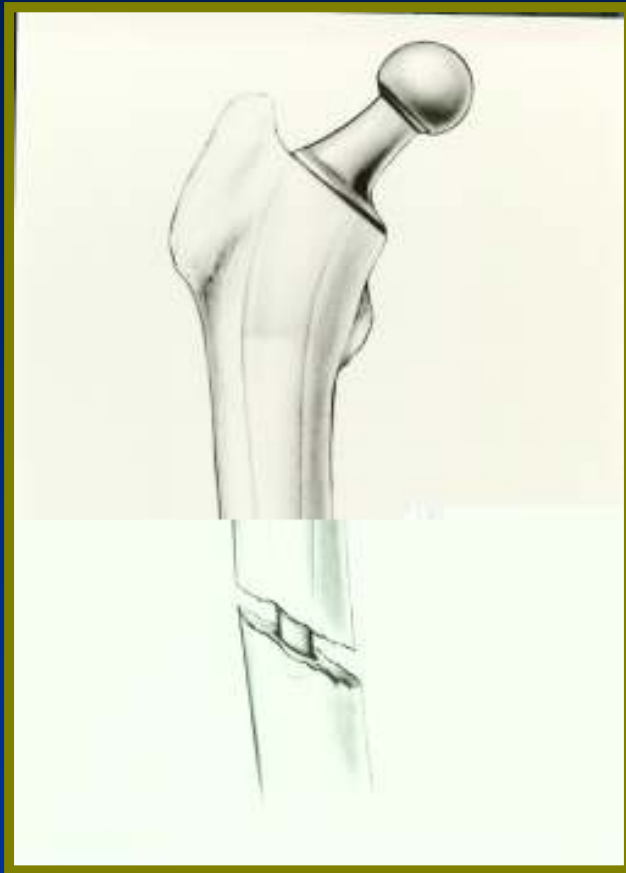
# Type C – distal to the implant



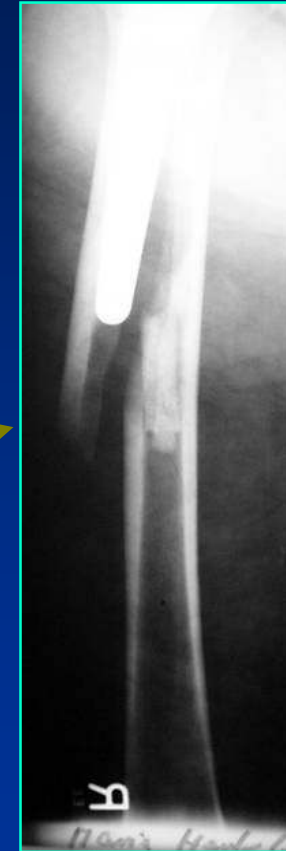
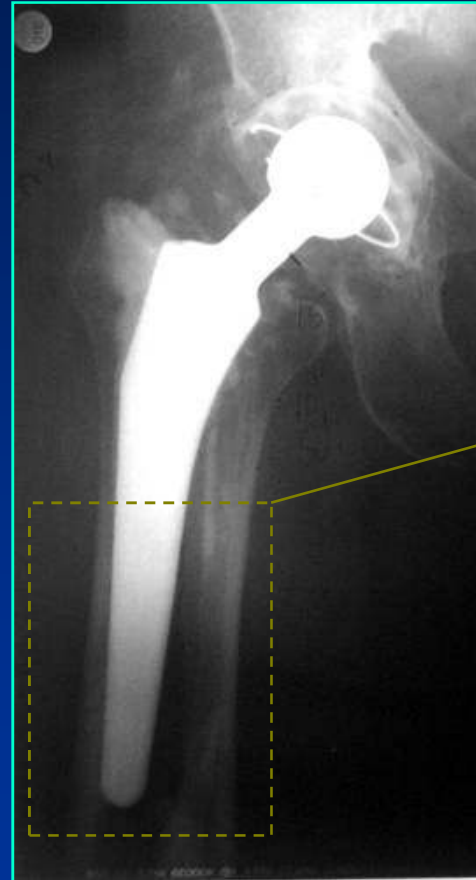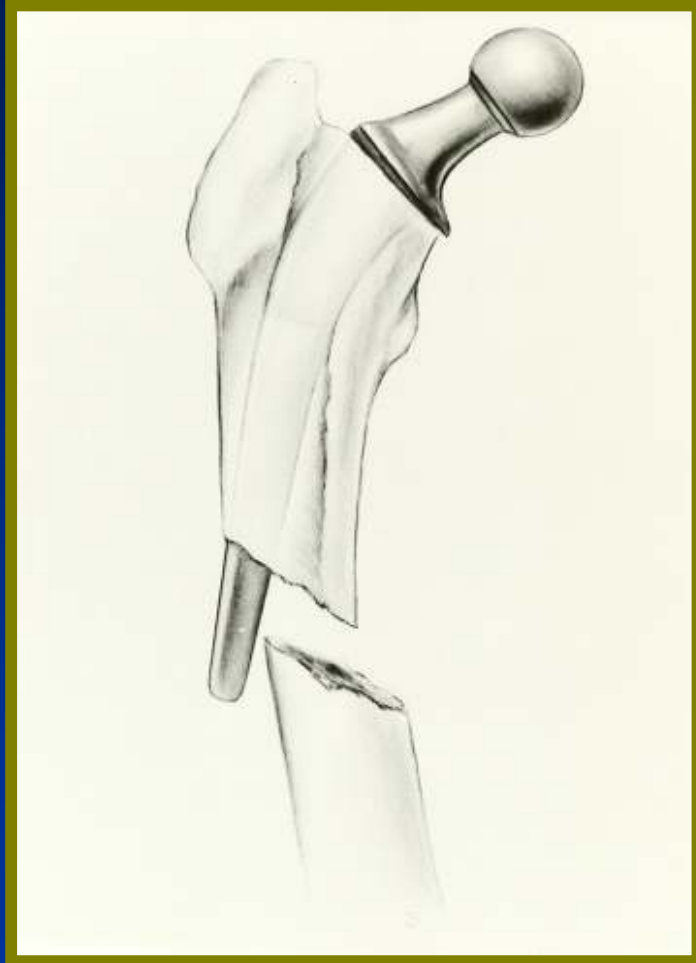# Type B



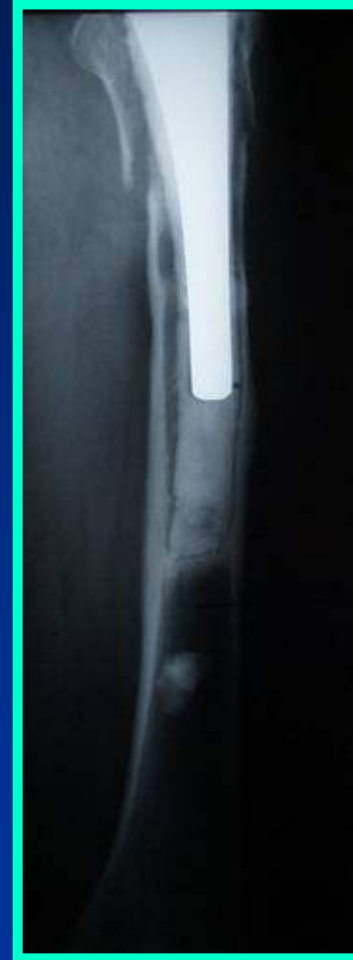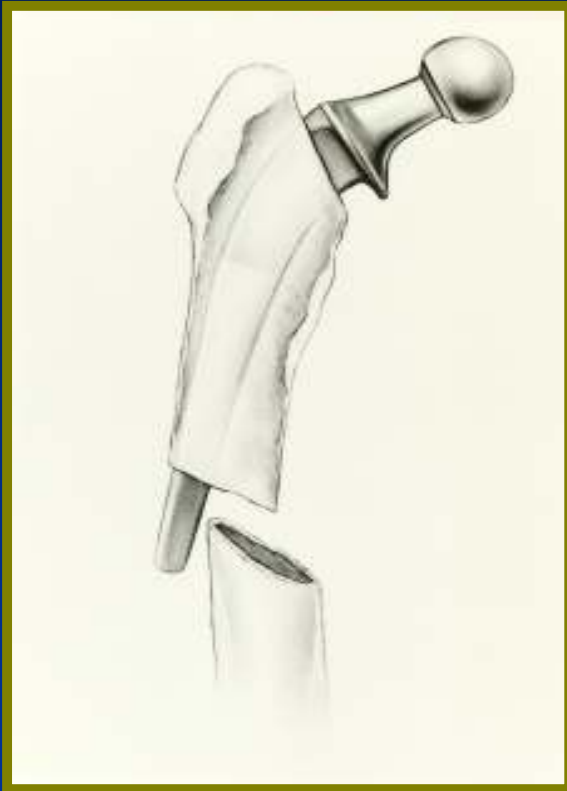B1



# B2



B3



# Reliability of Vancouver Classification

- Review of 58 cases
- Intraobserver reliability 0.84 kappa
- Interobserver reliability
  - Types A/B/C 0.93 (excellent agreement)
  - Types B1/B2/B3 0.64 (substantial agreement)

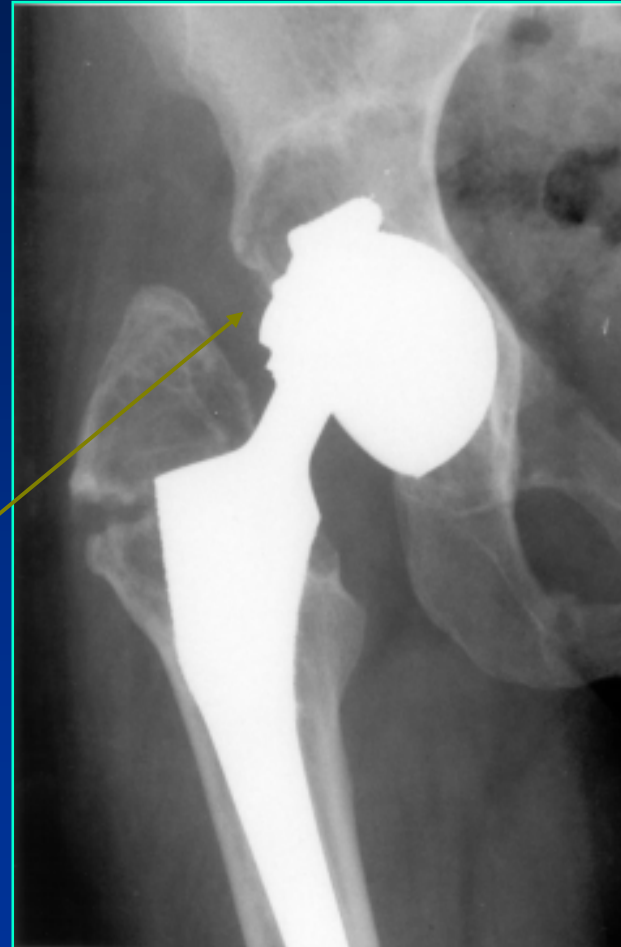
# Pitfalls

- Doesn't differentiate between spiral B1 fractures around implant (low bending moment) and transverse/oblique fractures at tip of implant (high bending moment)
- Type B1 and C fractures can essentially be treated by the same method ie Fixation
- B2 and B3 Fractures treated by Revision

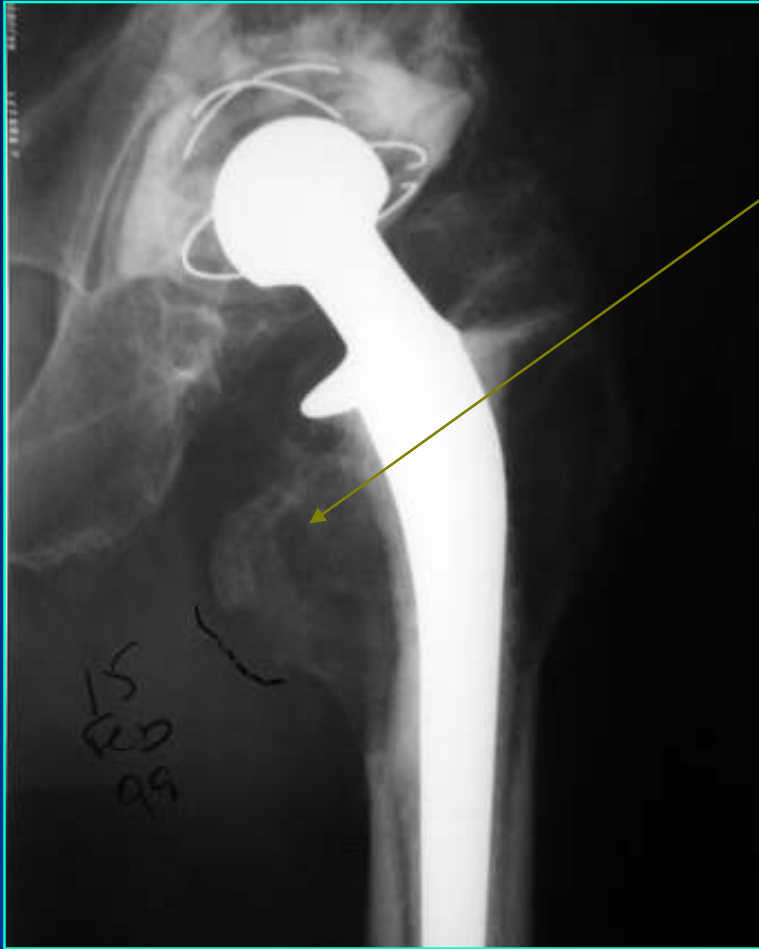
# Treatment Options

## – Type A<sub>G</sub>

- Often a silent manifestation of a worse problem
- Can often Rx symptomatically if traumatic
- Watch for migration
- Address the cause if osteolysis
- Fix if displaced >1cm



# Type A<sub>L</sub>



- Often related to osteolysis
- Treat Symptomatically if stem is stable
- Revise if stem is unstable
- Diaphyseal fixation if diaphysis is intact

# Type B1

- Treatment Goals
- Conservative?
  - If undisplaced and patient can be NWB
  - BUT, fractures usually unstable
  - Significant morbidity with bedrest, traction etc
- Is it infected?
  - Markers
  - Consider Aspiration

# Type B1

## Operative Management

- General Medical Status
- Will Stem and cement obstruct screws ?
- What is the personality of the fracture ?
  - Long spiral
  - Short oblique/transverse
  - Location
    - Proximal
    - At tip

# B1 - Options

- Retain Implant and Fix

- Revise ??

# Retain and Fix

- Aims
  - Achieve and maintain good reduction
  - Ensure Implant stability
  - Promote Healing
  - Allow earliest Mobilisation

# Retain and Fix

- Options
  - ~~Cables/Wires~~
    - Not by themselves
  - Cable plates+/-Strut Grafts
    - Dall Myles
    - Cable Ready etc
  - DCP type plates
  - Locked Plates
  - MIPO

# Cable Plates

- Open approach
  - Direct reduction
  - Combination of screws and cables
    - Improves torsional rigidity over cables alone
    - Cables supplement unicortical screws proximally
    - Now have plates where cables lock to plate



# Results

- Most papers small case series
  - 7 B1 fractures
    - 2 non unions
    - 2 in unacceptable varus
  - Initial varus implant = poor outcome
- 16 patients majority with B1 fractures
- 43% failure rate when used as sole fixation
- 10% failure rate combined with strut graft

(Tadross, Nanu, Checketts et al. J Arthroplasty 2000)

(Tsiridis, Haddad et al. Injury 2003)



Most Authors advocate augmenting with at least one strut graft

# DCP

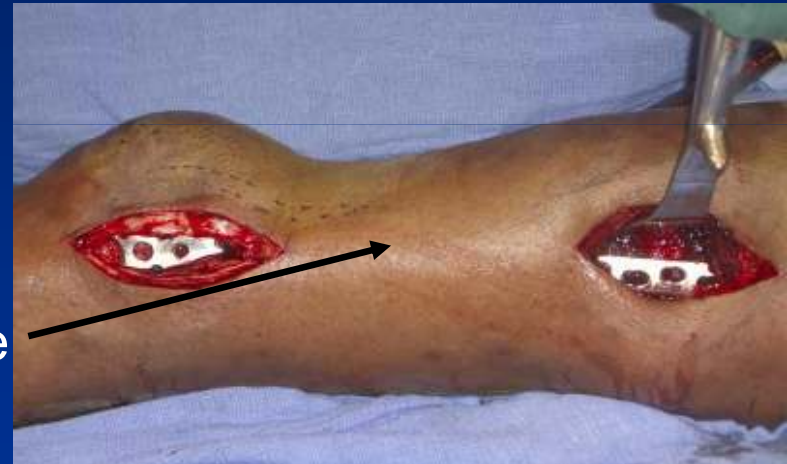- Open
  - Union rates of 90% in some series (combined with autograft or strut allograft)

Serocki et al J. Arthroplasty 1992

Tsiridis et al Acta Orthop 2005

- Minimally Invasive
  - Demanding
  - Preservation of soft tissue bridge critical
  - 100% union in one series
  - No autograft/allograft

Ricci et al . JBJS Am 2005



# Locking Plates

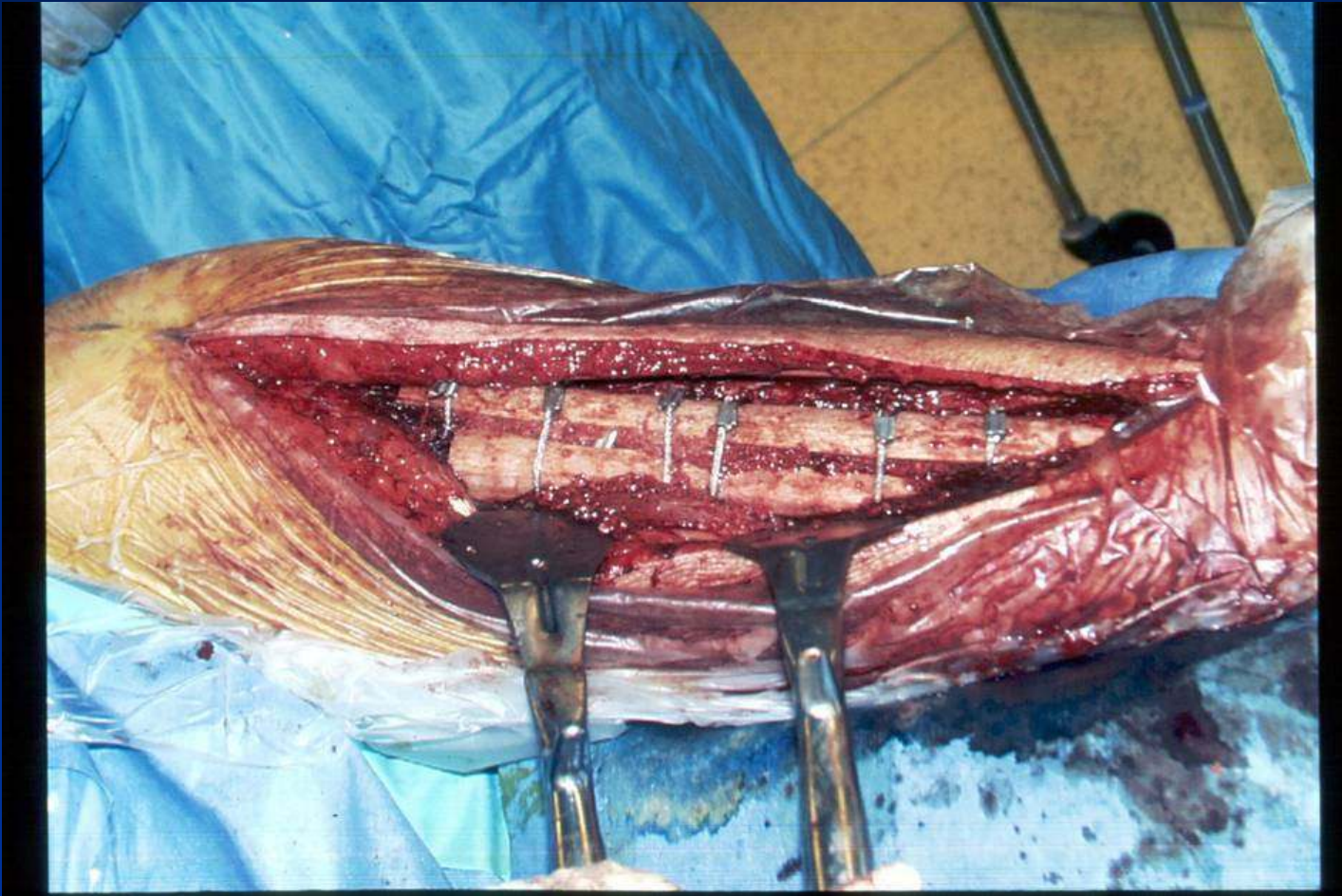
- Allow combination of unicortical and bicortical fix
  - Increases options for proximal fixation
- Respecting the biology is key
- Probably need augmenting if performed open
- Some Poor Results –  
Buttaro et al JBJS 2007



14 B1 fractures  
Ave f/u 20 months  
3 failed with plate fracture  
3 failed with plate pull-out

# Other options - Fixation

- Strut grafts only
  - Biologic
  - Difficult to contour
  - Difficult to obtain

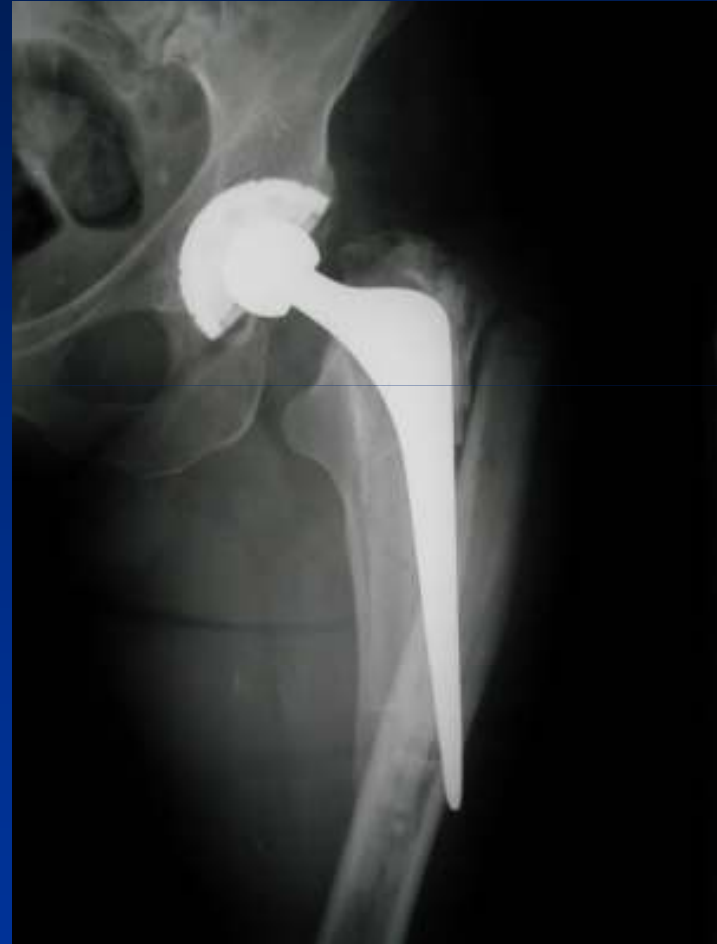

# B2 and B3 Fractures

- Loose Implant (B2) +/- Inadequate Bone Stock (B3)
  - mandates revision
  - +/- restoration of bone stock

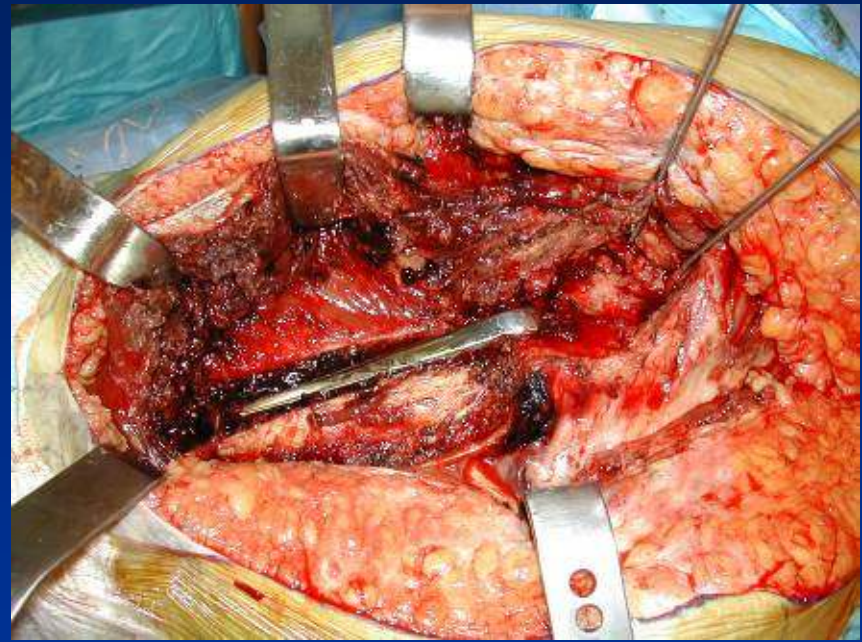
# B2

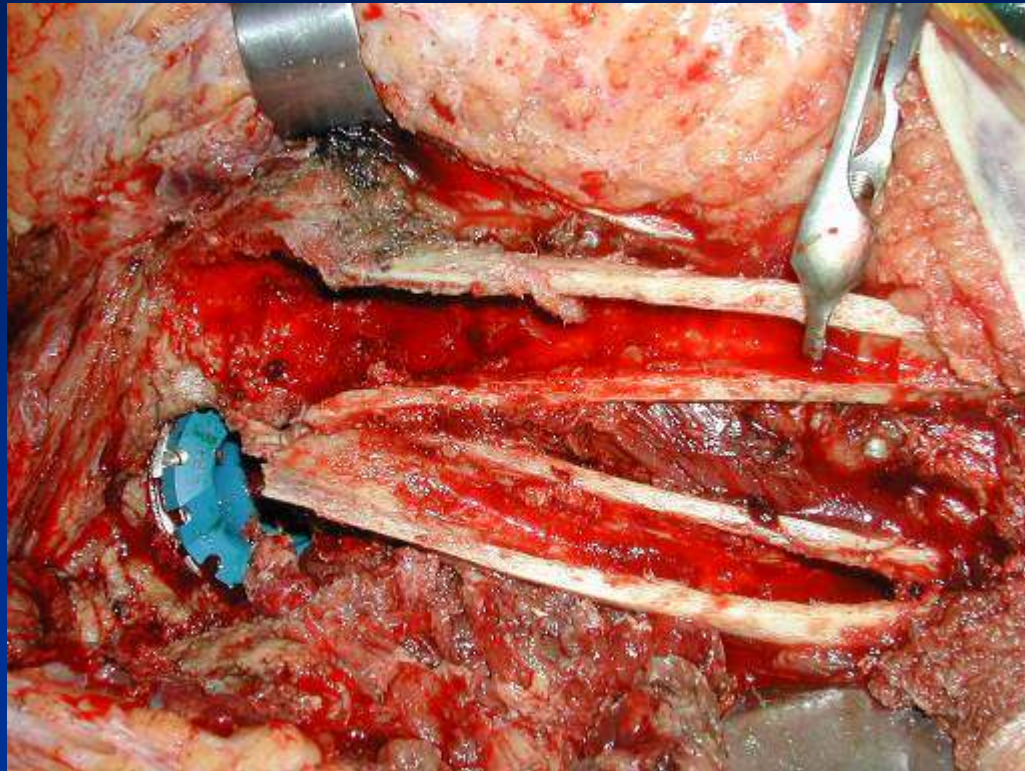
- Is it infected?
- What is the co morbidity?
- Can the patient non weight bear?
- Is there an isthmus to support my implant?
- What's the socket like?
- Have I got all the kit I might need?



# Technique

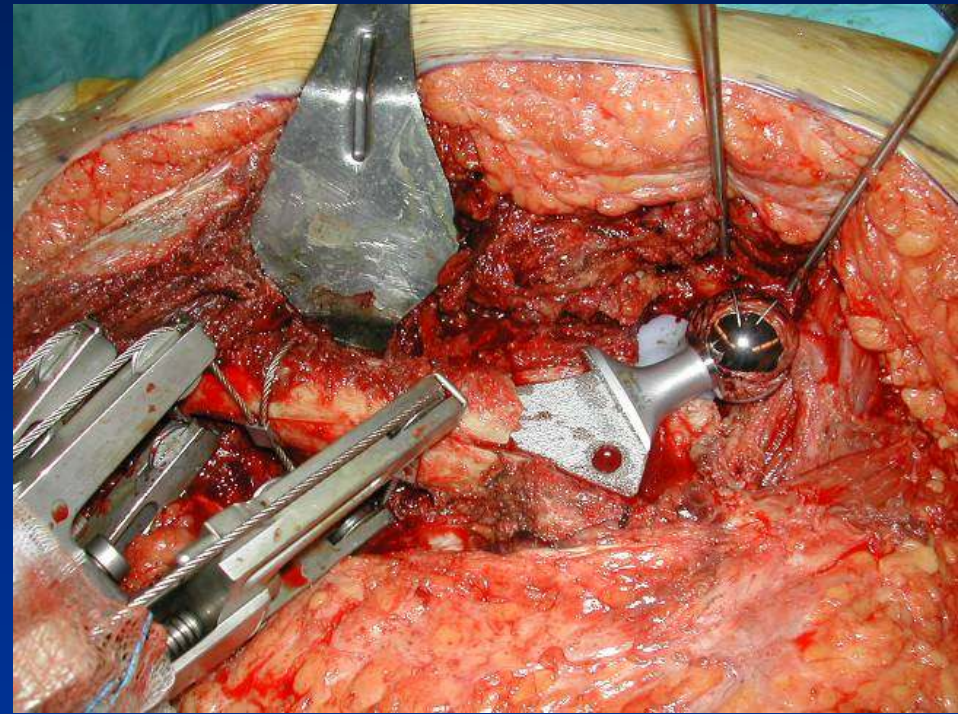
- Posterolateral Approach to Hip
  - Expose implant via fracture site
  - Hip dislocated and Implant extracted
  - Expose acetabulum and confirm initial plan, revise if necessary
  - Distal cement accessed via fracture

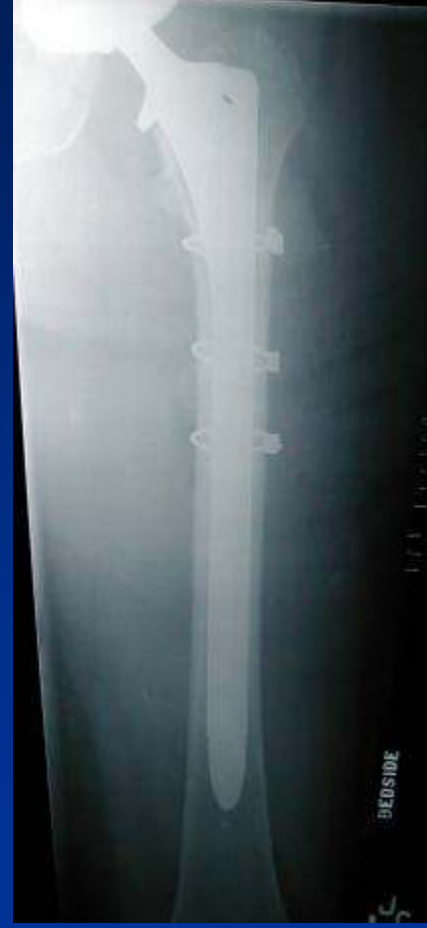
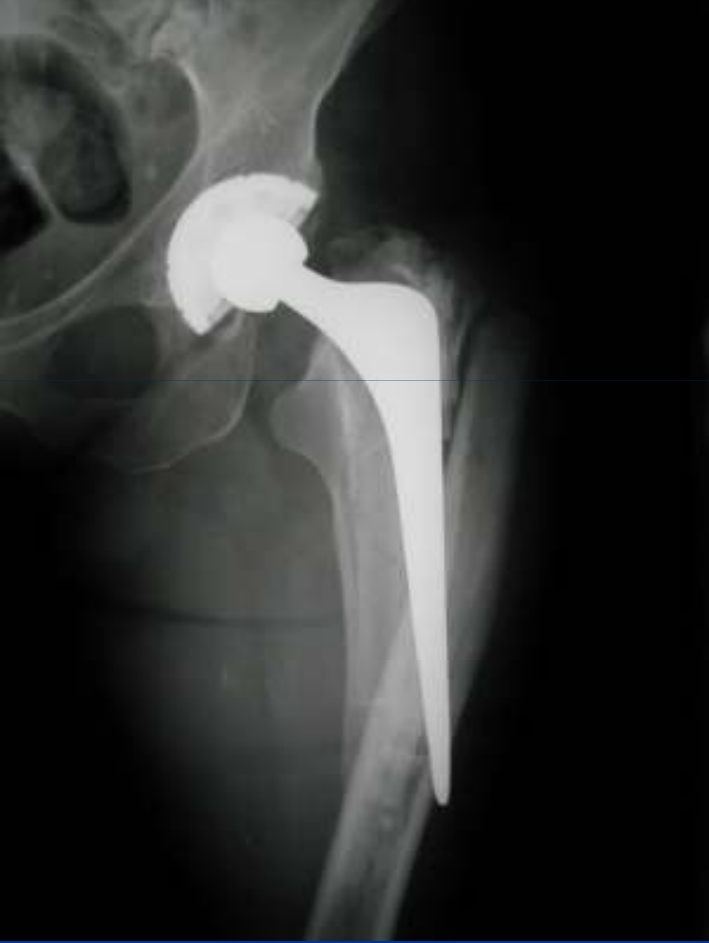


# Prosthesis Implantation

- Confirm pre op plan
- Trial Implant to assess leg length and stability
- Insert definitive Implant (prophylactic cerclage)
- Cable Proximal Femur around Prosthesis
- Augment as necessary





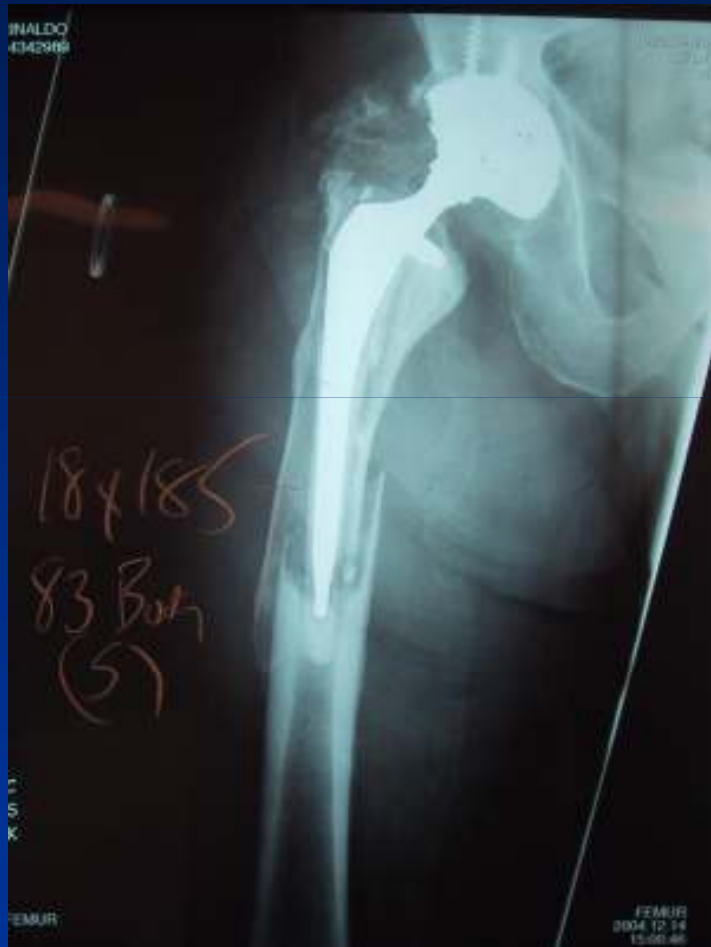# Pitfalls

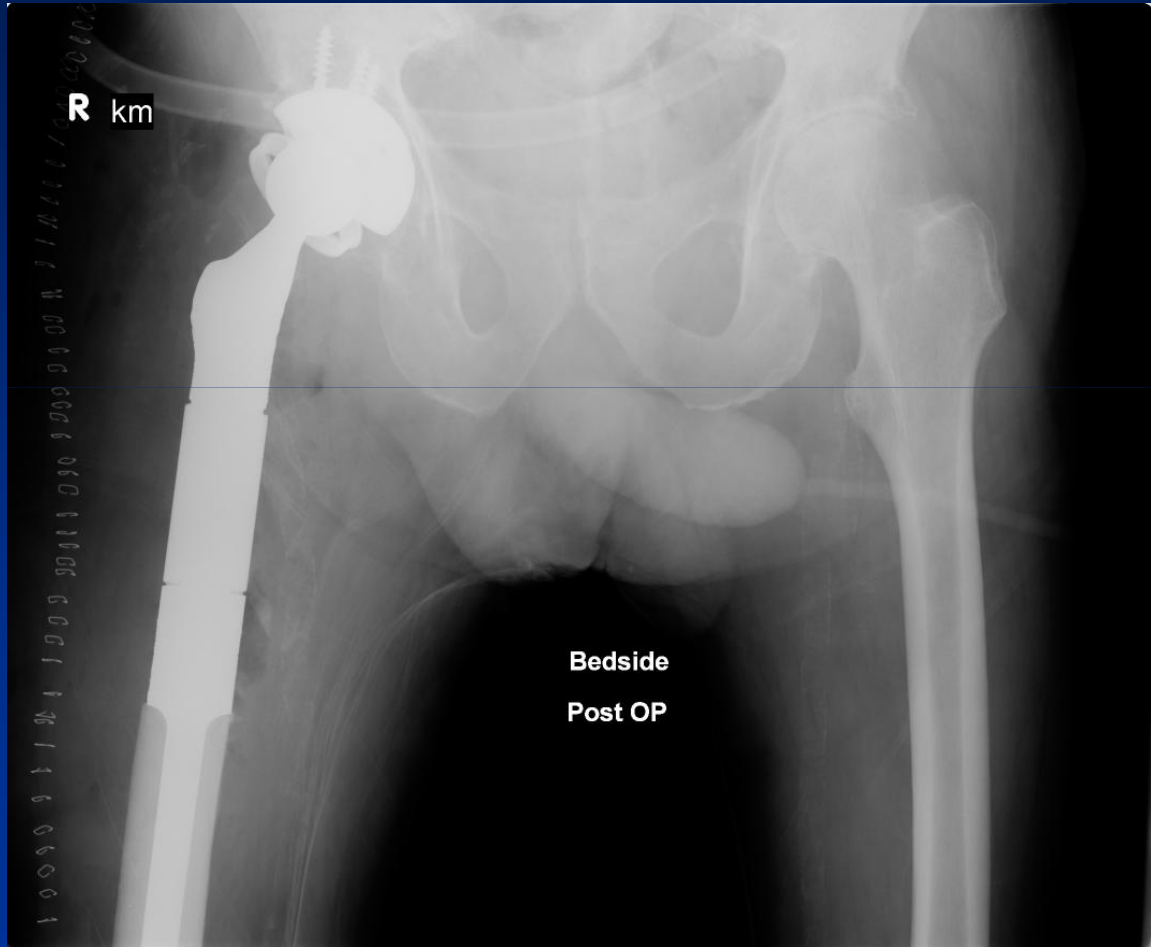
- Insufficient Kit “worst case scenario”
- Propagating Fracture
- Infection

Think about intra op radiographs

# B3 Fractures

- All the above applies BUT
- Inadequate bone stock
  - May be able to bypass if isthmus sufficient or can use distal locking stem
  - Still need to try and reconstitute proximal bone stock
    - Struts
    - Impaction graft
- If unable to restore bone
  - Allograft/Prosthesis Composite
  - Tumour Type Prosthesis

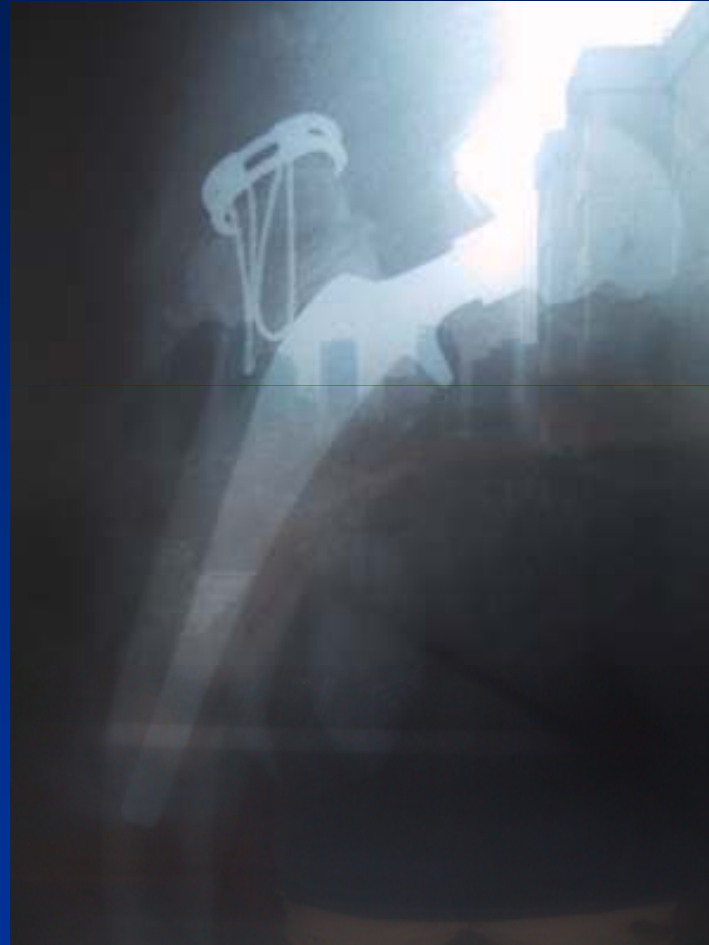

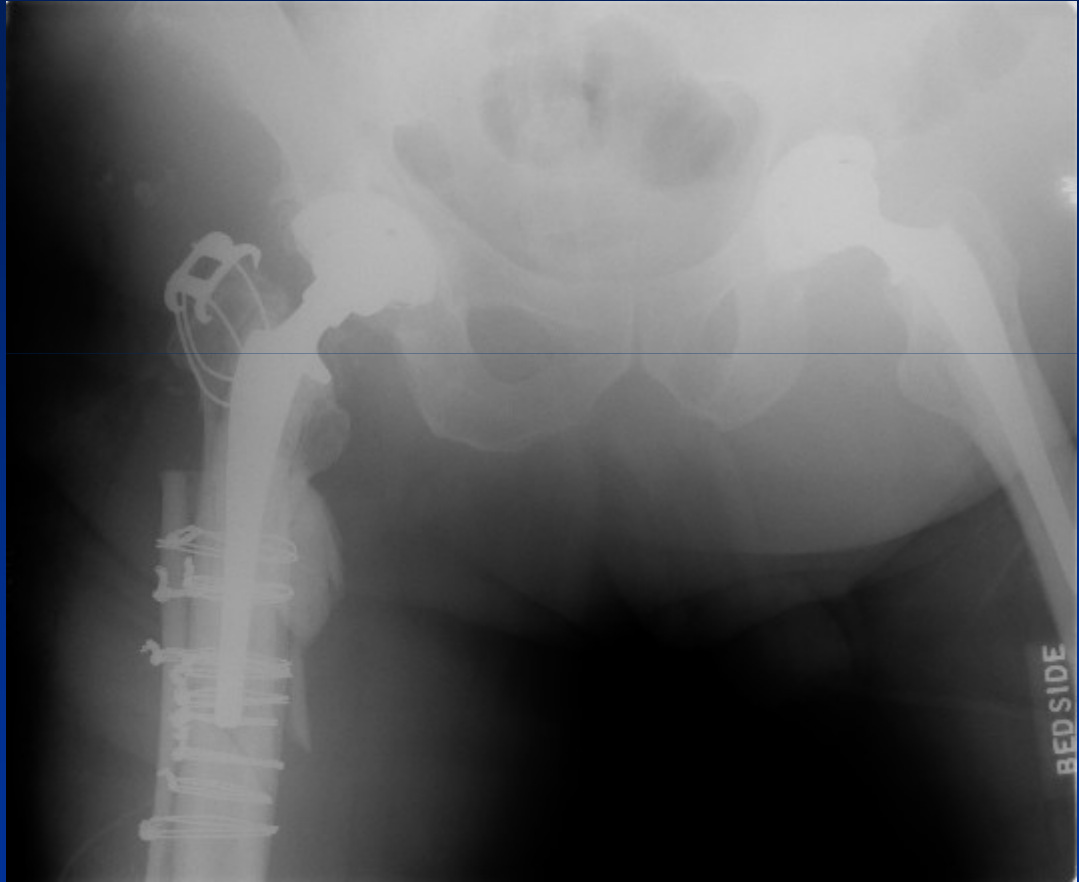


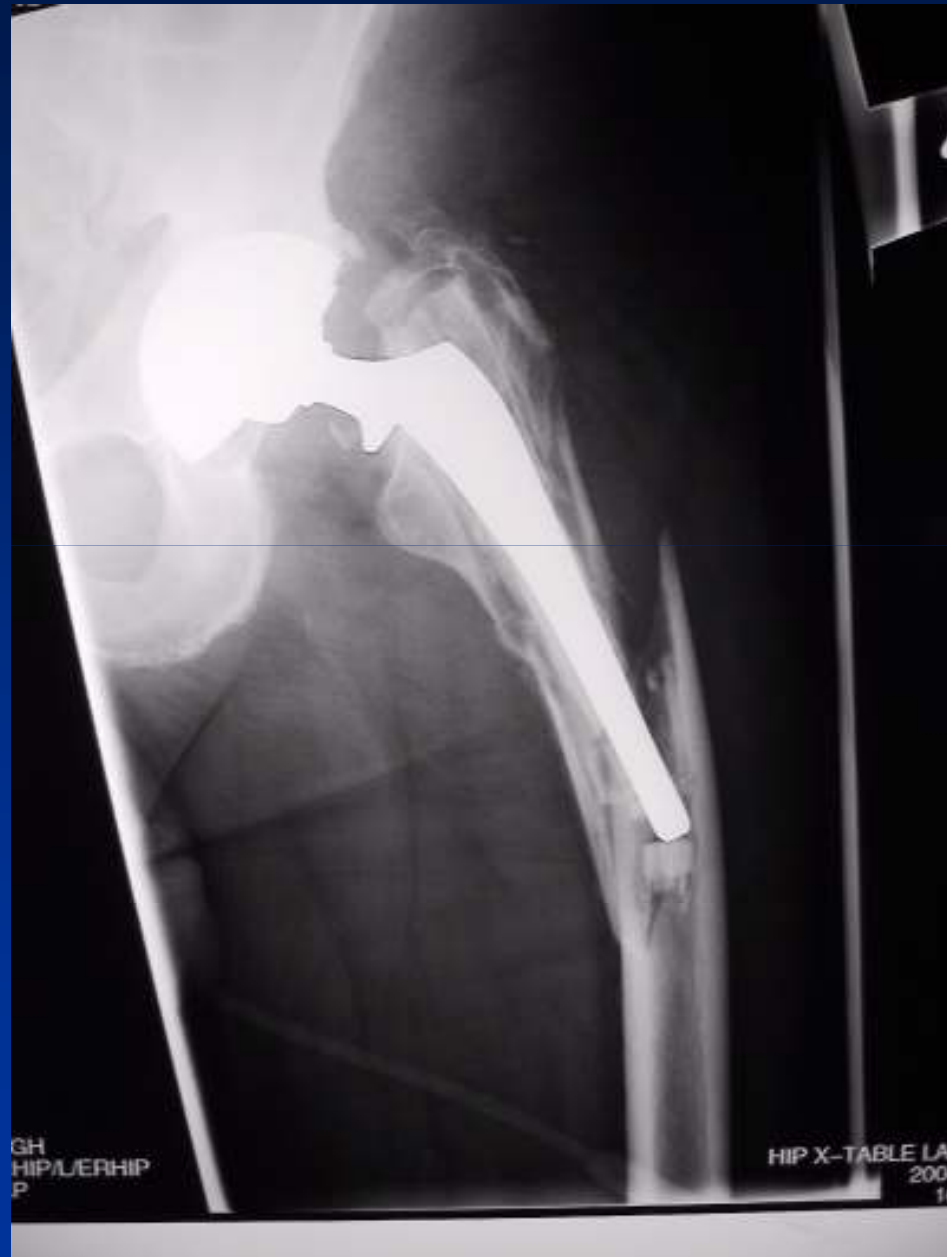# Type C

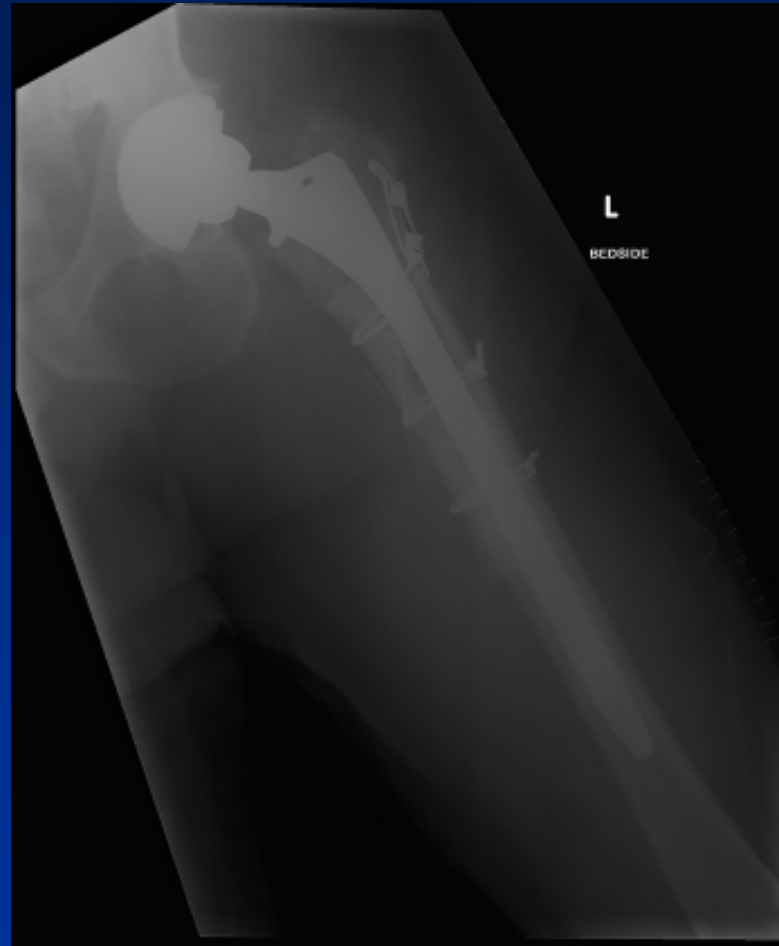- Generally fixed internally
- Same Modalities as B1
- Plate etc should overlap implant tip by 5cm
- Consider augmenting with strut graft
- Retrograde Nails
  - Need to bypass fracture by 2 cortical diameters
  - Stress riser between tip of nail and implant

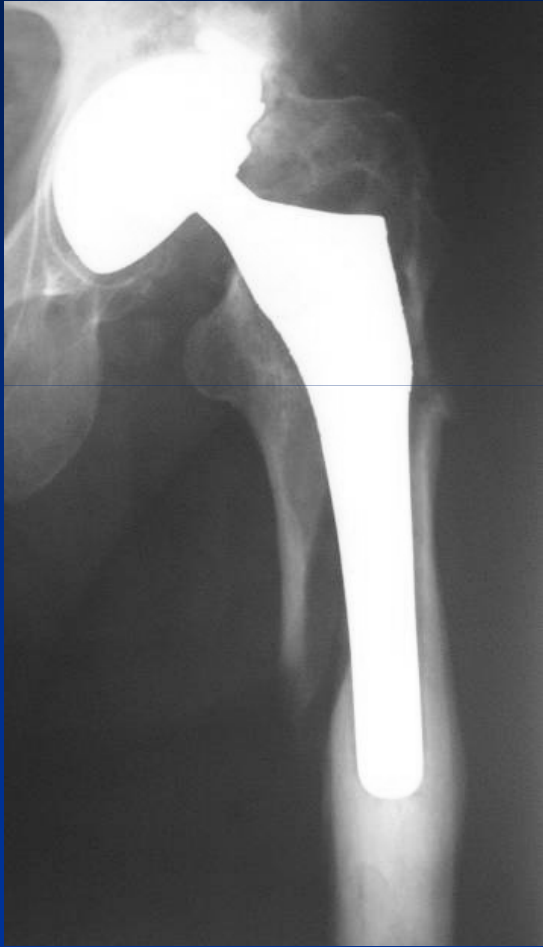A few cases.....

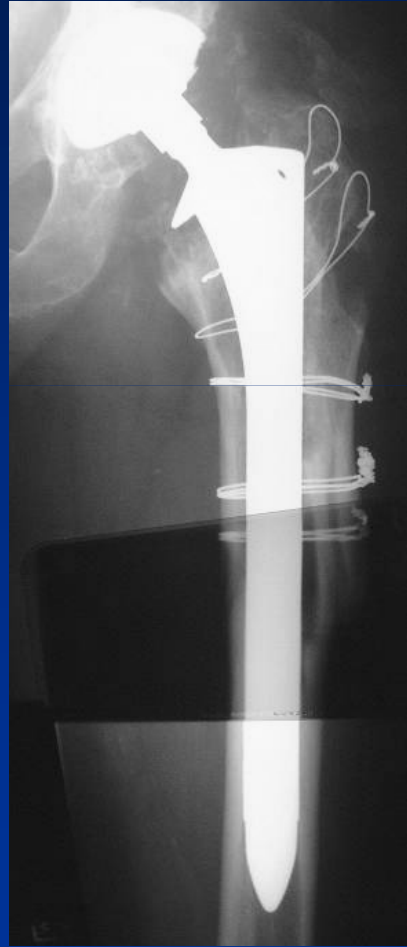


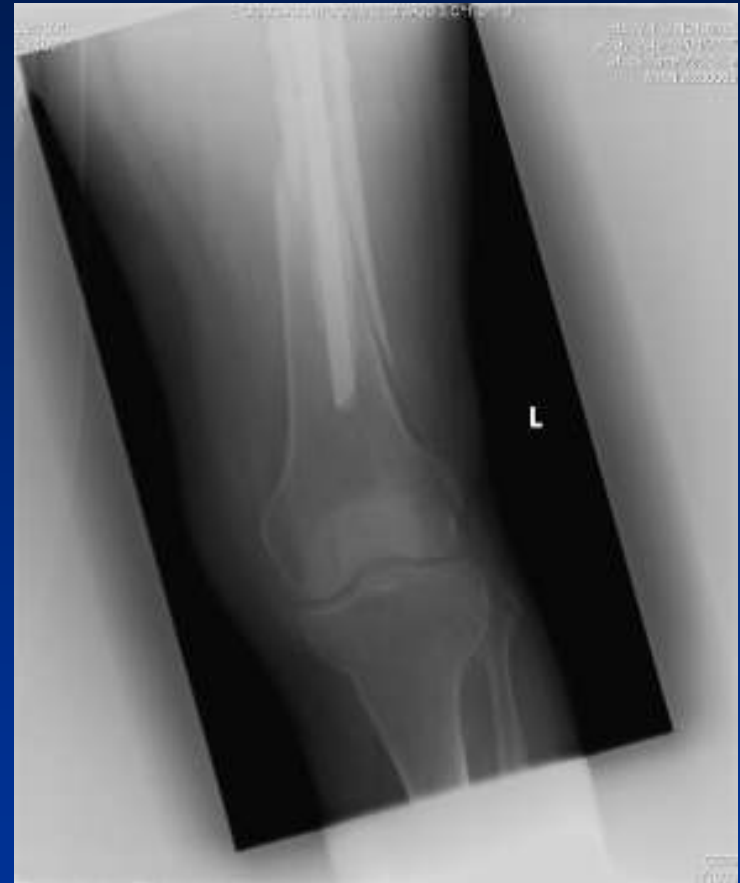
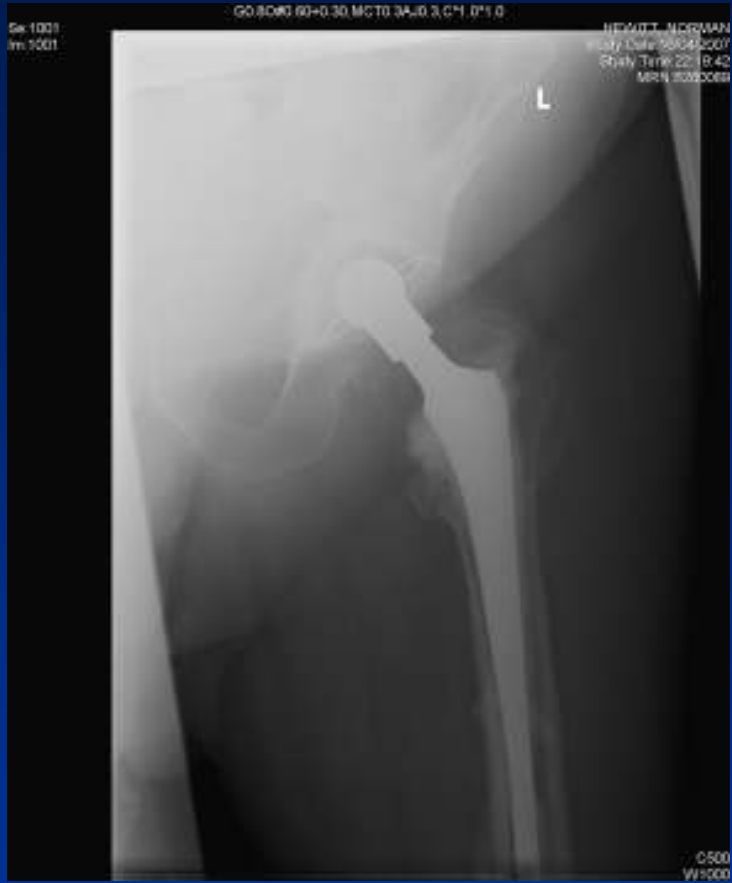








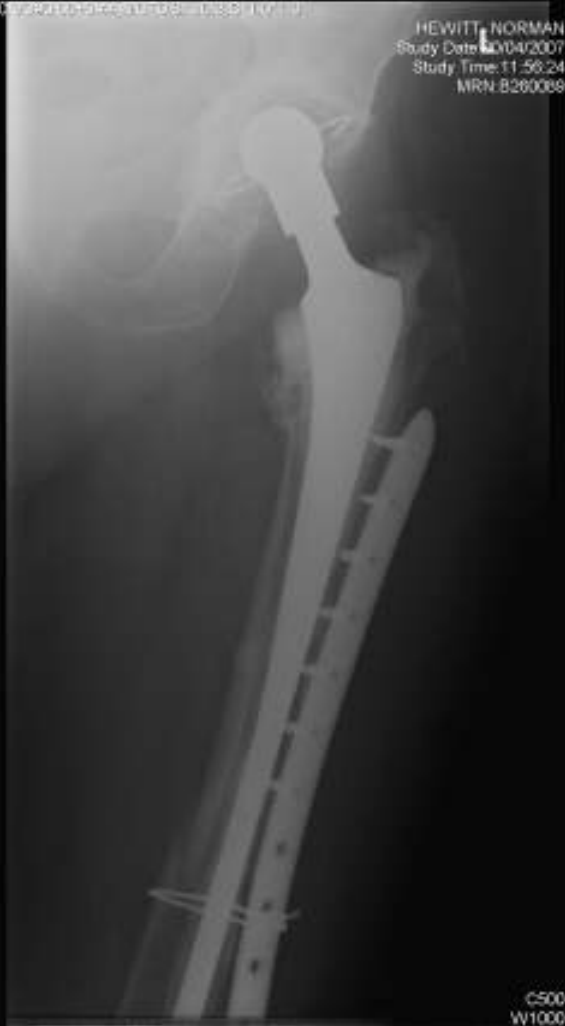
Se:1001  
Im:1001

GO:8040:040538MC103A:03:CHI:WT:J

HEWITT, NORMAN  
Study Date: 2004/2007  
Study Time: 11:56:24  
MRN: B260069

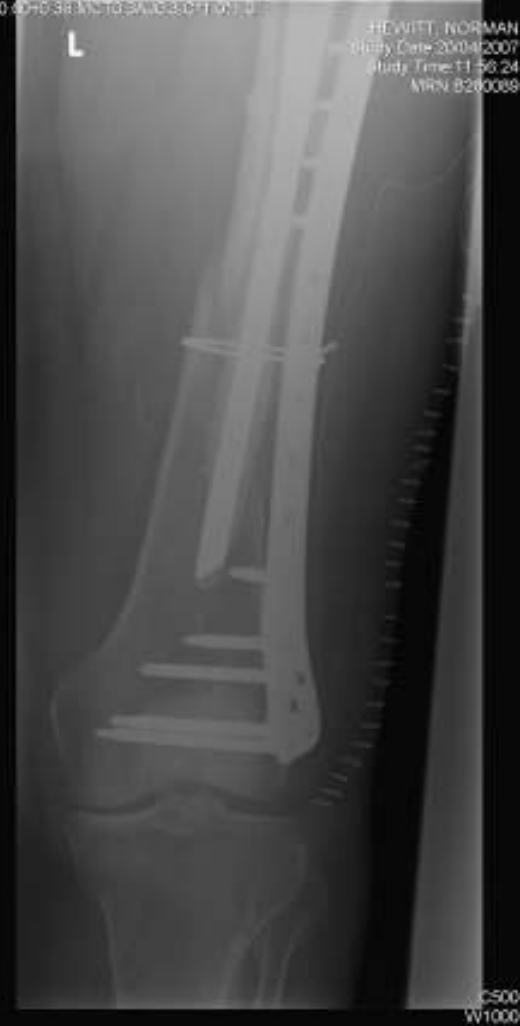

C500  
W1000

Se:1002  
Im:1002

GO:8040:040538MC103A:03:CHI:WT:J

HEWITT, NORMAN  
Study Date: 2004/2007  
Study Time: 11:56:24  
MRN: B260069



C500  
W1000

# Summary

- Don't underestimate your opponent
  - Treatment depends on
    - Fixation
    - Bone stock
    - Location
  - Exclude Infection
  - Have all the kit you need
- Good Luck



Thanks