



Deformities of the Legs: Who Cares?

Antoine de Gheldere, MD

Consultant in Children's Orthopaedics and Trauma

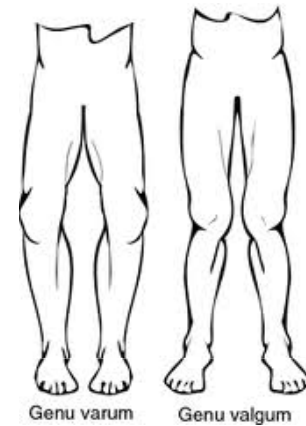
GNCH – Royal Victoria Infirmary
Newcastle upon Tyne, UK

Paediatric Orthopaedics Teaching, 16th April 2012

Types of Deformities

- Angular Deformities

- Genu Varum
- Genu Valgum
- Bowing of Tibia



- Torsional Deformities

- Femoral torsion
- Tibial torsion

Most of the time...

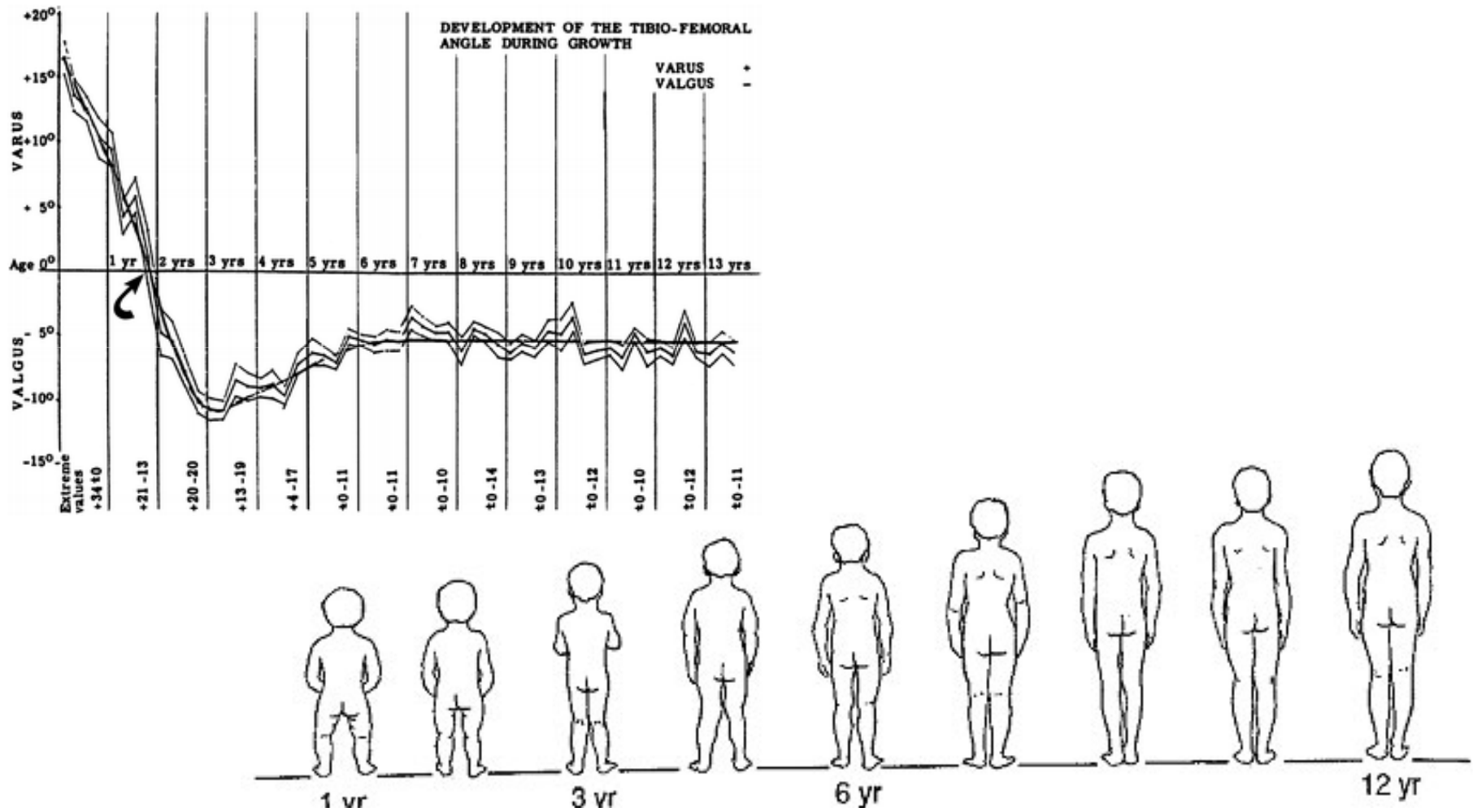
“... children seeing by orthopaedic surgeon for angular deformities of the legs are within normal limits”

What are the “Normal Limits”

Normal physiologic progression:

- Birth: maximum genu varum
- 18 months: legs straight
- 4 years: maximum genu valgum
- Maturity: straight or slight valgus

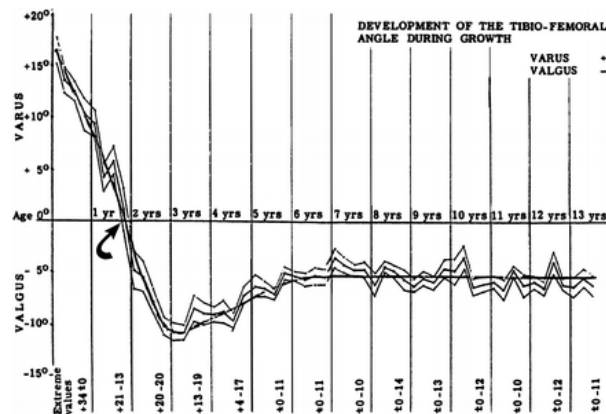
What are the “Normal Limits”



Heath & Staheli. JPO, 1993

Remember...

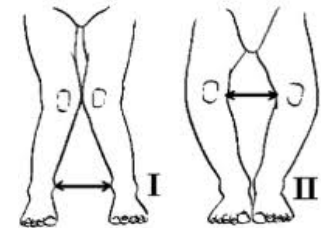
- Between 2 and 11 years, Moderate genu valgum is normal:
 - intermalleolar distance up to 8 cm
 - 12 degrees
- After 2 years genu varum is abnormal



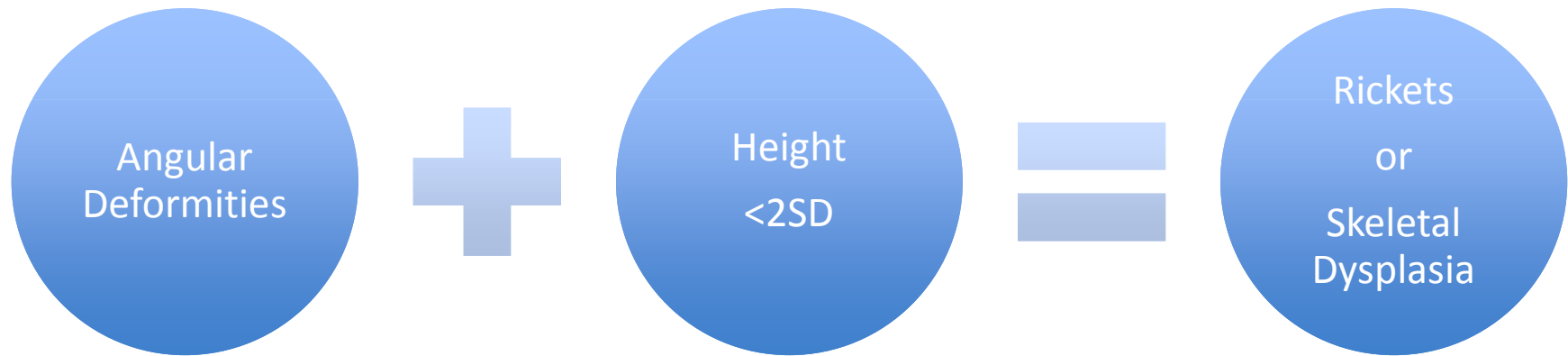Heath & Staheli. JPO, 1993

Clinical Assessment

- Difficult to be accurate!
- Standing
- Monitor the height on growth curve
- Intermalleolar distance
- Intercondylar distance
- Progression or improvement?
- Every 6 months until normal (3 months)

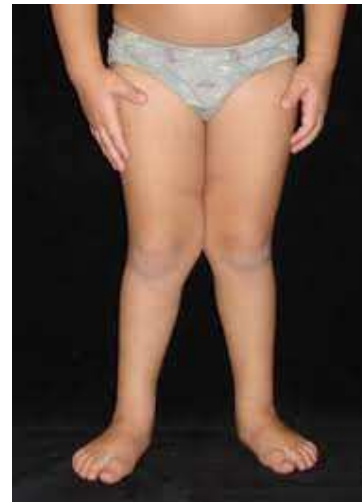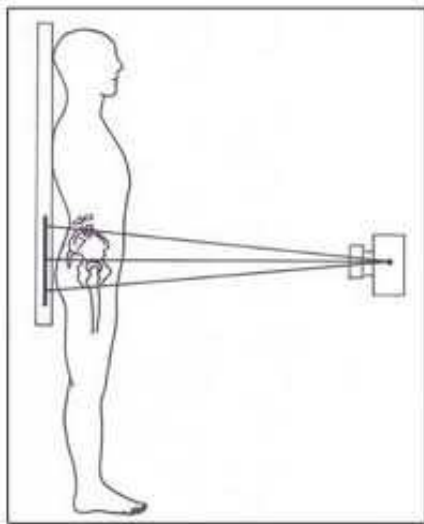


Stay out of Trouble...



X-Rays Assessment

- Standing
- Teleoroentgenogram (Long leg film)
- Knee caps (not the feet!!!) pointing forwards



GENU VARUM

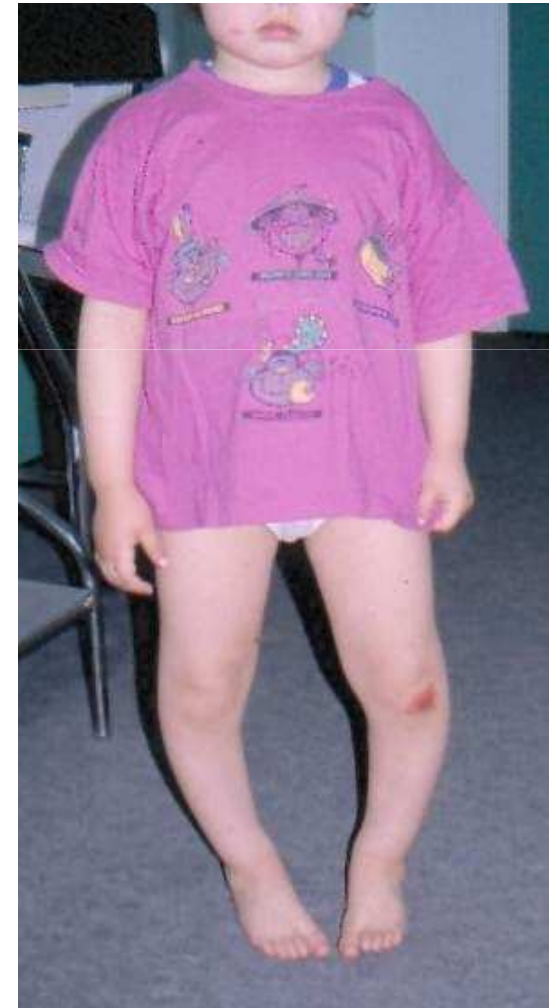or Bow Legs

Genu Varum or Bow legs

- Physiologic Genu Varum
- Apparent “Bowling”
- Blount Disease
- Rickets
- Focal injury of the growth plate
 - Trauma
 - Infection (neonatal infection, meningococemia)
- Focal fibrocartilaginous dysplasia
- ...

Suspect a Physiologic Bowing When...

- Parents report it is improving
- It's symmetrical
- Generalized bowing (femur/tibia) on X-rays



Suspect an Apparent “Bowling” When


“Bowling”

- Feet points forward
- (Patellas points laterally)

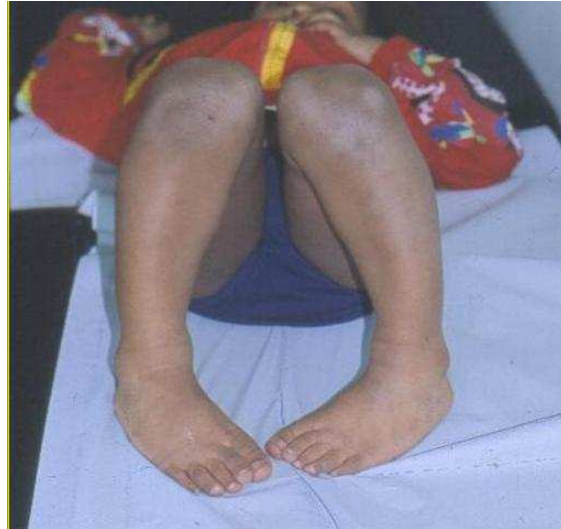Straight

- Feet points internally
- (Patellas point forward)

Apparent
Bowling



Internal
Tibial Torsion

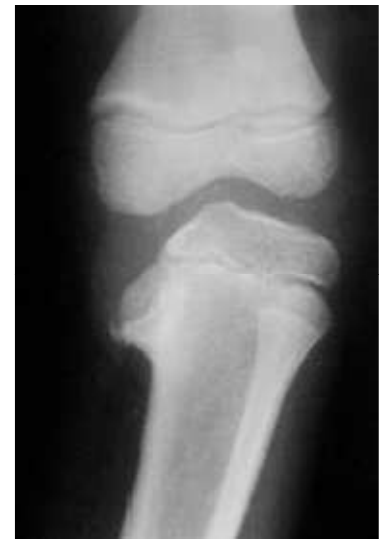

Suspect Bount Disease When...

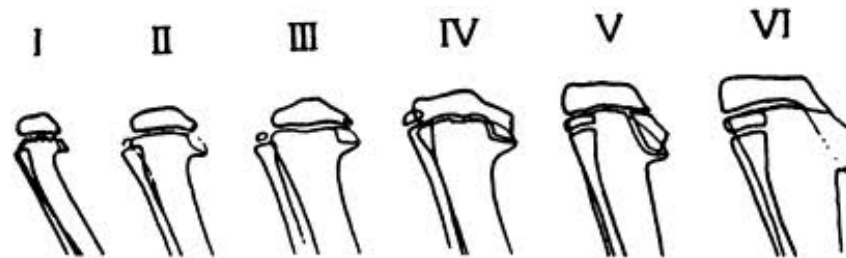
- Parents report it is not improving
- Child > 2 years
- During stance: lateral knee translation
- X-rays:
 - Focal angulation at proximal tibia
 - Medial beaking of the tibia

High Level of Suspicion if:

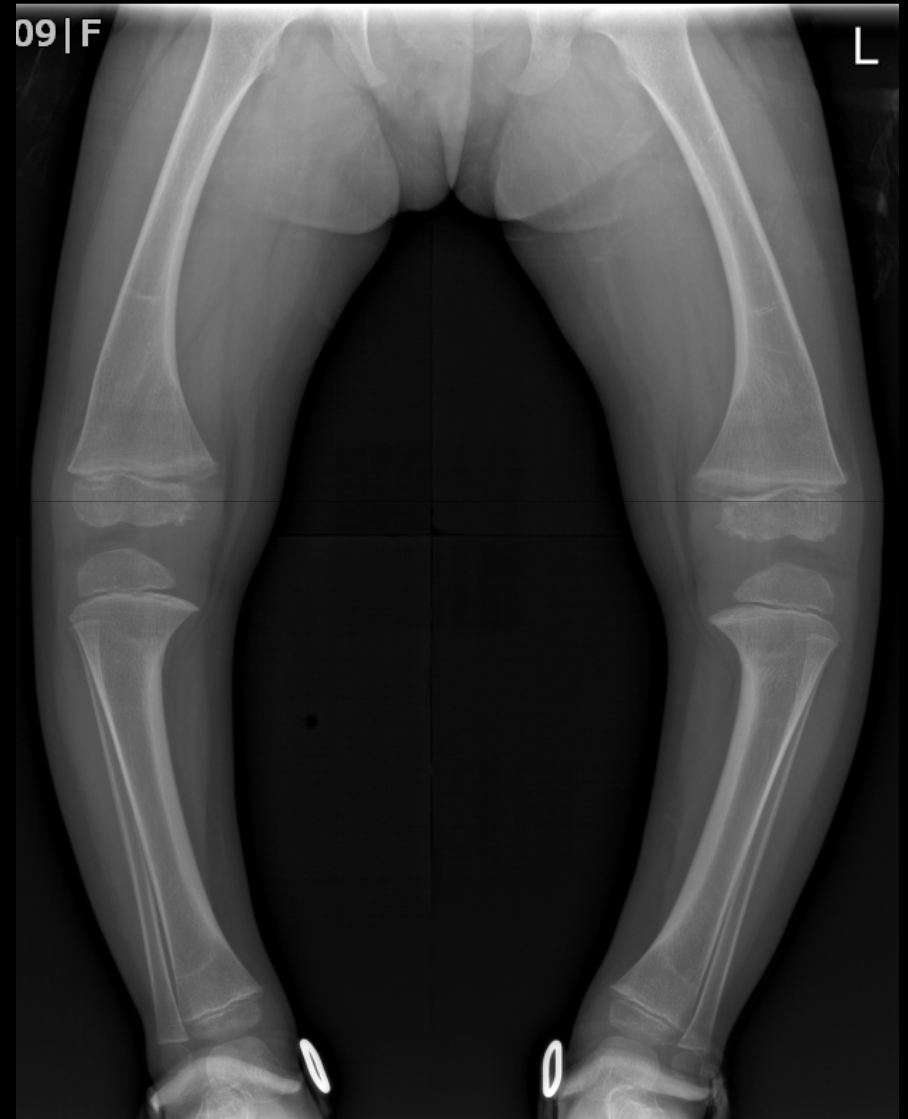
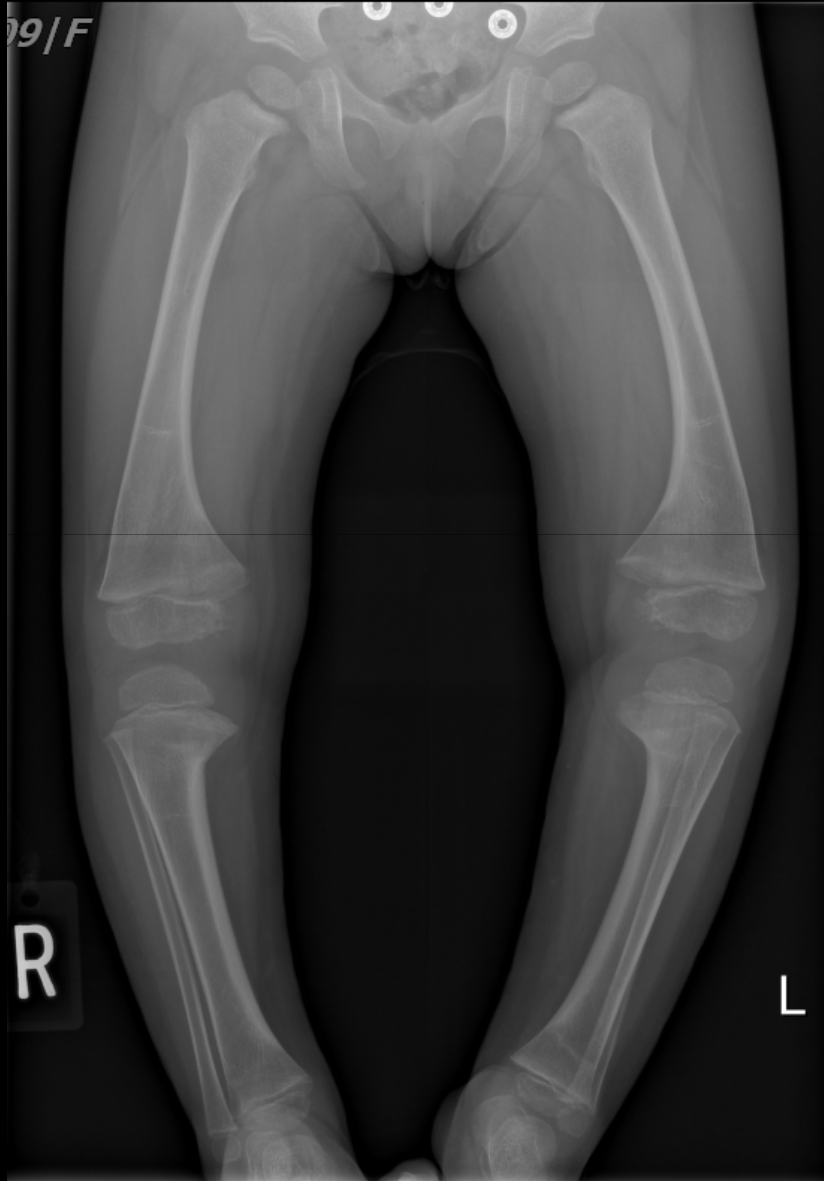
- Obesity
- African
- Early walker
- Unilateral



Treatment for Blount Disease

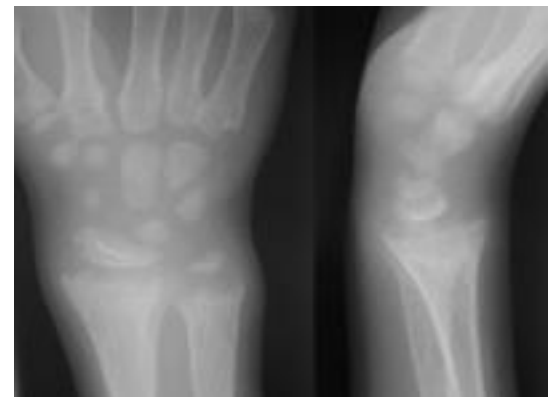
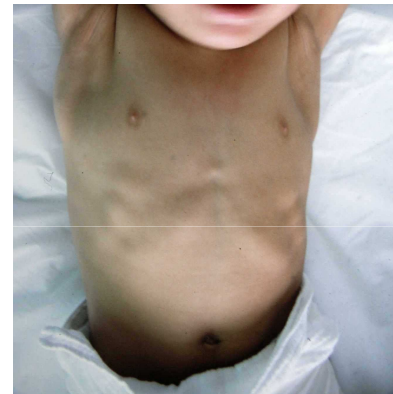


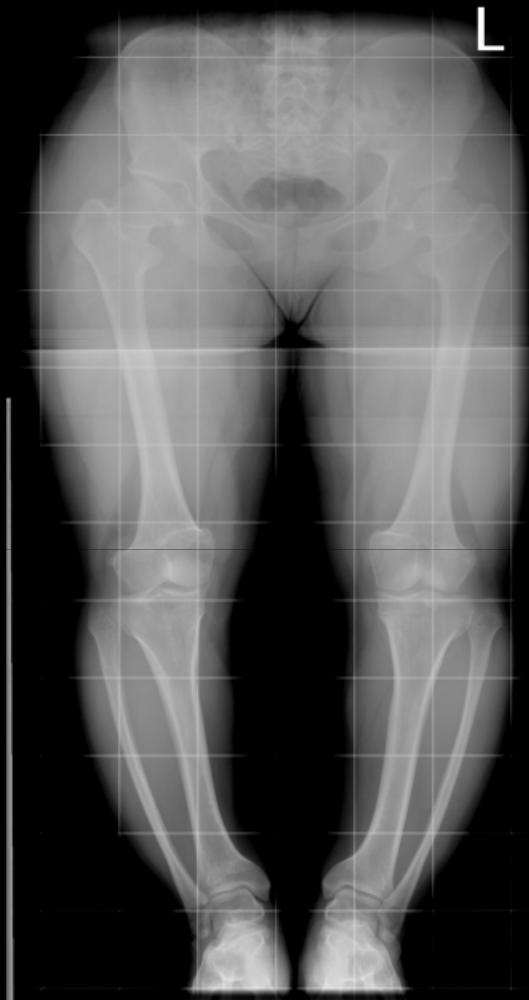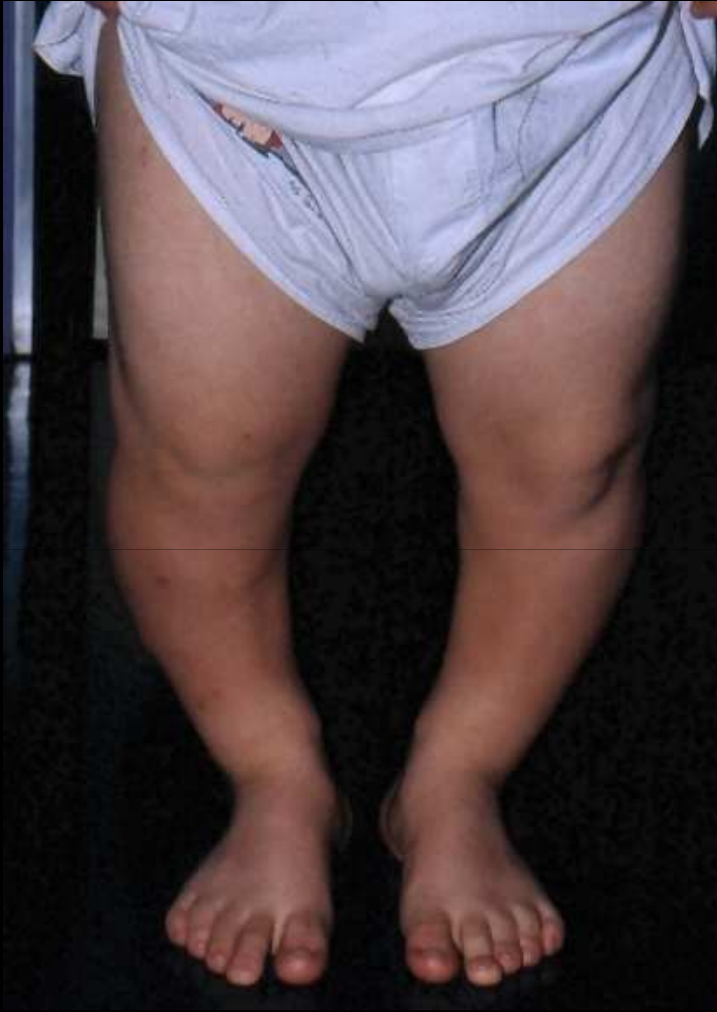- 1) Bracing (before 3 years)
- 2) Guided Growth (if no medial bone bar)
- 3) Corrective osteotomy:
 - ✓ Restore a neutral mechanical axis
 - ✓ Restore the length
 - ✓ Correction of the rotation



Rickets

- Failure of calcification of cartilage
- GP thickness
 - Knee
 - Wrist
 - Chest
- Soft bone (deformity)



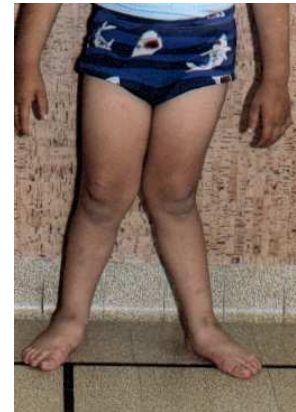

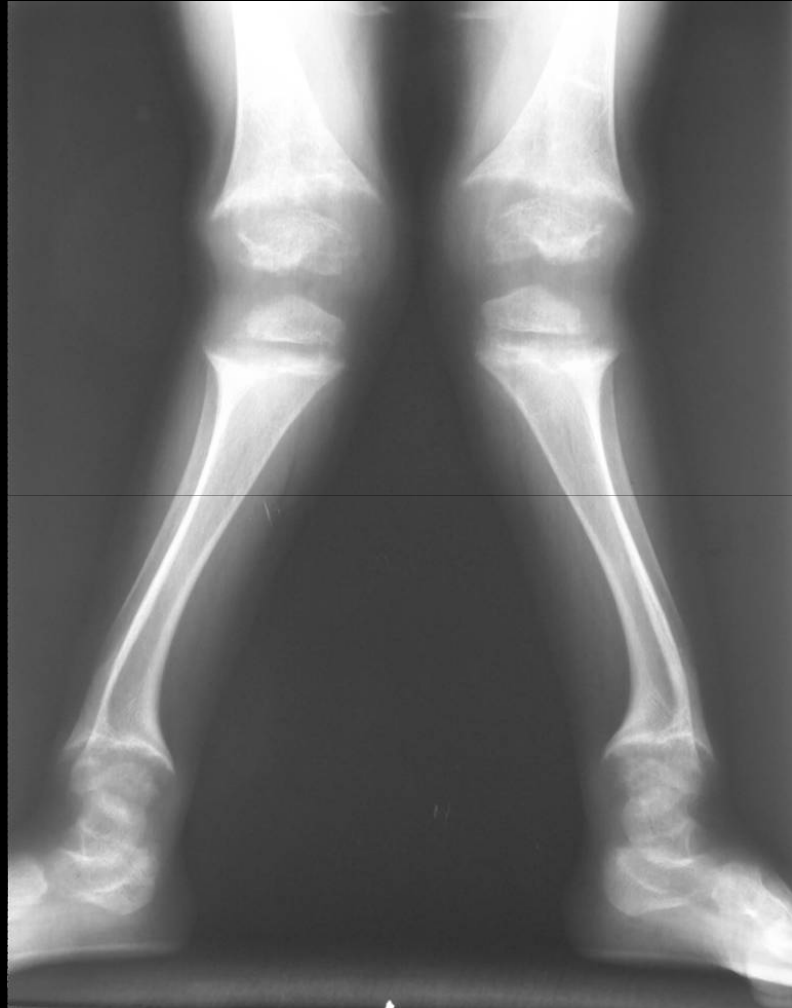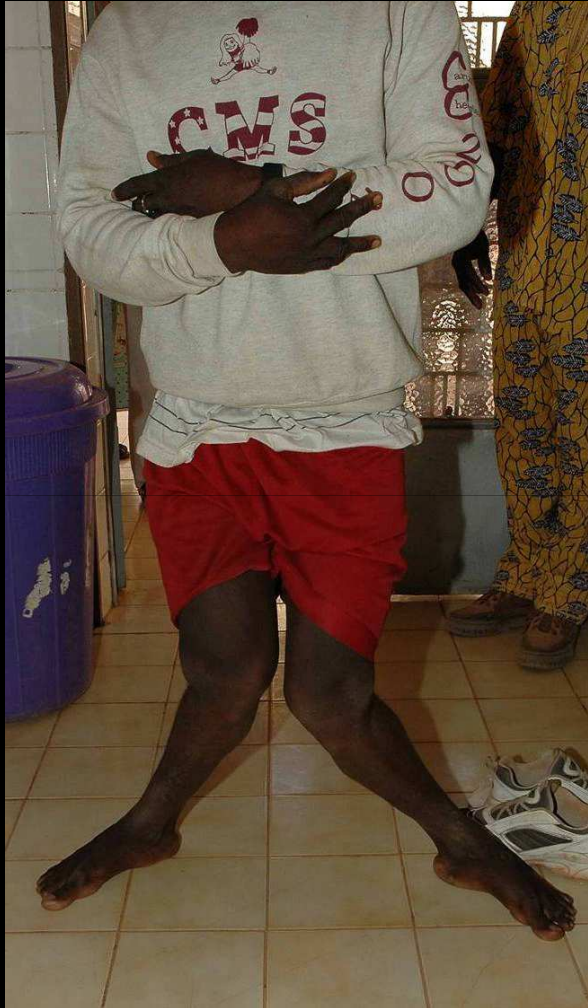Genu Valgum

or Knock Knees

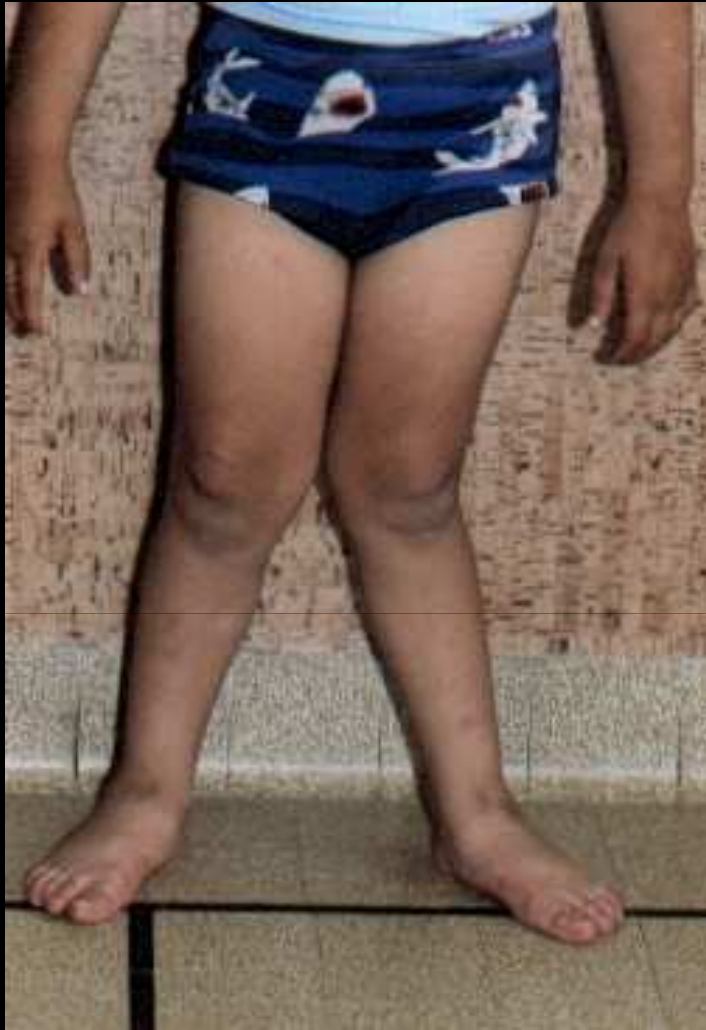Genu Valgum or Knock Knees

- Physiologic Knock Knees
- Renal osteodystrophy
- Skeletal dysplasia
- Posttraumatic (proximal tibial metaphysis Fx)
- Others:
 - Infections
 - Tumors
- ...

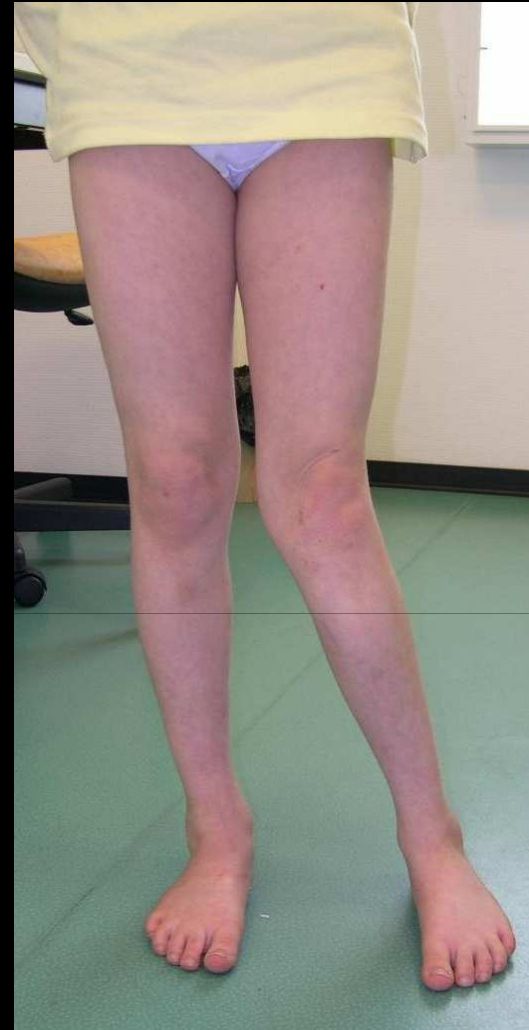



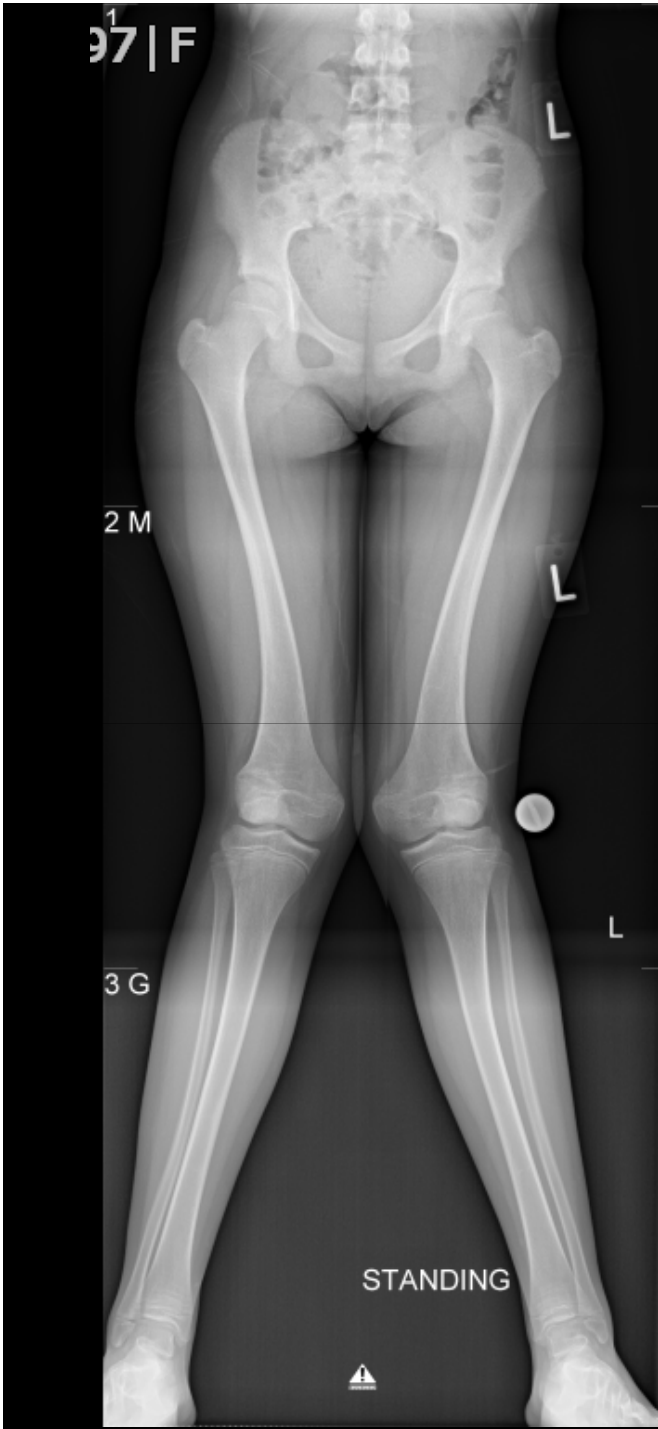
Rickets



Physiologic Genu Valgum



Unilateral Genu Valgum
(benign tumor)




Rickets

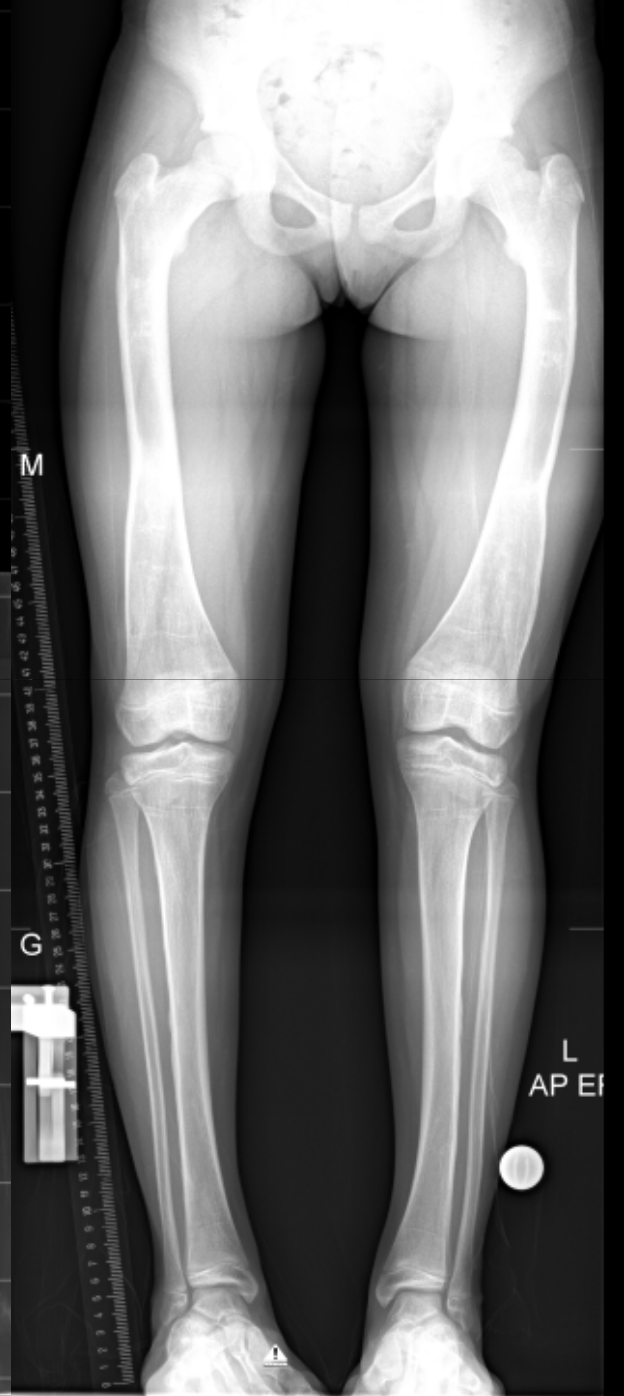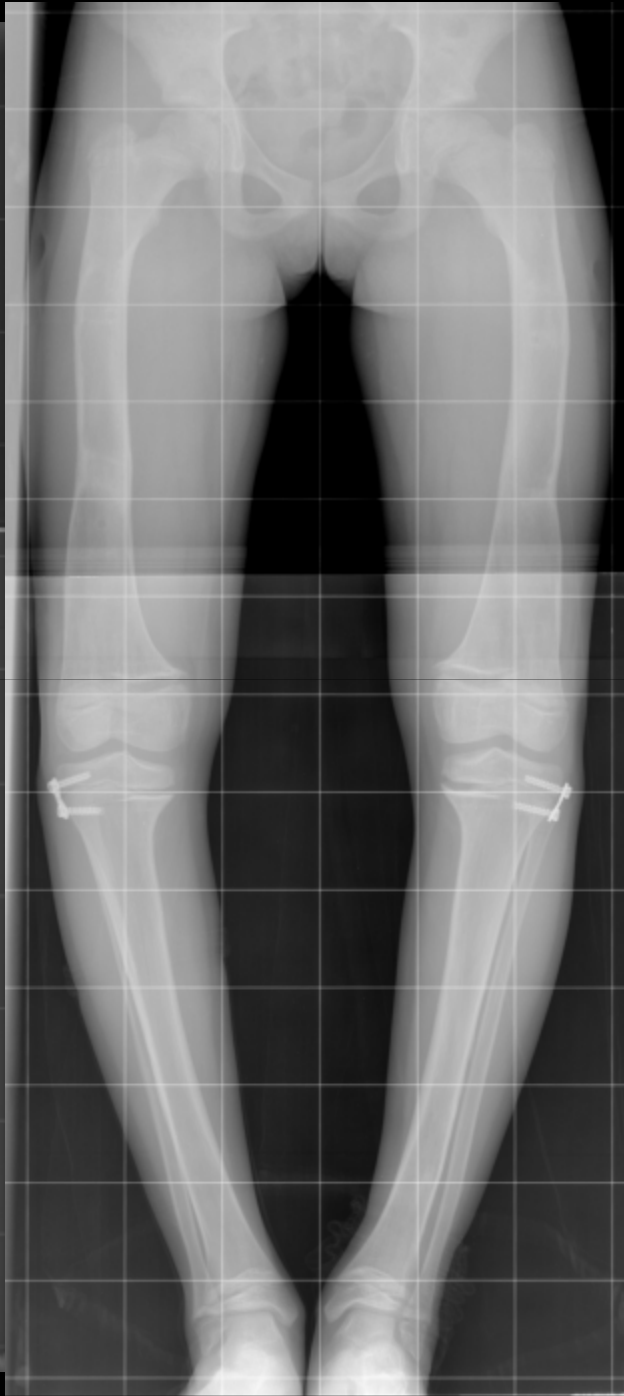
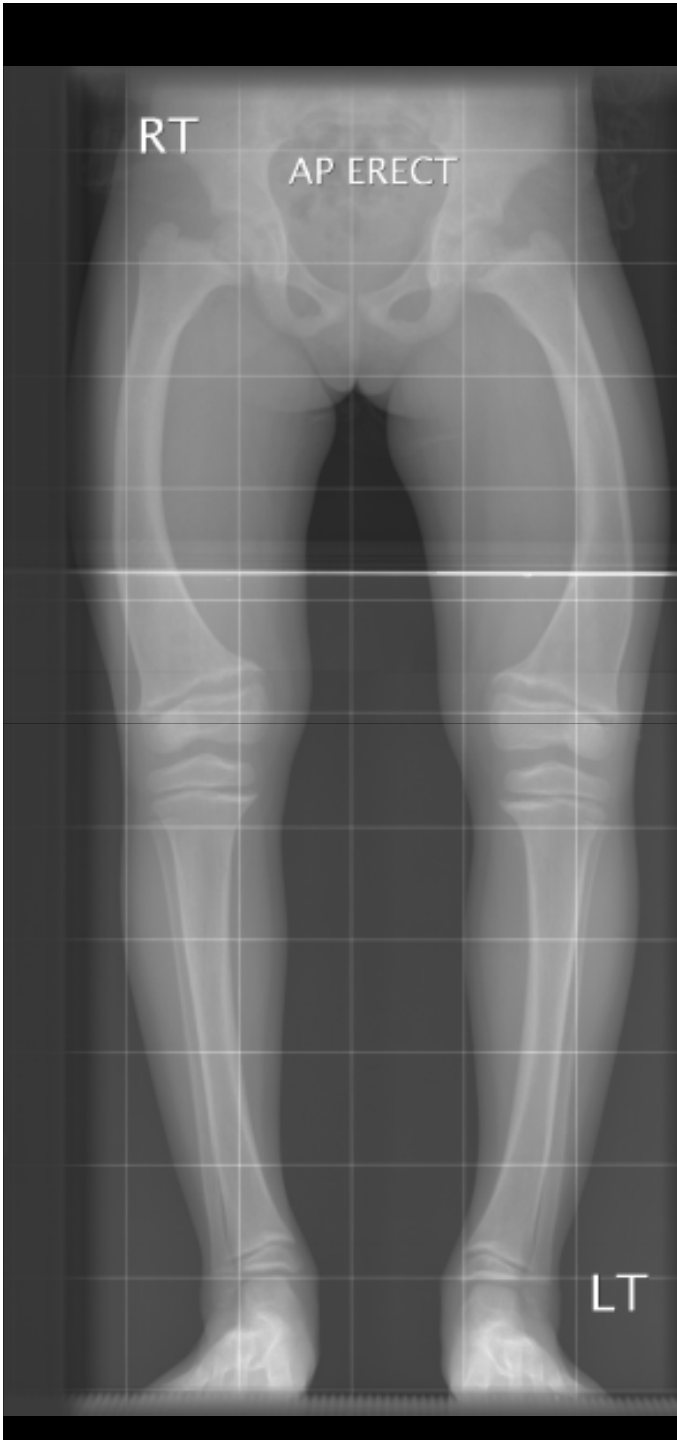
Surgical Indication?

- Symptomatic Genu Valgum
 - Walking difficulty
 - Running difficulty
 - Pain (medial or patellar)
- Mechanical axis lateral to the knee
- Cosmetic (?)

Guided Growth

- Avoid permanent Hemiepiphysiodesis
- Temporary hemiepiphysiodesis = GG
 - 2 Staples
 - Screw
 - 8-plate
- Stay away from the perichondrial ring
- Make sure the patient come back!
- Mind the rebound phenomenon

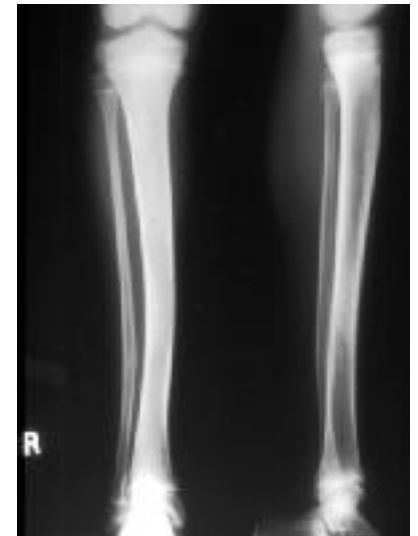



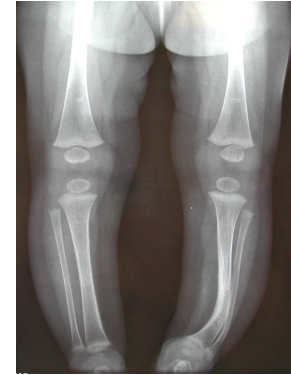Bowing of Tibia

Bowing of Tibia

- **Posteromedial bowing**
 - Benign
 - Calcaneovalgus foot (stretching)
 - Spontaneous correction in 2 years time
 - Possible residual LLD (3-8 cm)



Bowing of Tibia



- **Anterolateral bowing**
 - 50% NF1
 - Refer to Clinical Geneticist
 - Pseudarthrosis
 - At birth
 - After fracture
 - Prevent fracture with AFO/KAFO
 - Very difficult to treat!

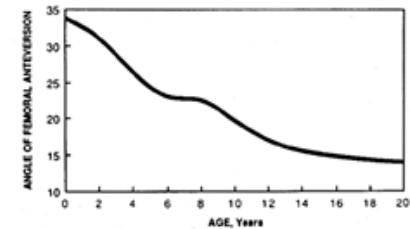
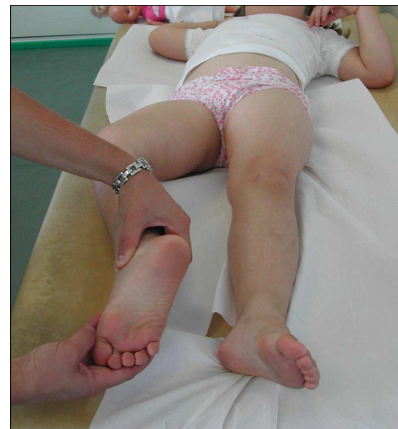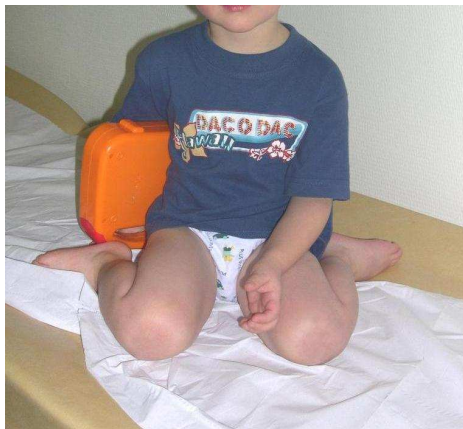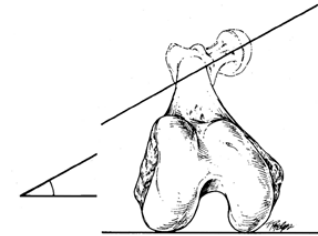
Torsional Deformities

Torsional Deformities

- Parents take the “problem” very seriously!
- Role of Bracing?
 - No evidence that it influence the natural history
 - Evidence of detrimental psychological effects on children
- Most of the professional basketball players are intoeing

Femoral Torsion

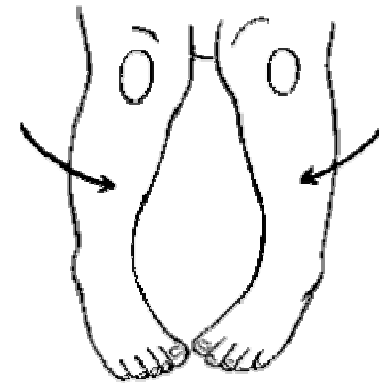
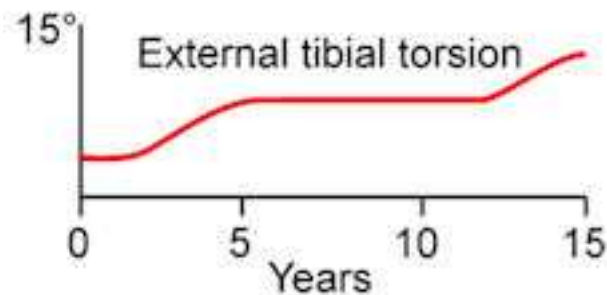
- Looks clumsy when they run
- Femoral anteversion improves spontaneously the first decade
- No evidence that persistent femoral torsion causes problems



Staheli. JBJS-Am, 1985

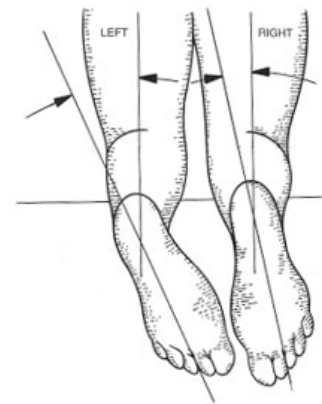
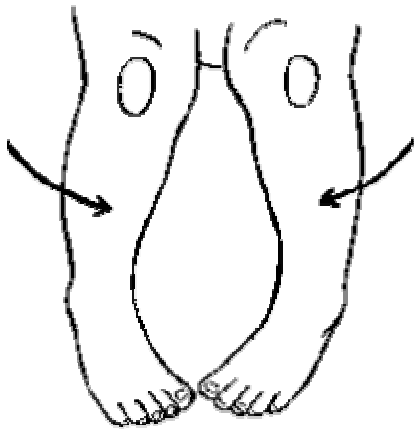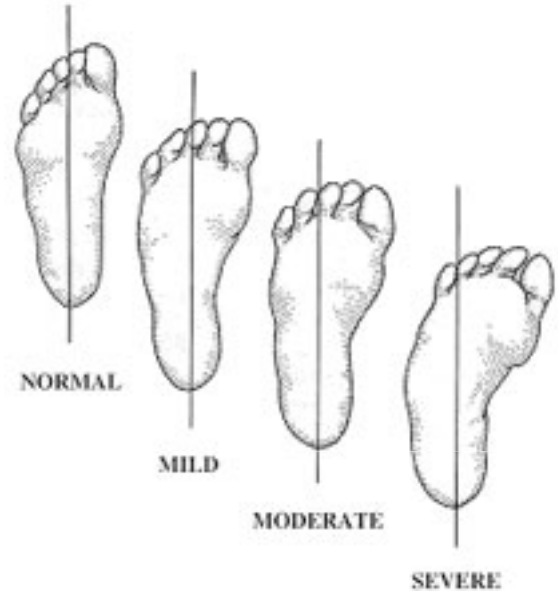
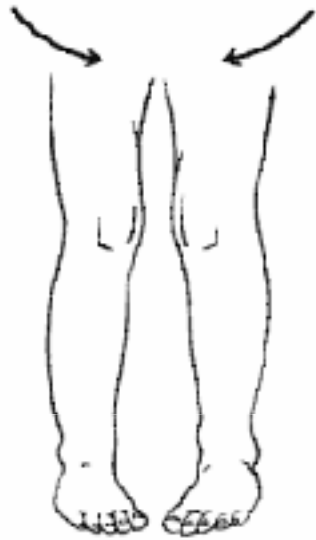
Tibial Torsion

- At birth: 5 degrees of external tibial rotation
- Spontaneous improvement can be expected
- Professional sprinters have more internal tibial torsion



Fuchs & Staheli. JPO, 1996

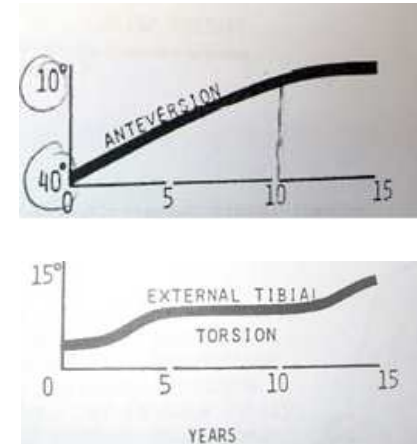
Intoeing?



Stay Out of Trouble...

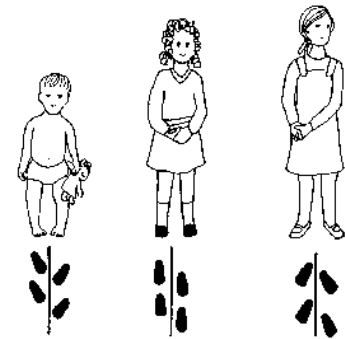
- If out-toeing patient:

- SUFE
- Coxa vara
- External tibial torsion



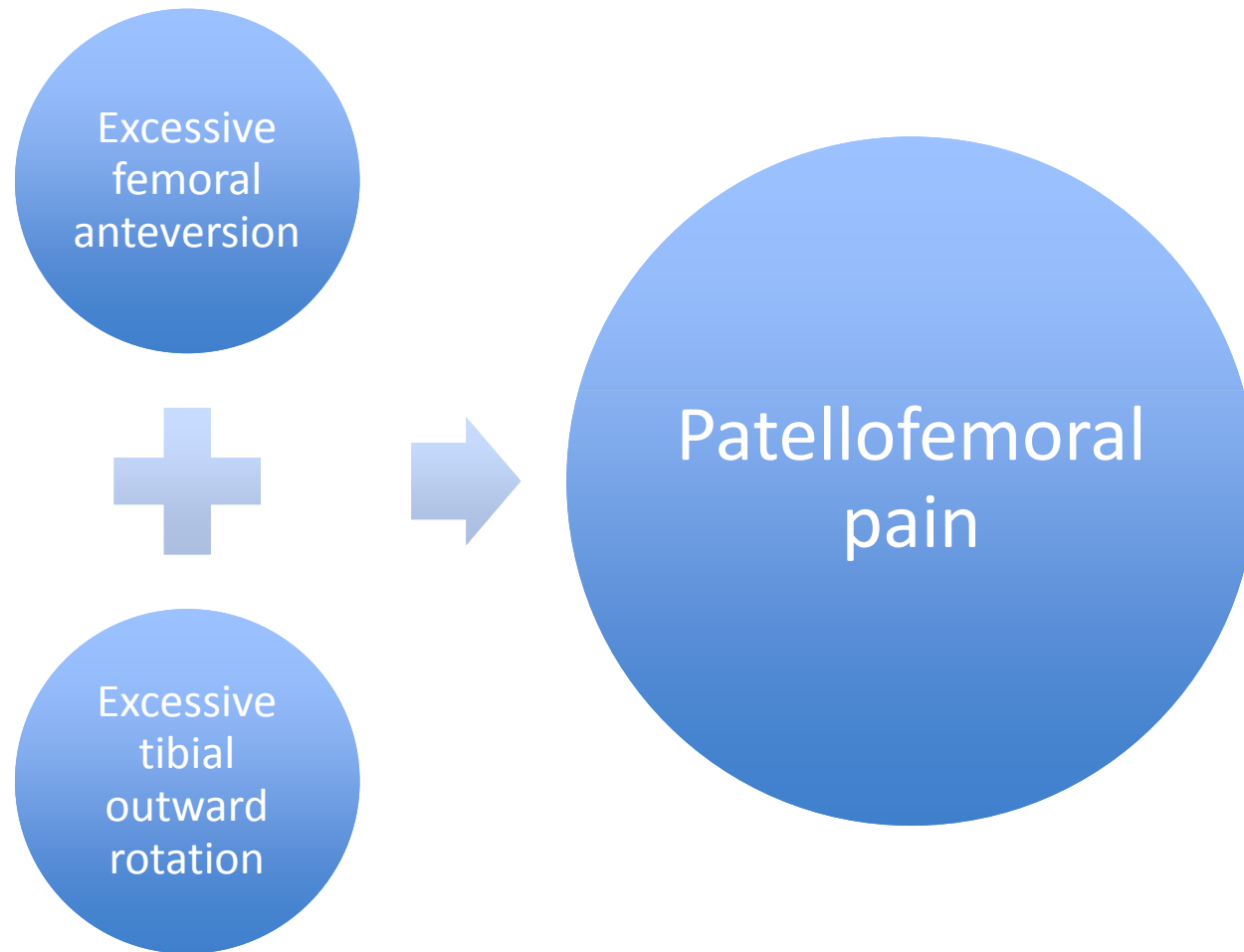
- If 1 foot is intoeing:

- Hemiplegia
- Neuromuscular disorder



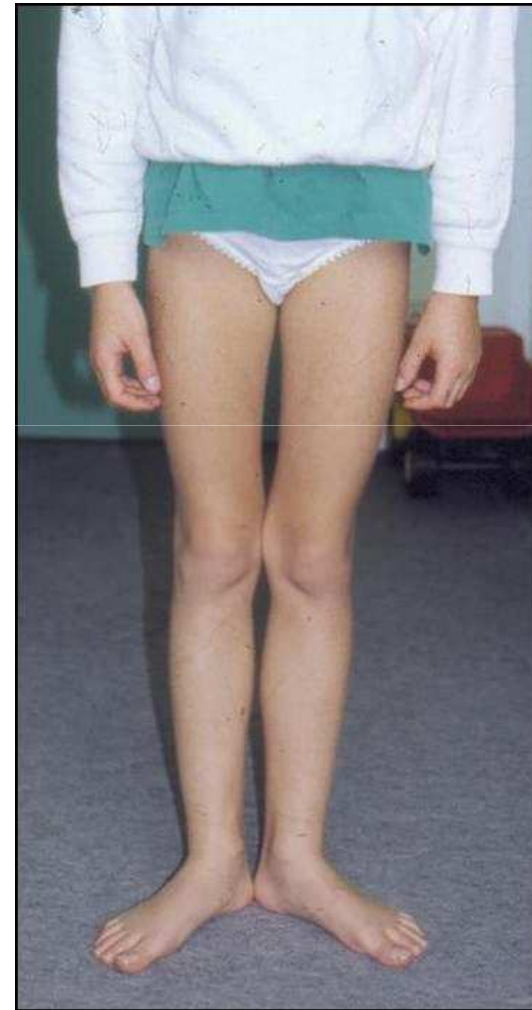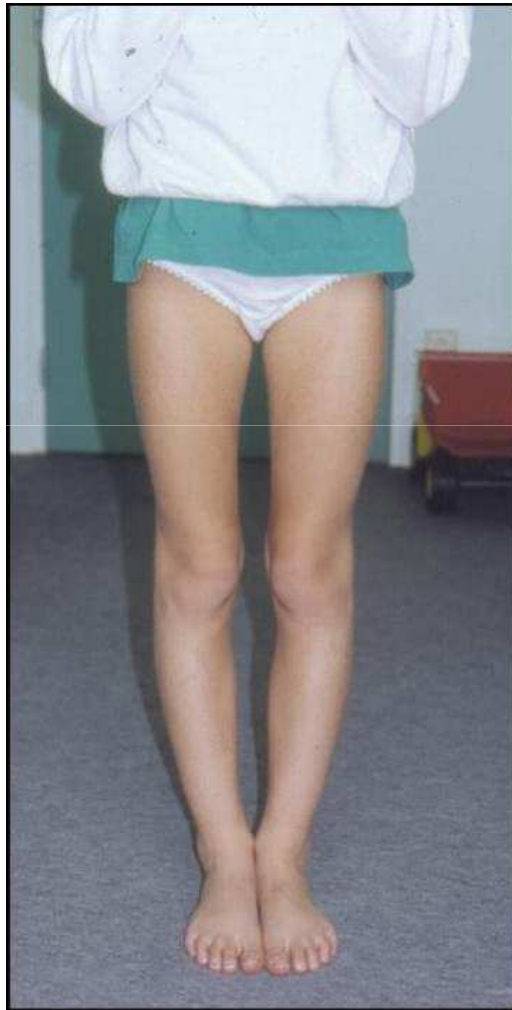- Limp? Pain? Search other etiologies!

Miserable Malalignment Syndrome



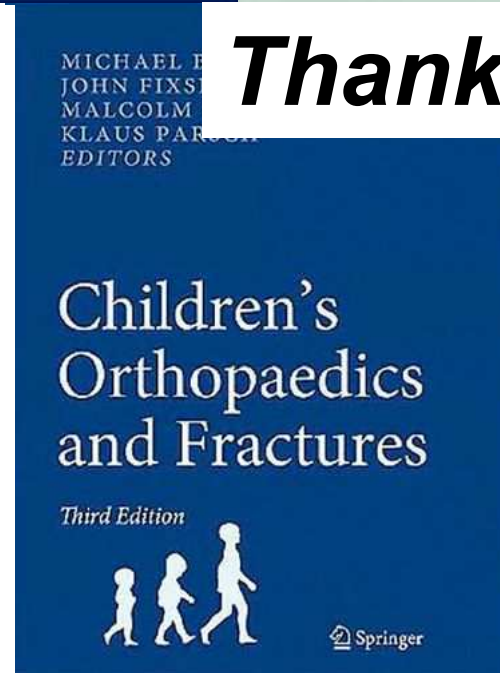
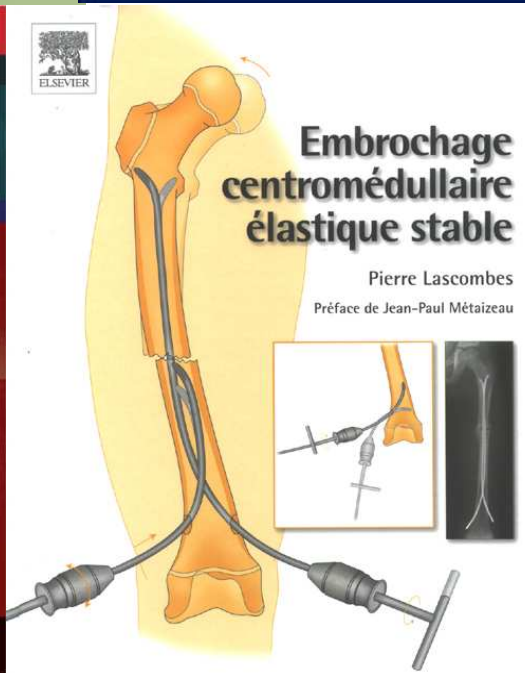
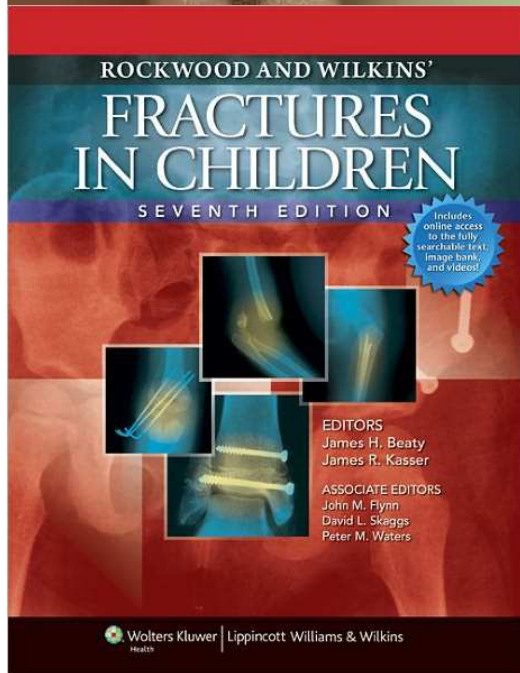

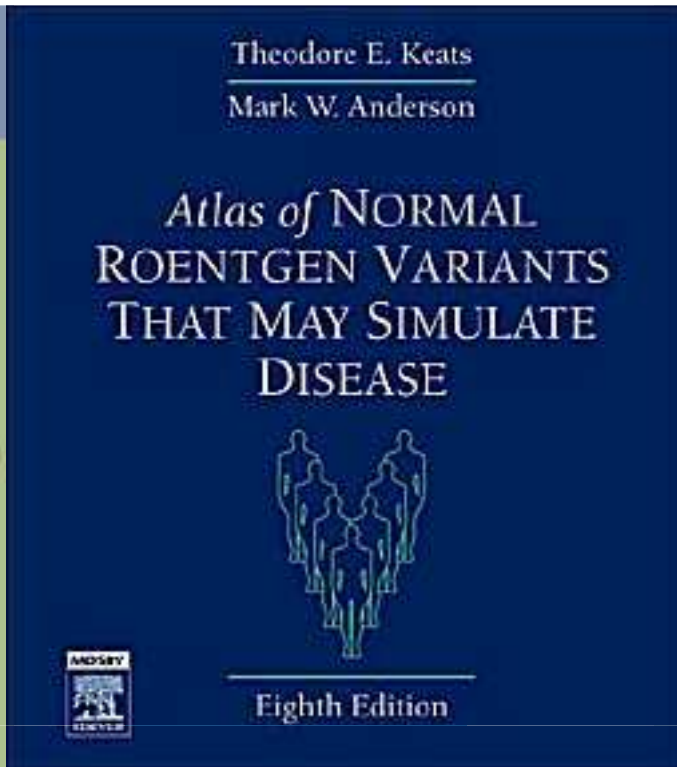

Bruce & Stevens. JPO, 2004

Miserable Malalignment Syndrome



Take Home Message

- Suspect Rickets (or skeletal dysplasia) if bowed legs and small stature
- Guided growth procedure
- Torsional deformity: no pain, no limp
- Residual inward tibial torsion may be associated with faster runner



Thank You...

