



Syndromes of Paediatric Orthopaedic Importance

Antoine de Gheldere, MD

Consultant in Children's Orthopaedics and Trauma

GNCH – Royal Victoria Infirmary
Newcastle upon Tyne, UK

Paediatric Orthopaedics Teaching, 16th April 2012

General Principles

- Orthopaedic genetic abnormalities: 5/1000
- Common syndromes vs. Once-in-a-career rare
- Remember:
 - Name
 - Orthopaedic manifestations
 - Associated systemic problems

The Steps to Diagnosis of a Syndrome

- ① History/family history/physical exam
- ② Informal exam of the parents
- ③ Leave the room: consult textbook/internet
- ④ Reexamine the child: specific features
- ⑤ Appropriate X-rays confirming diagnosis
- ⑥ Consult clinical Geneticist
- ⑦ F/up with all results: plan of action/treatment

And then...

- Don't lose sight of the true goal
- Guide parents to support group
- Associated problems
 - Potential sources of trouble
 - Contact your anaesthetist prior surgery

Trouble When Operating on a Child with a Syndrome

- *Downs*: congenital heart disease, UCS instability, infections, hypothyroidism
- *Morquio*: USC instability, myelopathy
- *Marfan*: Mitral valve prolapse, aortic dilatation
- *NF*: hypertension
- *Proteus*: difficult intubation
- *Larsen*: USC instability, airway problems
- *Nail-patella*: abnormal renal function

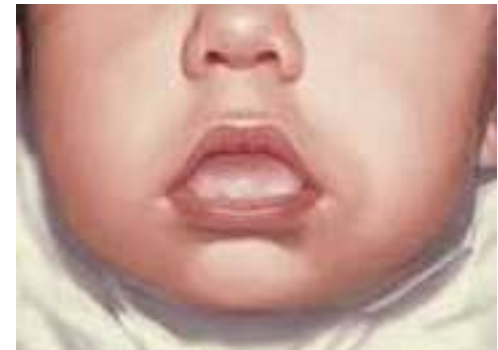Trouble When Operating on a Child with a Syndrome

- *Turner*: cardiac abnormalities
- *Prader-Willi*: morbid obesity
- *Beckwith-Wiedemann*: difficult intubation
- *VACTERL*: congenital heart defects, renal abnormalities
- *ED*: UCS instability, abnormal wound healing
- *KT*: thromboembolism
- ...

Top 10 Syndromes

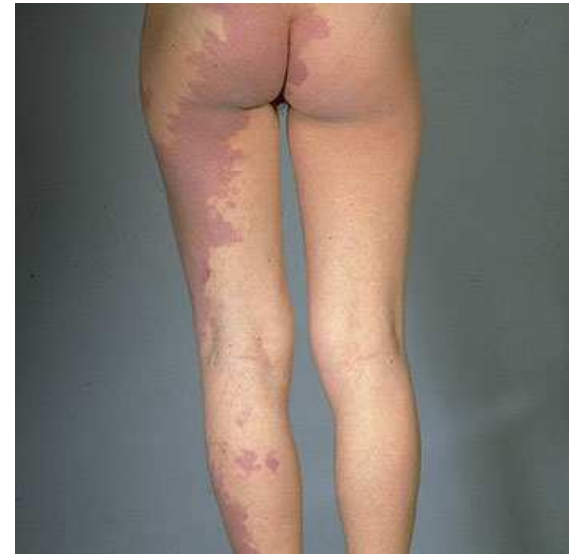10. Beckwith-Wiedemann

- Large CP
- LLD
- 10% of abdominal tumor (Wilm)
 - *Refer to paediatrician/oncologist*



9. Klippel-Trenaunay Weber

- LLD: limb hypertrophy
- Cutaneous nevi and varicosities
 - Simple resection of venous/lymph = recur
- Prior surgery:
 - MRI: extension of the lesion
 - *Blood available*



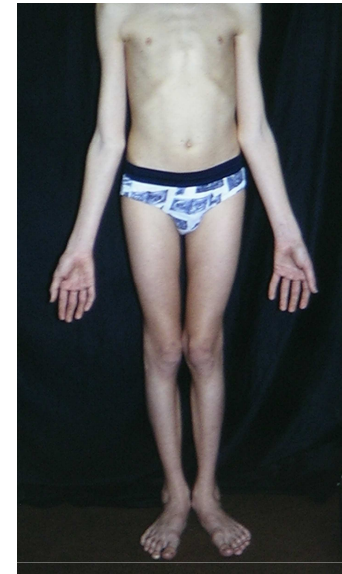
8. Proteus



- Overgrowth:
 - Limb hypertrophy
 - Macrodactyly
 - Other incongruity
- Bony overgrowth can be treated vs. soft tissues
- *Avoid surgery* (especially lengthening procedure):
 - Recurrences/complications +++
 - Foot macrodactyly: Amputate/ray resection
 - Angular deformities can recur quickly

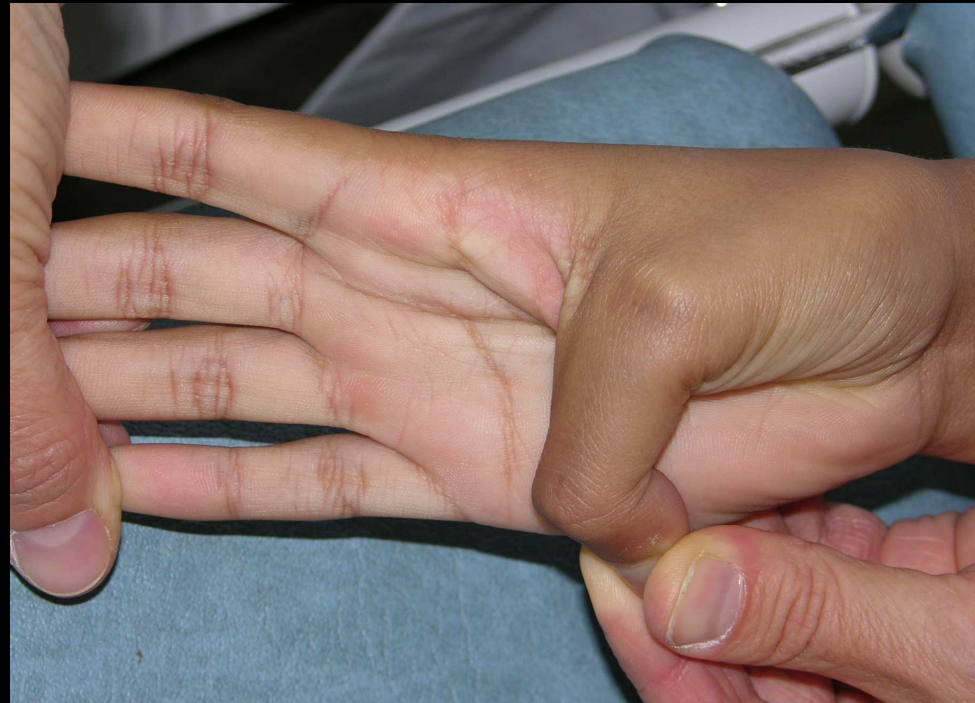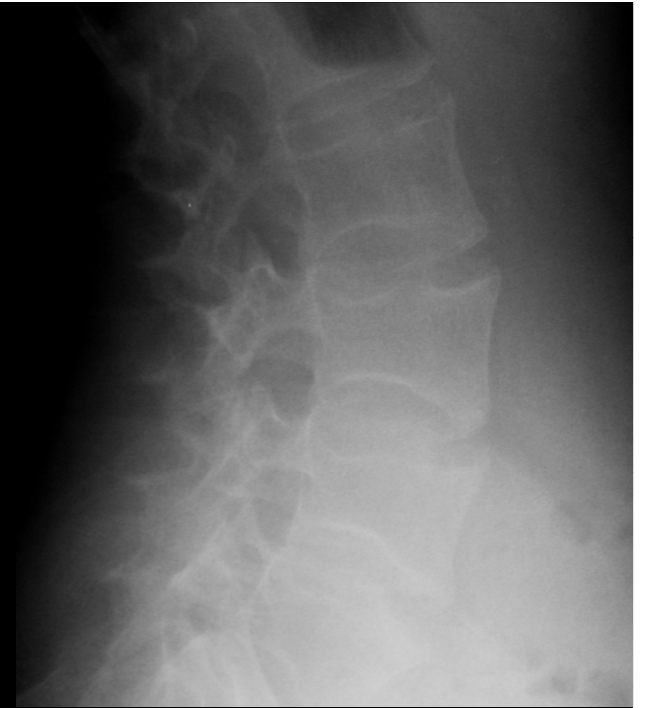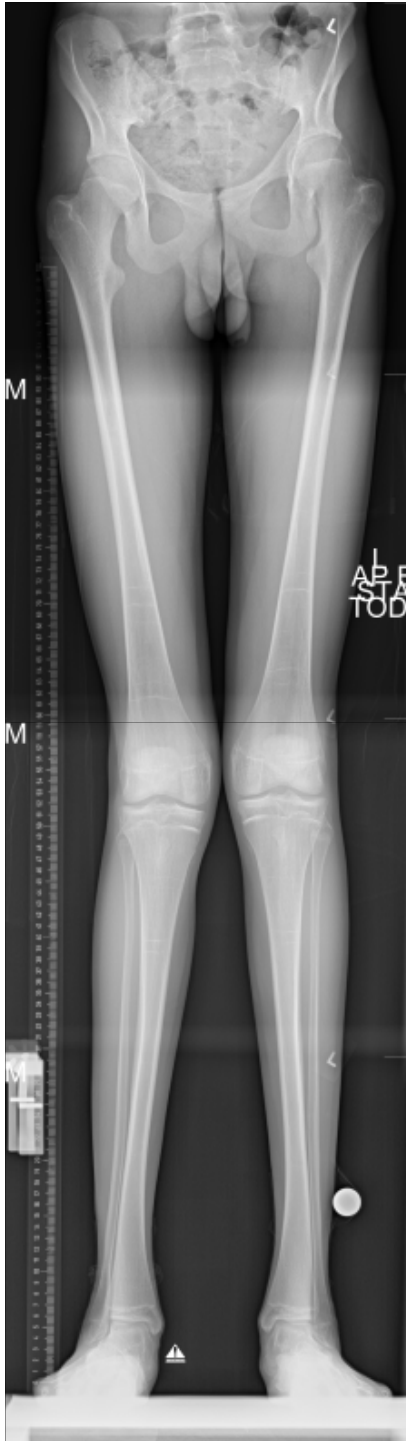
7. Marfan

- 1/10,000
- Autosomal dominant
- Clinical manifestation vary greatly:
 - Long flat feet/scoliosis/ligament laxity
 - Marfan vs. Marfanoid appearance
- *Refer to: geneticist, cardiologist (cardiac surgery first?), ophthalmologist*



7. Marfan

- Spine:
 - Tricky scoliosis (difficult to manage with brace)
 - High rate of complication after spinal fusion
- Hips:
 - Hip protrusio



6. VACTERL/VATER

Vertebral (vertebral defect)

Anal (imperforate anus)

Cardiac

Tracheal (tracheoesophageal fistula)

Esophageal (tracheoesophageal fistula)

Renal or **R**adial

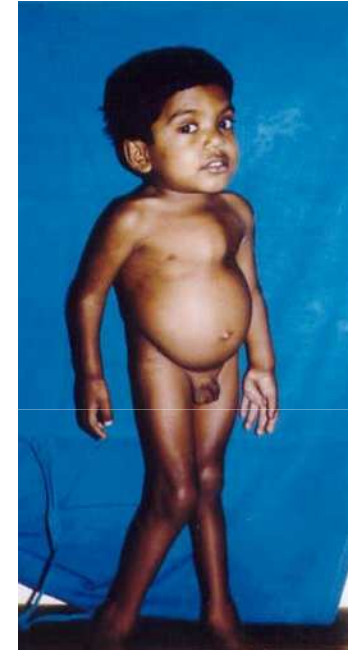Limb

6. VACTERL/VATER

- Spine surgeons
- Hand surgeons
- Keep in mind:
 - High rate of congenital *heart abnormalities*
 - High rate of *renal abnormalities*

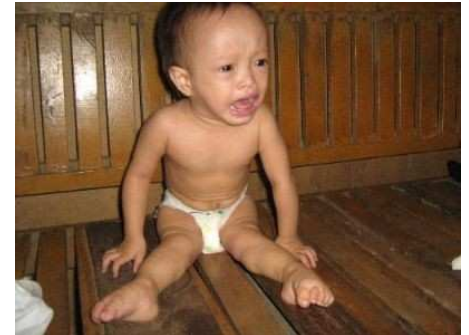5. Mucopolysaccharidoses

- Type 1 to 4
- Hurler:
 - Odontoid hypoplasia
 - Spinal canal soft-tissue mass
- Morquio:
 - Very unstable knees
 - C1-C2 instability (can lead to death the first year)
 - *Always have a F/E cervical spine film before GA*



4. Larsen

- Many joint and spine problems
 - Dislocated knees (ACL absent)
 - Patellar malalignment
 - Radial head dislocations
 - Popliteal pterygium (very difficult to manage)
 - Abnormal cervical spine segmentation
 - Kyphosis (later in childhood)
 - Myelopathy (vs. poor musculature)
 - *Always get a C-spine series before the first year (or if any clinical changes)*



4. Larsen

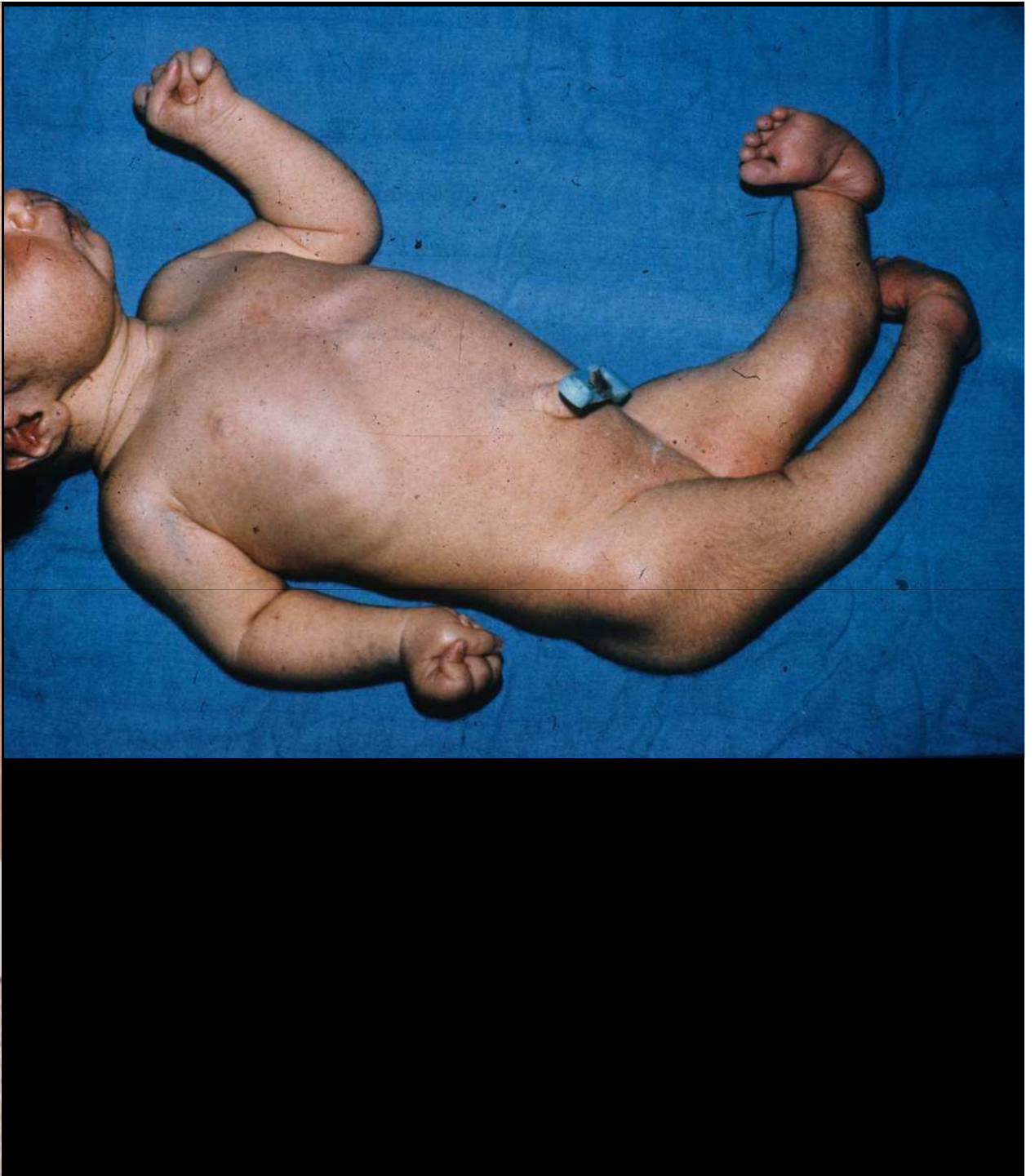
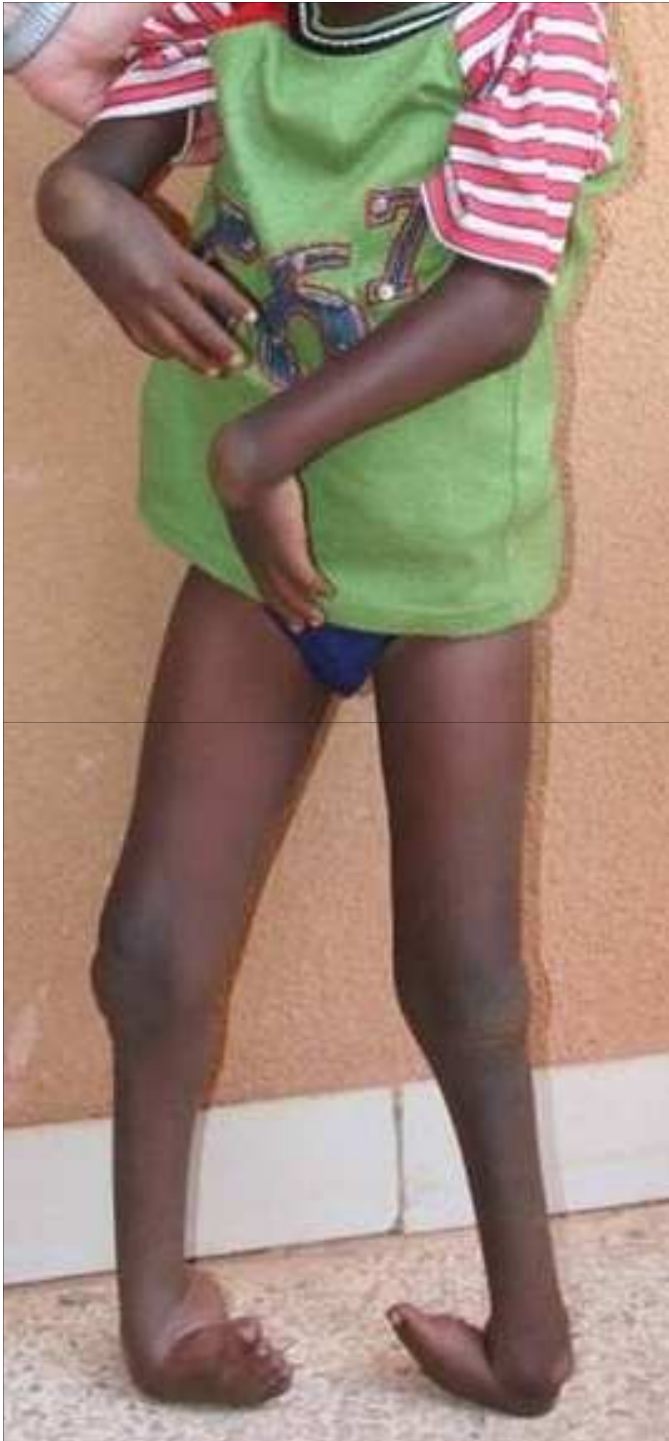- Many curious radiographic finding:
 - Elbows asymptomatic sublux/dislocations
 - Wrists with multiple carpal centers
 - Fingers contractures with good function
 - Curious asymptomatic foot appearances
 - ...
- ... but rarely any of these require surgery!

3. Arthrogryposis and Other Contractural Syndromes

- Not disease/diagnosis, but only symptom
- ARTHRO = joint
- GRYPOS = stiff
- >120 different syndromes:
 - Arthrogryposis Multiplex Congenita (AMC)
 - Larsen syndrome
 - Freeman-Sheldon syndrome
 - Pterygium syndromes

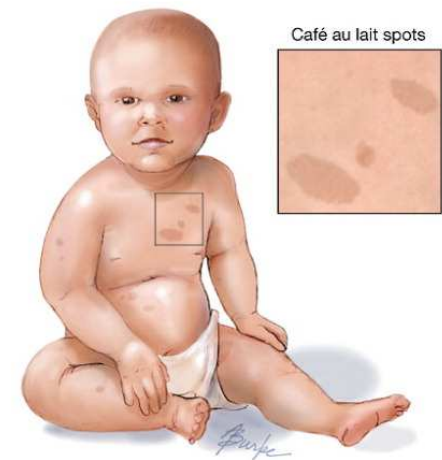Arthrogryposis Multiplex Congenita (AMC)

- Joints stiffness:
 - Physical therapy may cause fracture
 - Soft tissue release early in life
 - Corrective osteotomies closer to bone maturity
- Hip dislocation:
 - Often failure of closed reduction
- Knee contracture: F or E
- CTEV-like: often failure of the Ponseti



2. Neurofibromatosis – NF1

- 1/3000
- Neurofibromas: <2% malignant degeneration
- X-rays: tumor-like bone changes
- Clinical diagnosis!

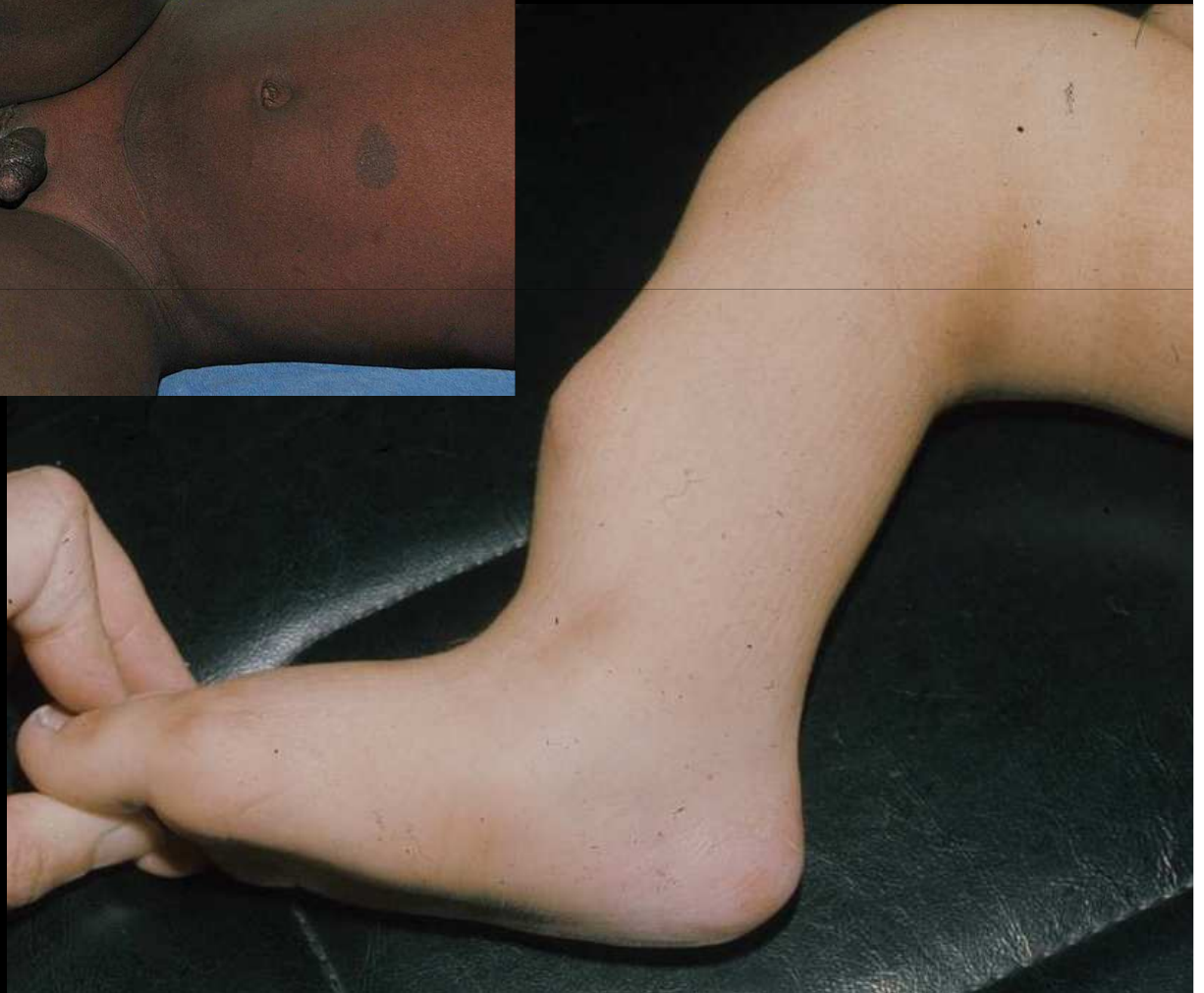
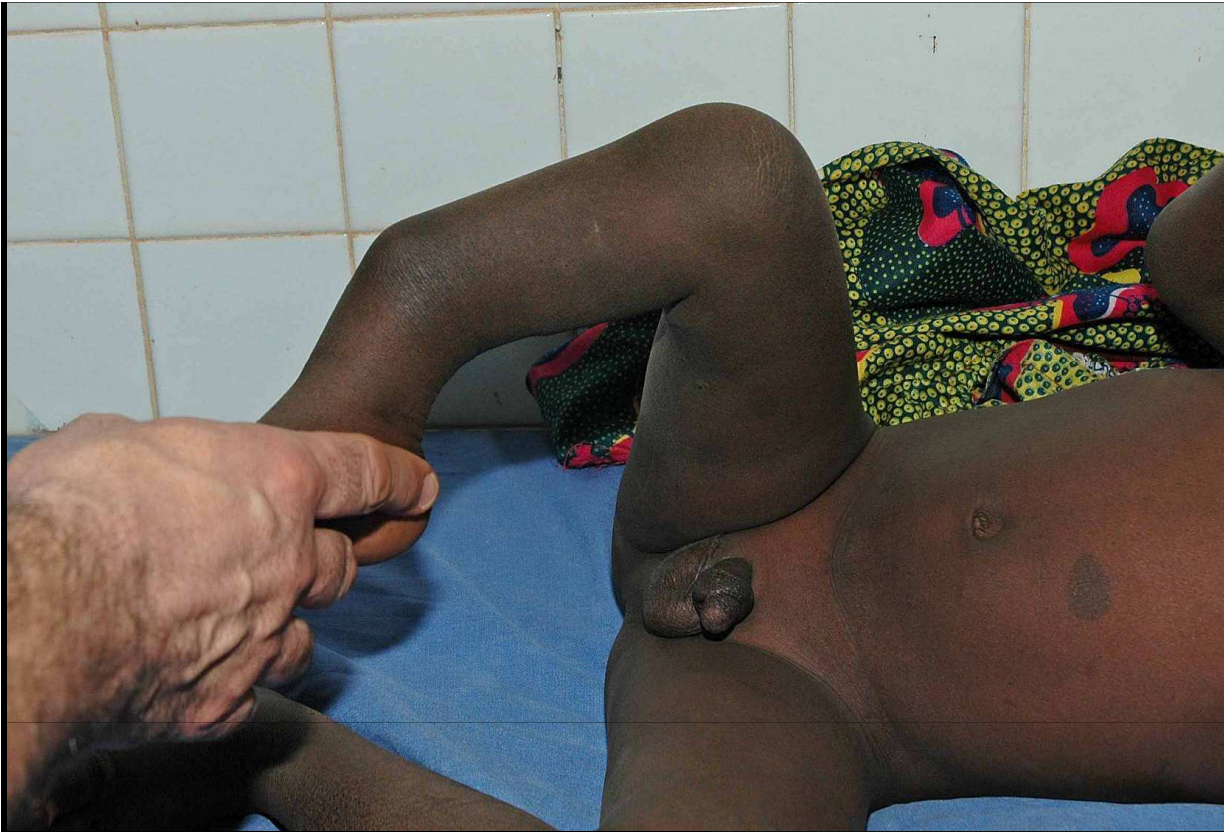
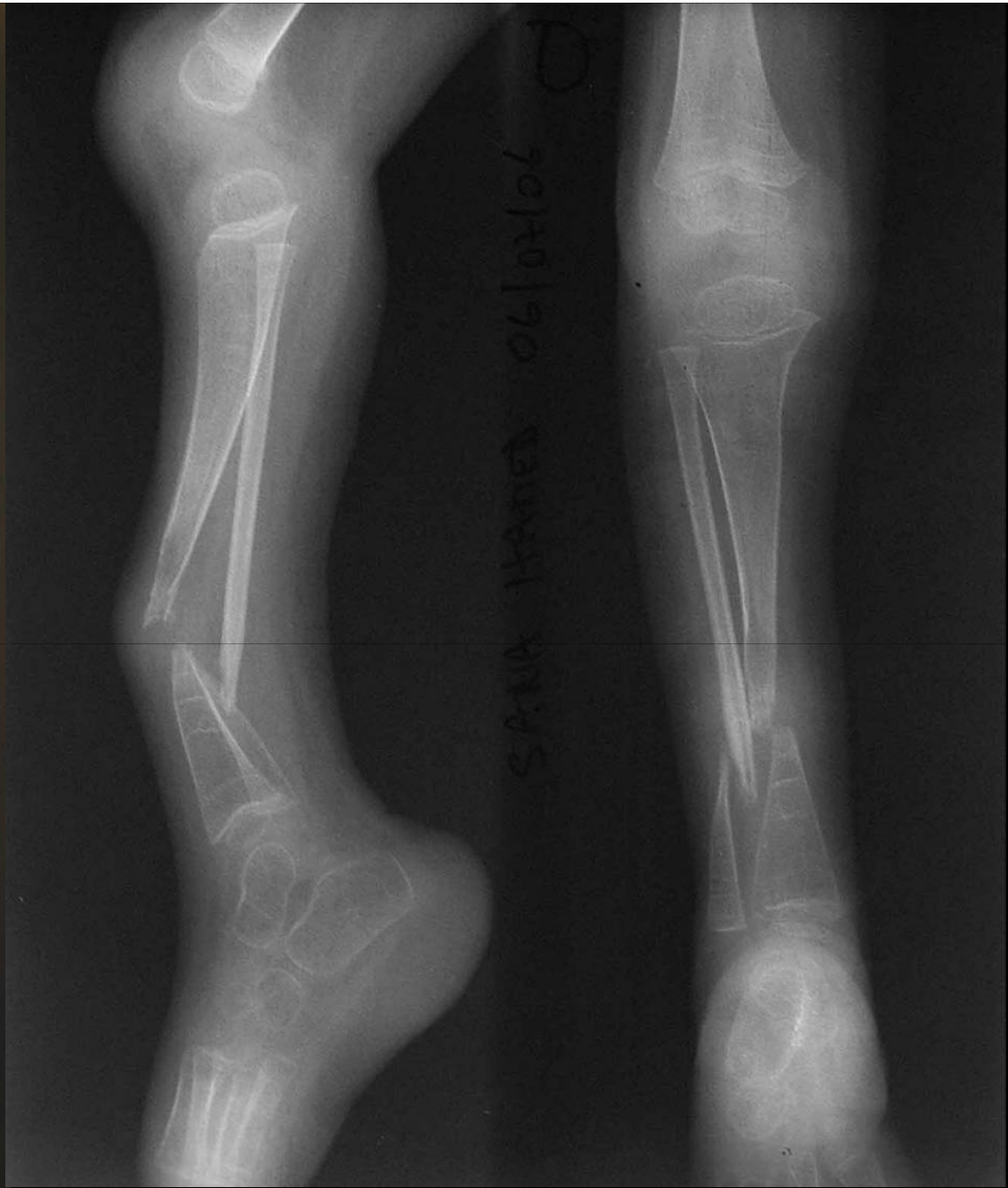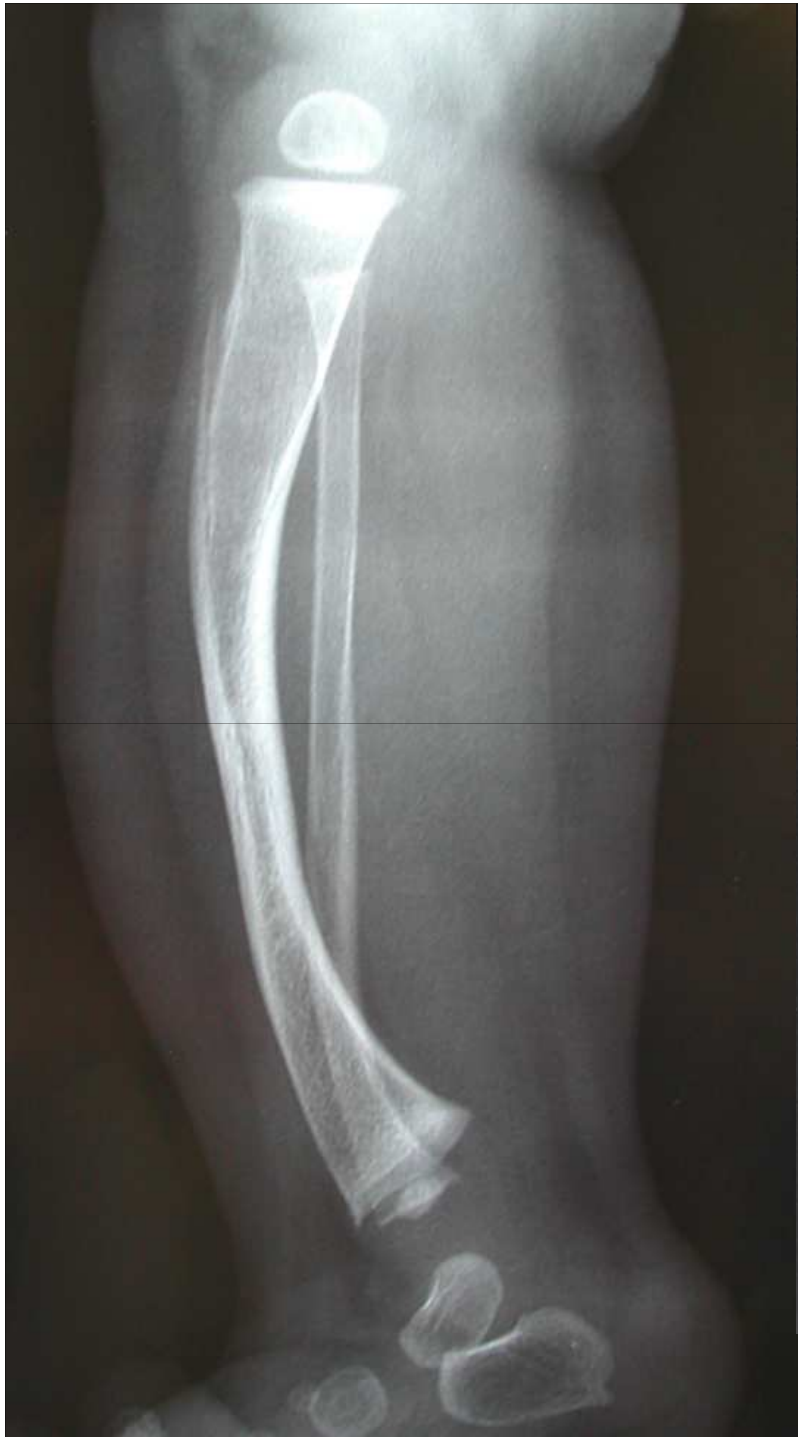2. Neurofibromatosis – NF1

- Spine:
 - Start earlier and relentless
 - Short/sharp curve (vs. idiopathic)
 - Bracing often ineffective
 - Screw fixation difficult (eroded pedicles)
 - Lower rate of spine fusion
 - Higher risk of paralysis (kyphosis)
 - Cervical instability (erosion of cervical pedicles)

2. Neurofibromatosis – NF1

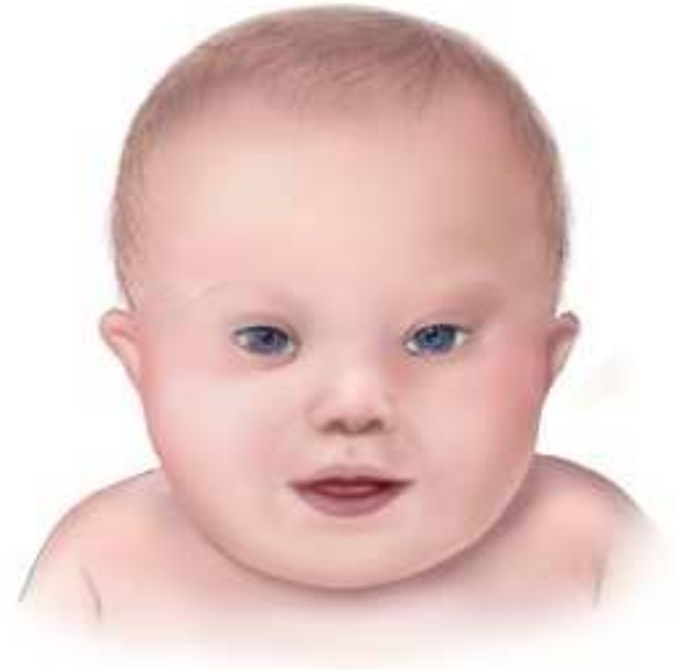- Congenital Pseudoarthrosis of the Tibia
 - ... but also: femur, clavicle, forearm
 - Bracing protection (young kids)
 - Many different treatment:
 - Ilizarov, bone transfer, bypass grafting, ESIN...
 - No osteotomy through affected zone
 - Stay out of trouble:
 - Prepare family for multiple procedures... amputation!
 - F/up to maturity



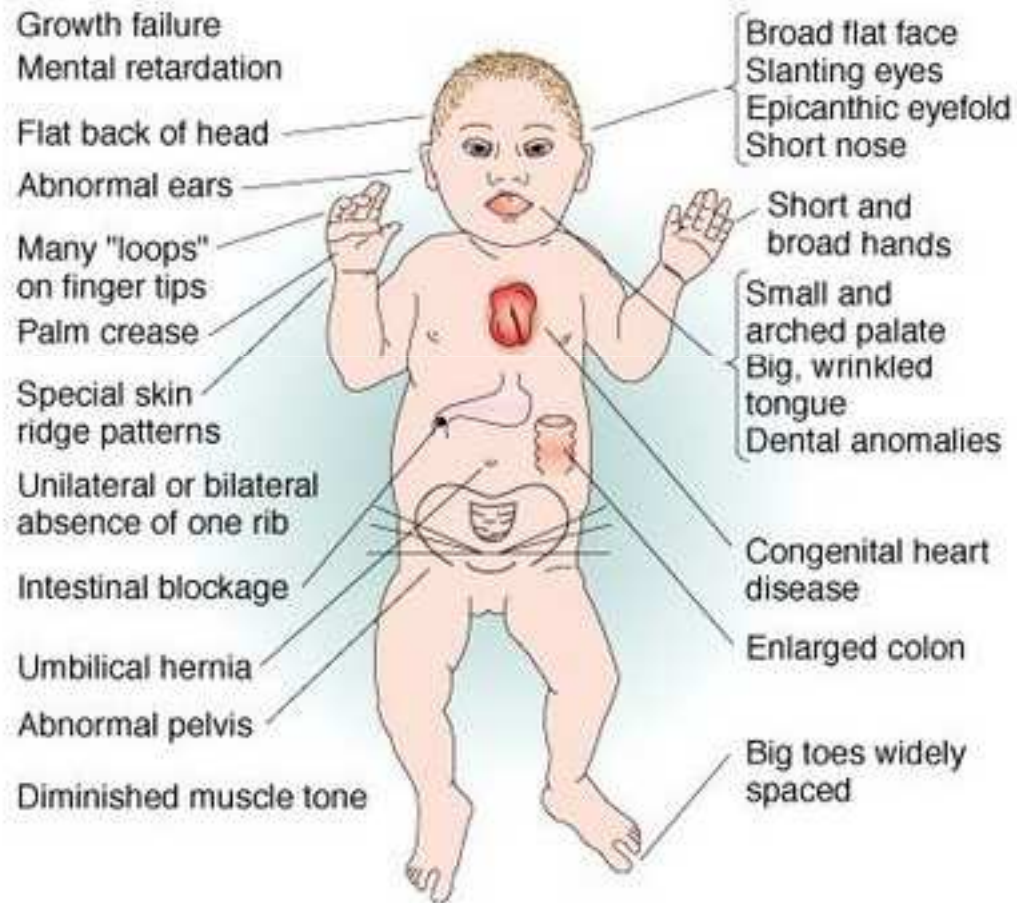


1. Down

- 1/660 live births
- Many unusual physical/radiographic findings
 - Function remain very good
 - Focus on the problems
- Spine:
 - Cervical instability, myelopathy
 - Scoliosis
 - spondylolisthesis

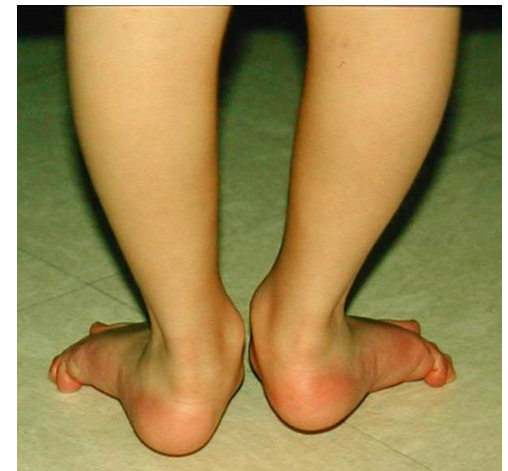

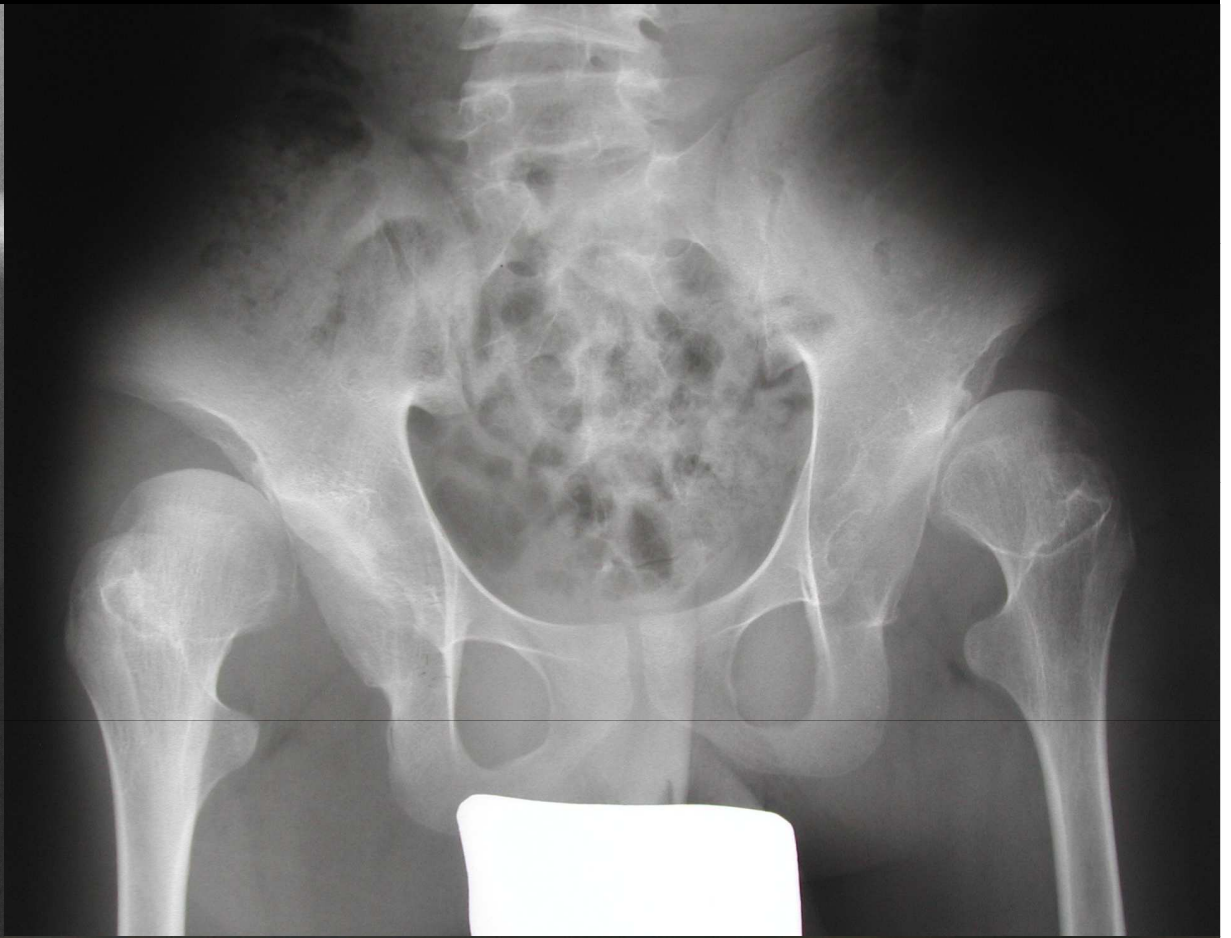
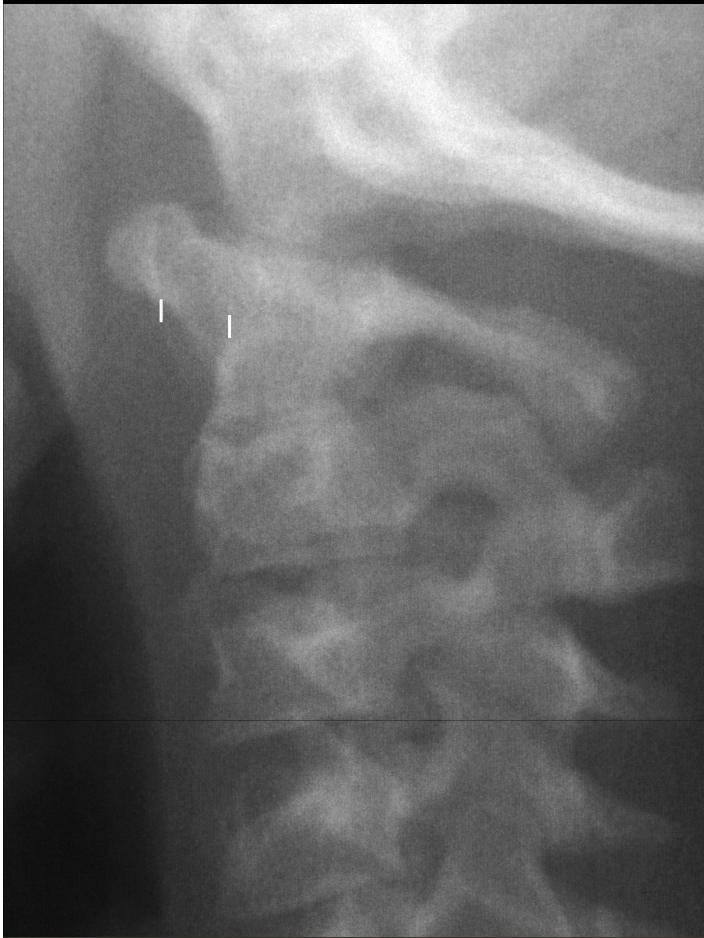1. Down



1. Down

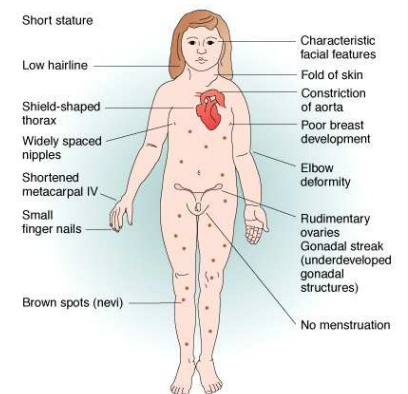
- Ligament laxity (shoulder instability)
- Hip instability:
 - Late dislocation (2-10 years)
 - “Good looking” acetabulum
 - Difficult to treat (50% complications!)
- Hip pain:
 - Late dislocation vs. SUFE
 - Higher risk of AVN



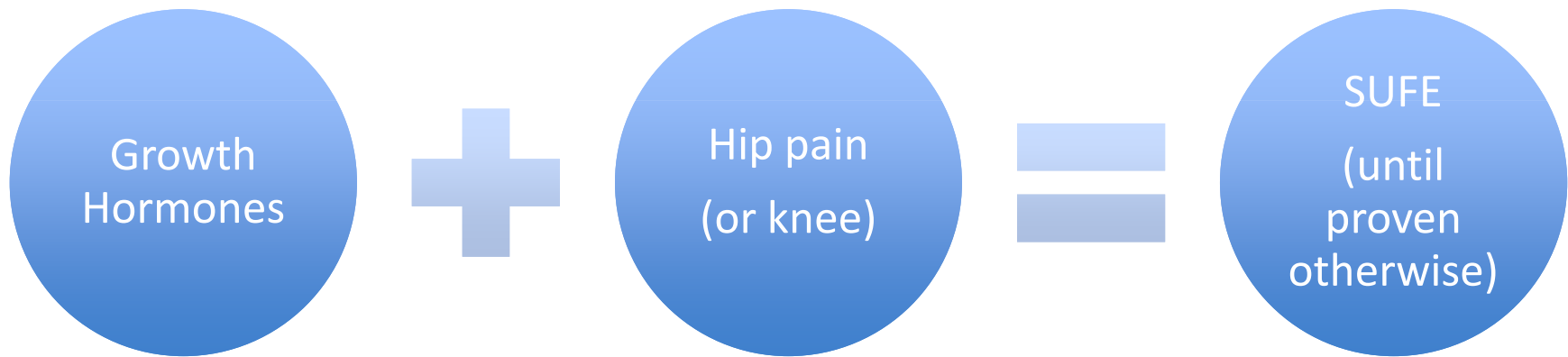

Other Pit Falls

- ***Rett syndrome***
 - Normal girl (X-linked) at 1-2 years
 - Progressive dementia, autism, ataxia...
 - Don't ignore the spine:
 - Sometime normal life expectancy
 - Similar to a neuromuscular spinal deformity
- ***Turner syndrome*** = growth hormones
 - Rapid worsening of scoliosis
 - SUFE

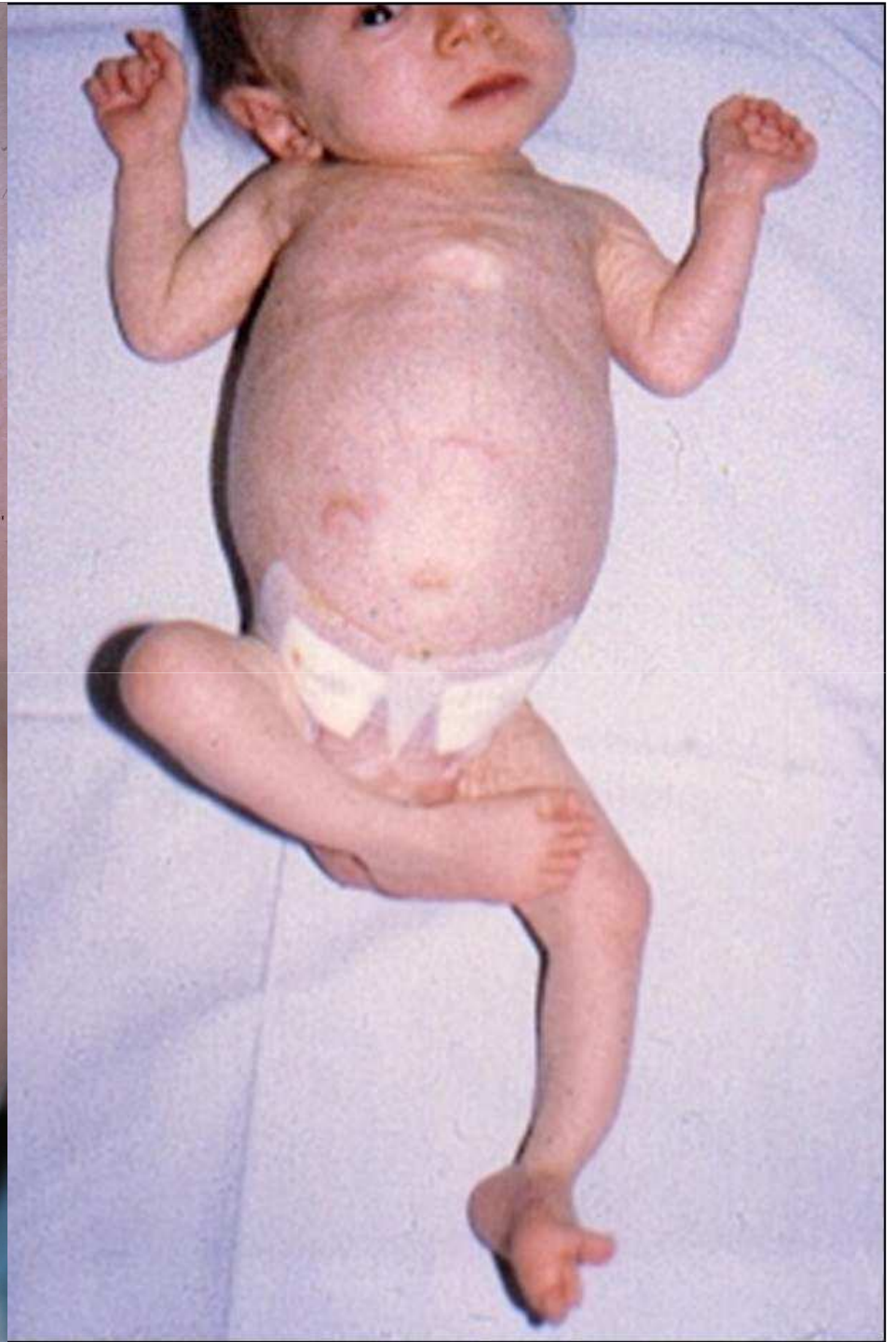
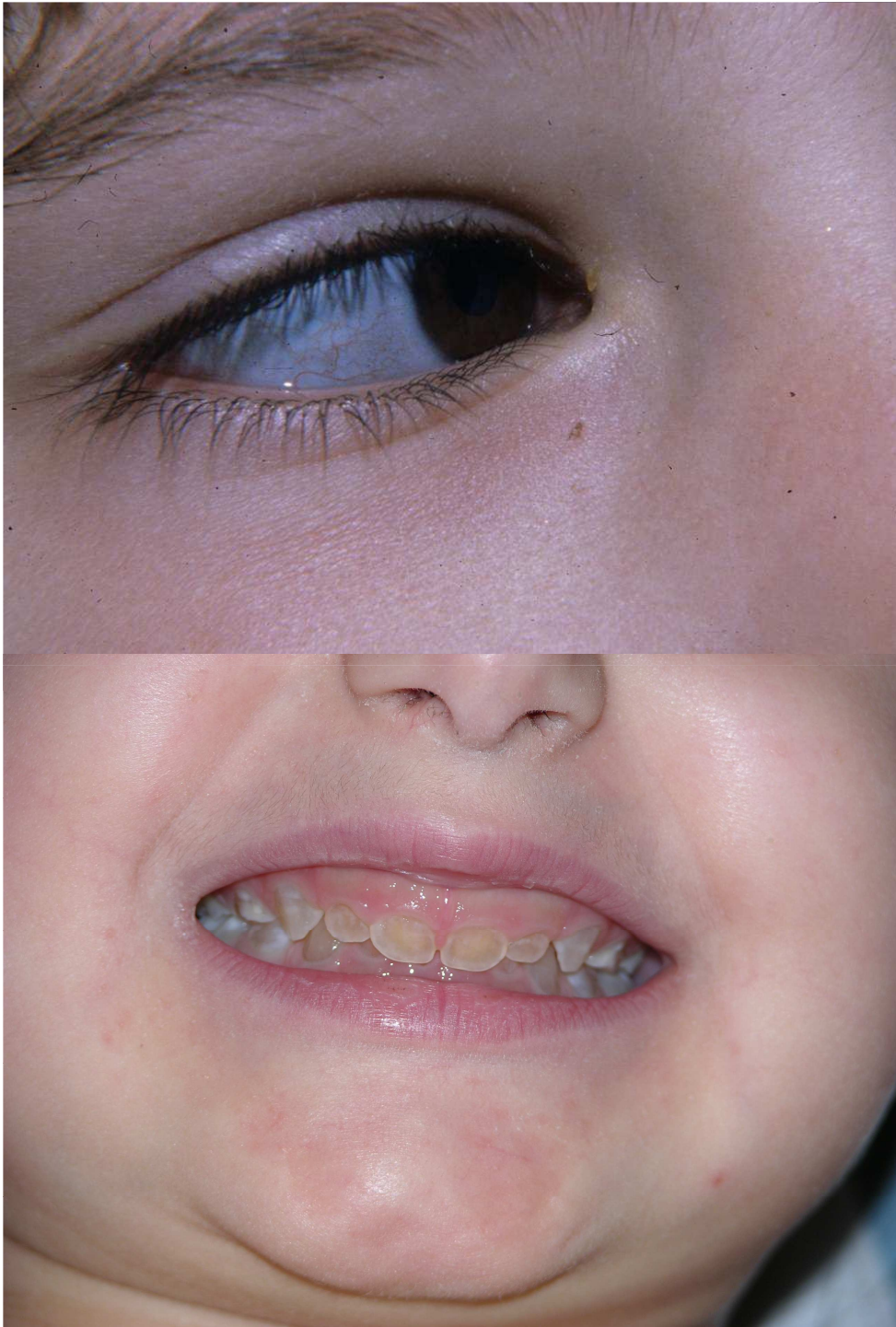
Stay out of Trouble...



Osteogenesis Imperfecta - OI

- Defect of Type 1 collagen:
 - Fragile bones
 - Ligamentous laxity
 - Spinal deformities
 - Hearing loss
 - Bruises
 - ...
- Dilemma: OI vs. NAI



Rickets

- Aetiologies:
 - Nutritional rickets (Vit. D)
 - Metabolic disorder
- Key for success:
 - Medical treatment first (endocrinologist)
 - Correction of deformities (overcorrection?)
- Bilateral SUFE (renal osteodystrophy)

Osteopetrosis

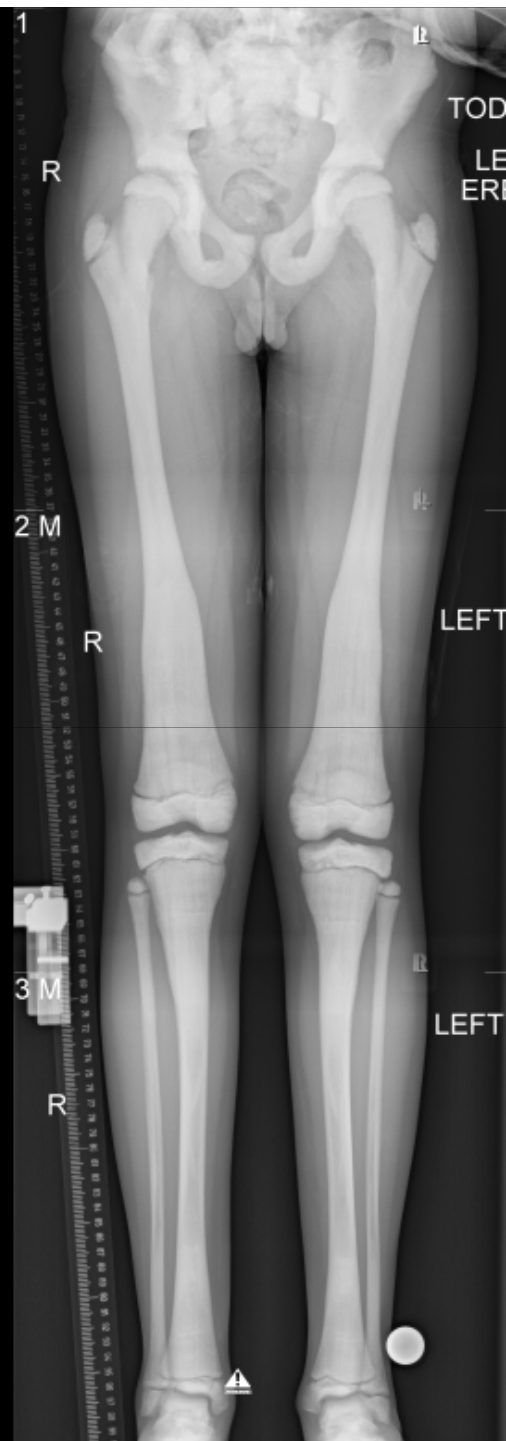
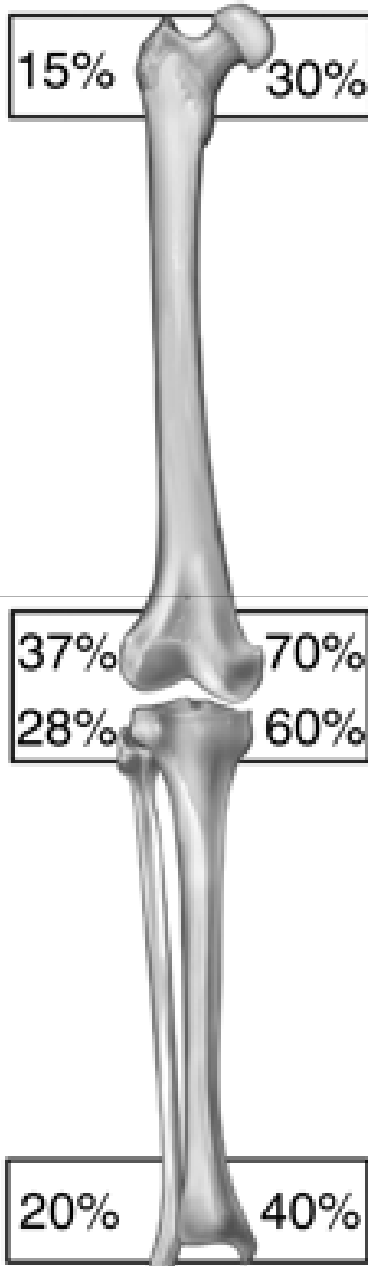
- Genetic defect osteoclast (turn over)
- OSTEO = bone
- PETROS = rock
- Very very very very dense bone... but fragile!
- Fractures:
 - Slower to heal
 - Nightmare to fix
- Higher risk of osteomyelitis

Complete limb **Limb segment**

15% 30%

37% 70%
28% 60%

20% 40%

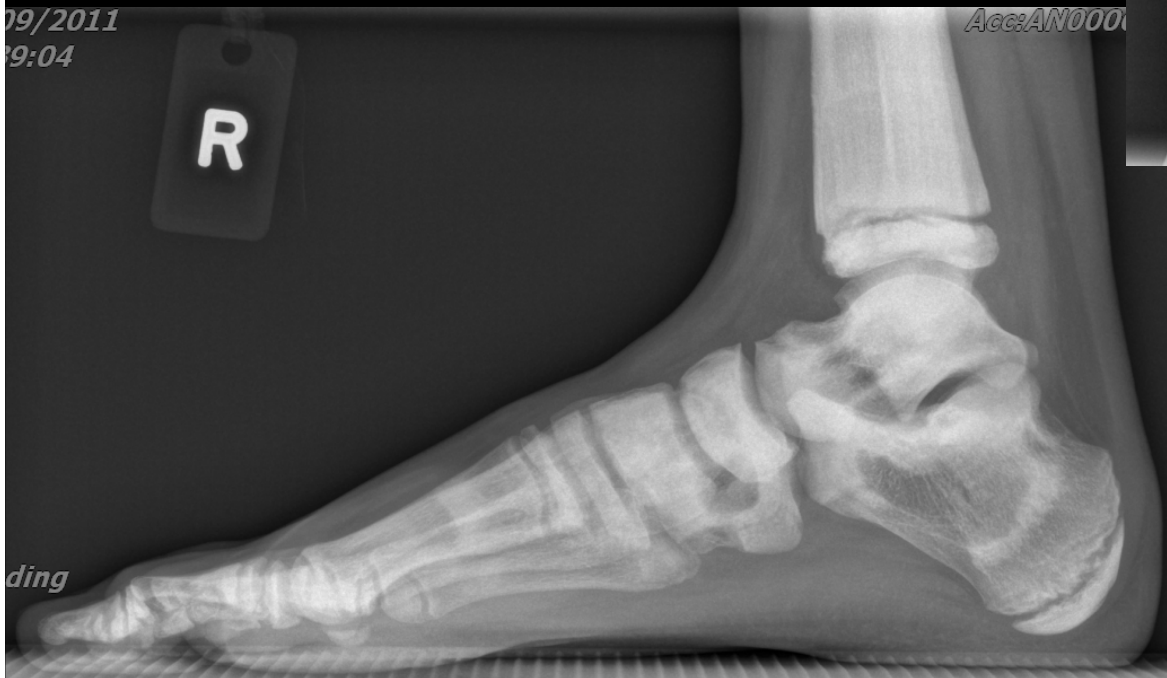
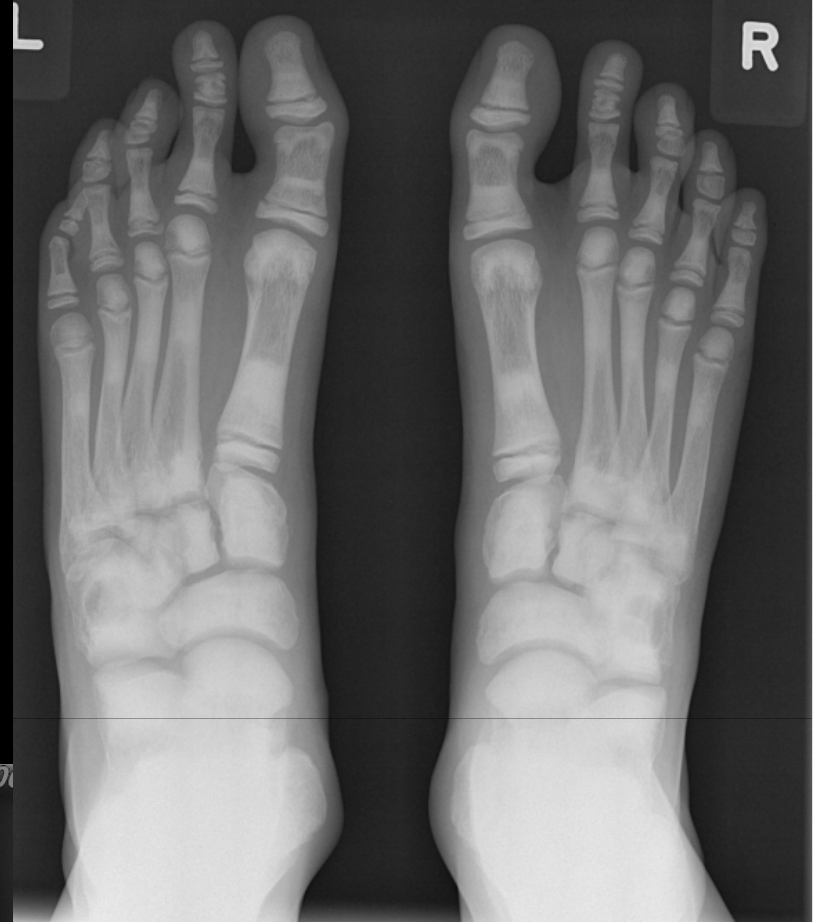
09/2011
9:04

R


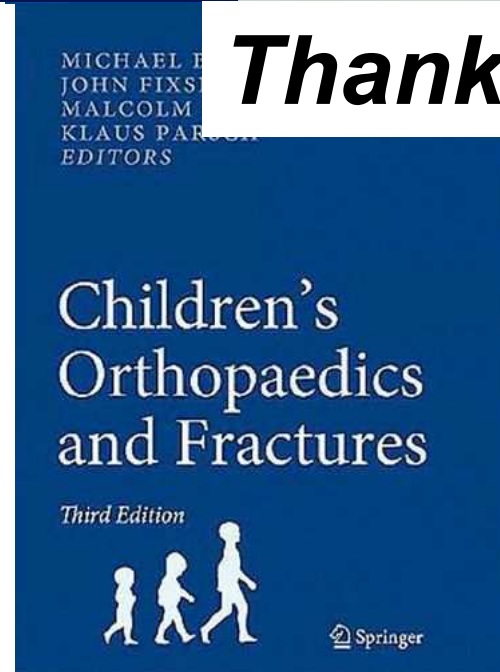
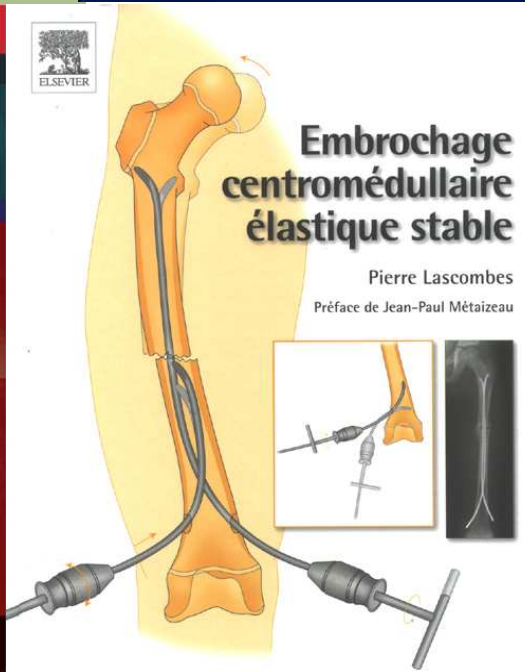


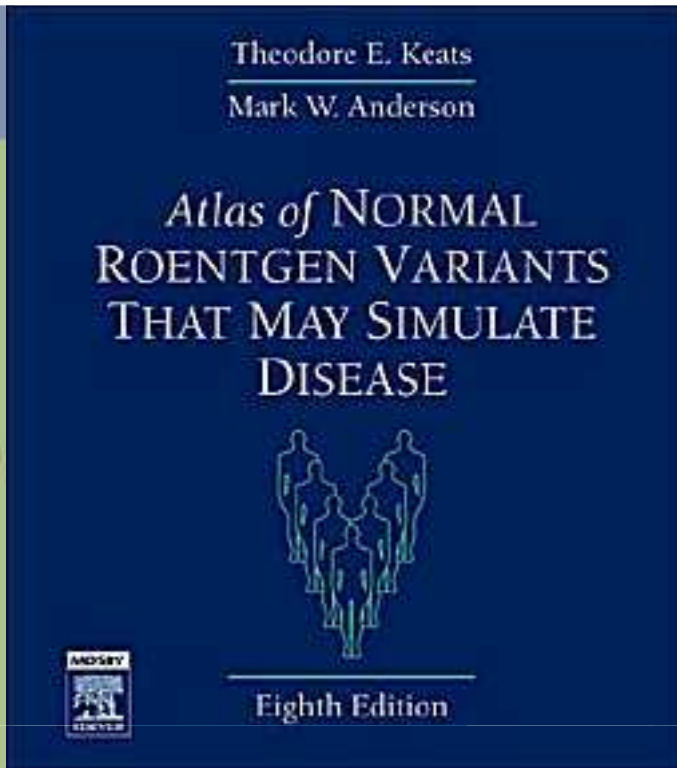

Acc:AN000

ding



Take Home Message

- Syndromes are unavoidable
 - Think about it!
 - Discover the syndrome
 - ... before it finds you (and gets you in trouble!)
- Keep your friends close:
 - Geneticist
 - Endocrinologist
 - Radiologist
 - ...



Thank You...