

# Management of Clubfoot Deformity

Sanya Adedapo

James Cook University Hospital

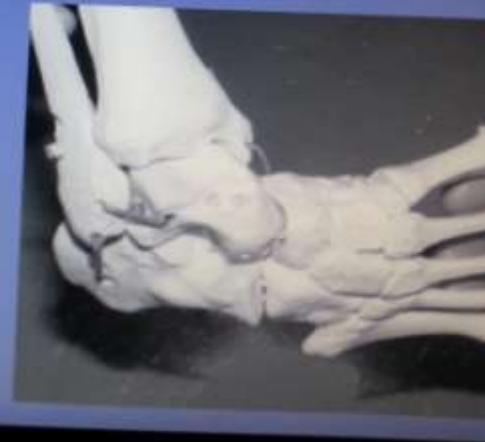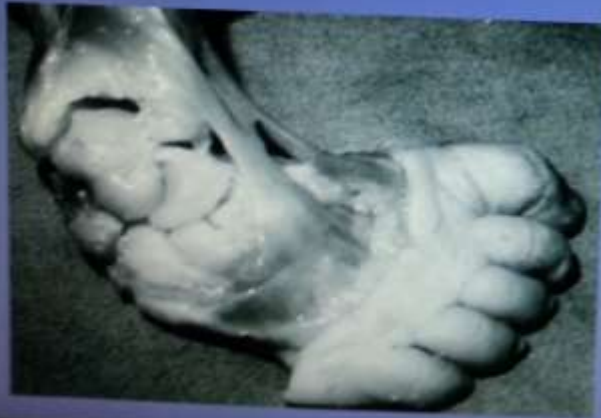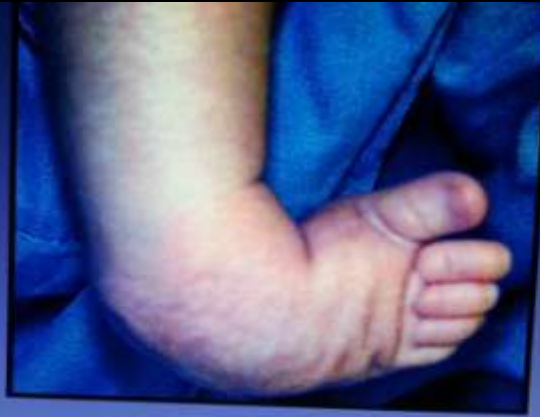# For the ones

- That escaped Ponseti
- That didnt work with or couldn't be bothered with Ponseti
- That Ponseti didn't apply
- Or that you silently screamed O dear under your breath.

# At the risk of labouring the point

- If its too simple to be true. It probably is that simple.
- Its biology, simples

# The deformities are severe



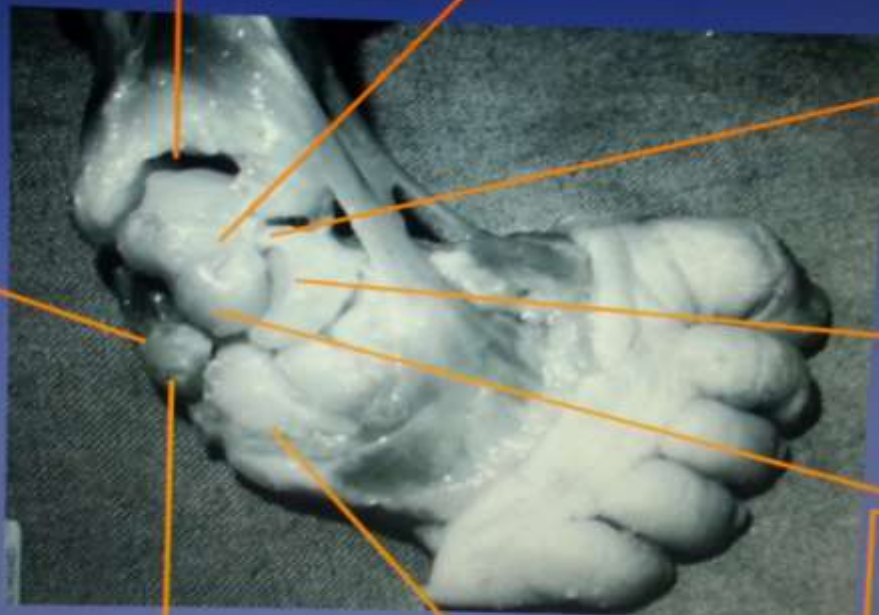


Severe tibio-talar  
plantar flexion

Medial talar neck inclination

Severe  
medial  
displacement  
of navicular

Adducted  
and  
inverted  
calcaneus



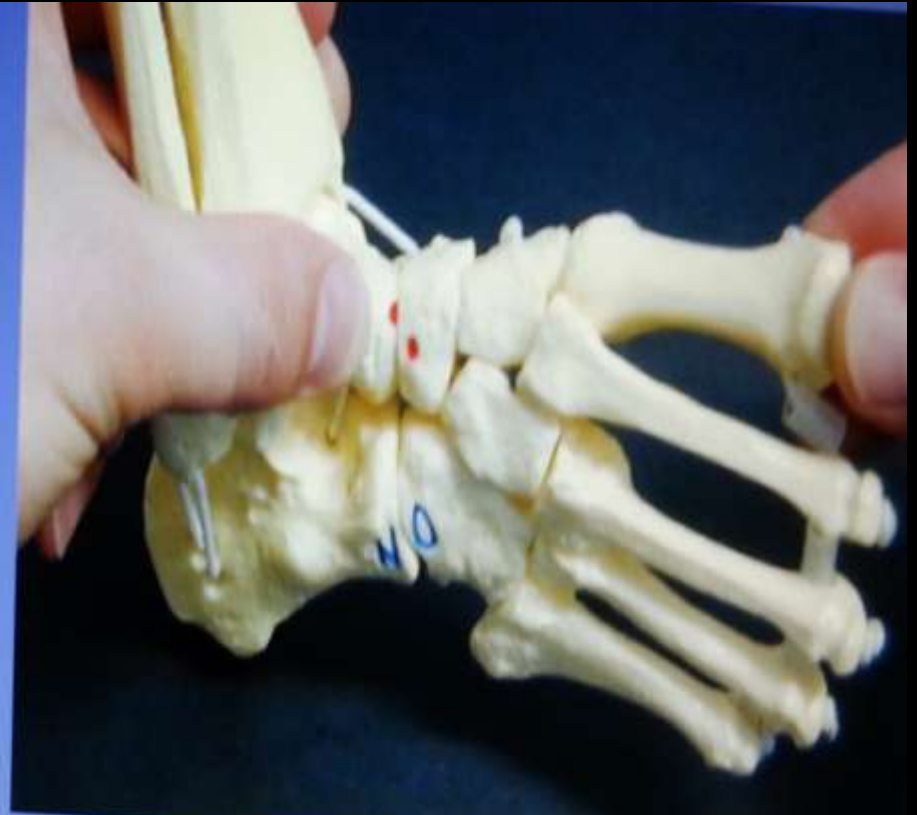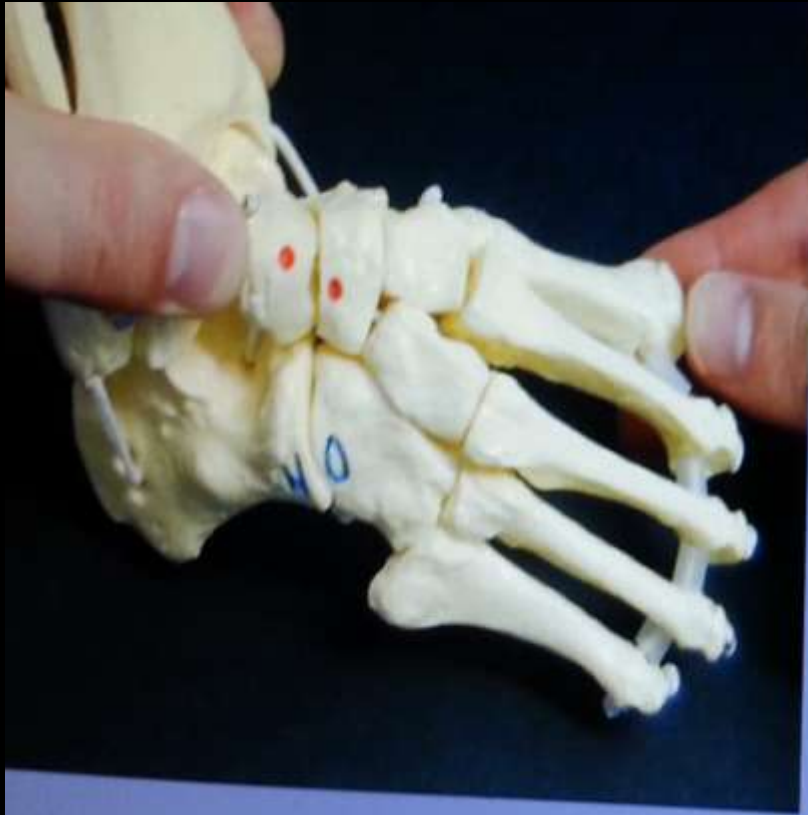Wedge  
shaped  
navicular

Wedge shaped  
head of talus

Wedge shaped distal  
calcaneal articular surface.

Medially displaced cuboid

You can stretch



# Syndromic TEV

- Spina bifida
- Sacral agenesis
- Fetal alcohol syndrome
- Congenital myopathy
- Downs syndrome
- Arthrogryposis lots of syndromes with this  
freeman Sheldon, Beals, Gordons etc

# Ponseti recurrence

- Engagement with treatment Education  
Education , Education if Educatable
- If they wont use boots and bars it will relapse  
The more severe ones will probably relapse  
anyway
- If the Peroneals don't develop quickly it will  
relapse

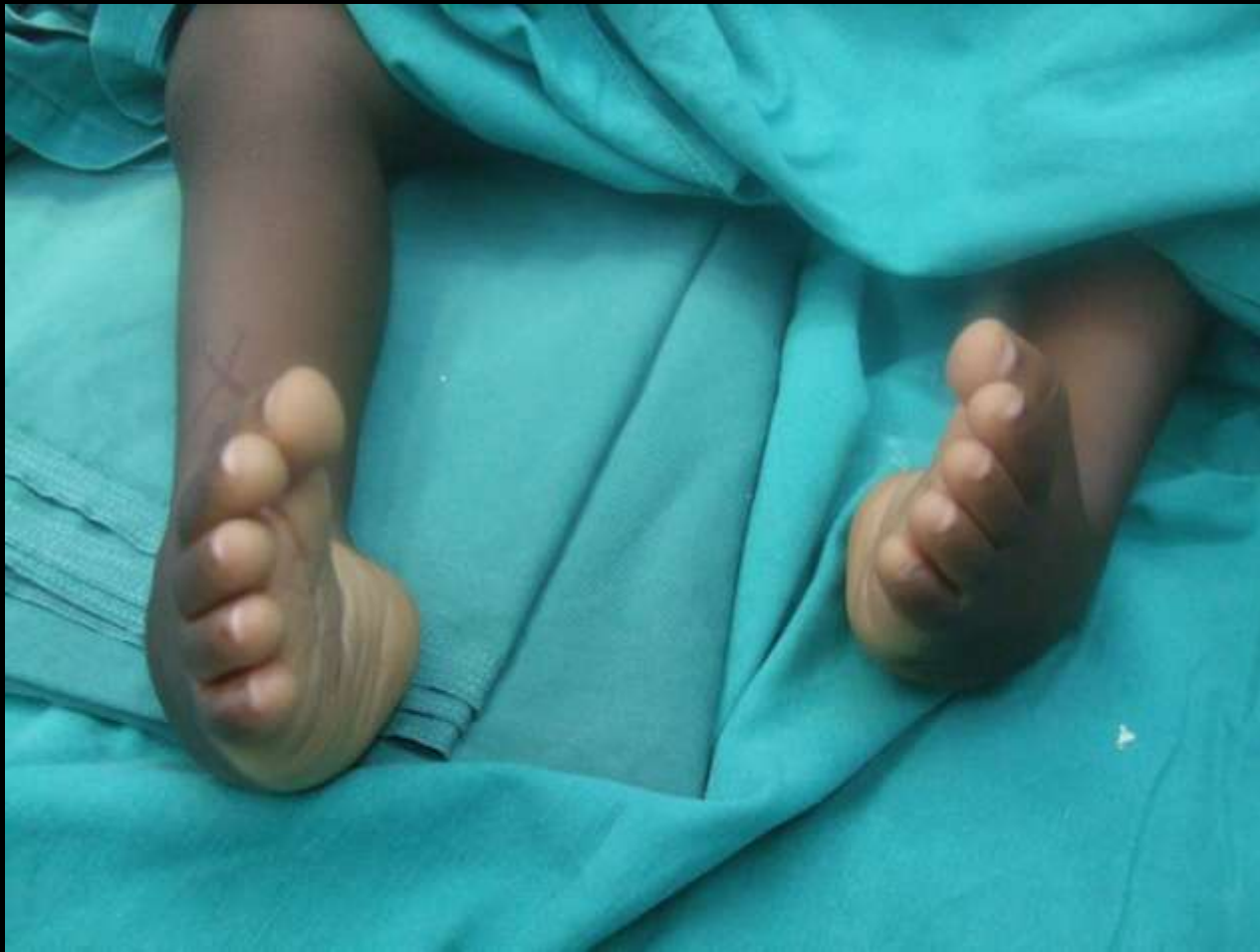# Tibialis anterior tendon transfer

- Age over 3. I do it after 4
- Dynamic supination of foot with severe intoeing
- Move the whole tib ant and put it into a decancellised cuboid
- Non weight bearing cast for 6 to 8 weeks.

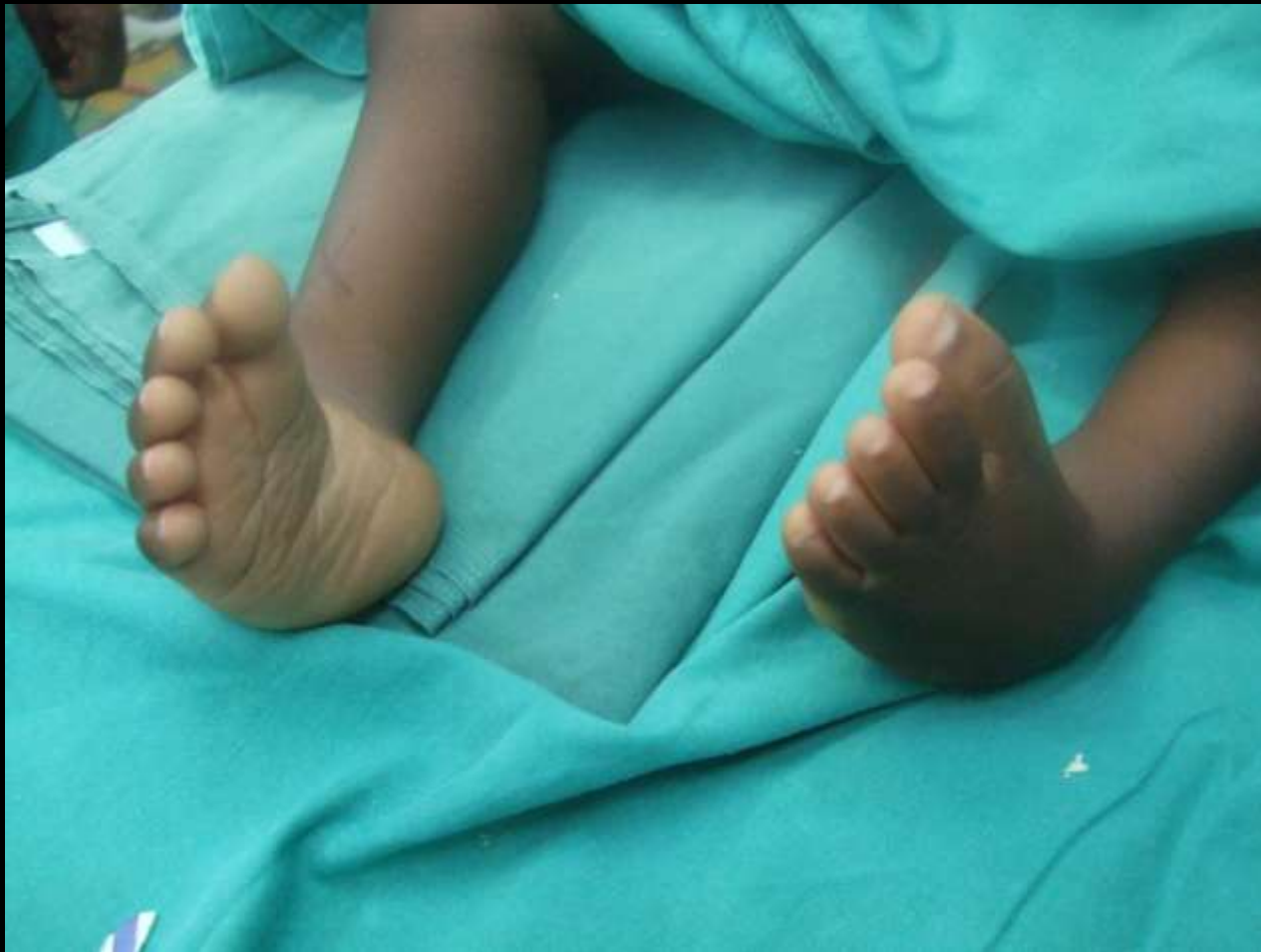# Older children

- Will definitely need surgery but do ponseti first to get as much correction as you can.
- Then will need various osteotomies and fusions as required.
- Principles are plantigrade painless and shoeable foot.
- Wreck as few joints as possible. They've still got the rest of their lives ahead of them

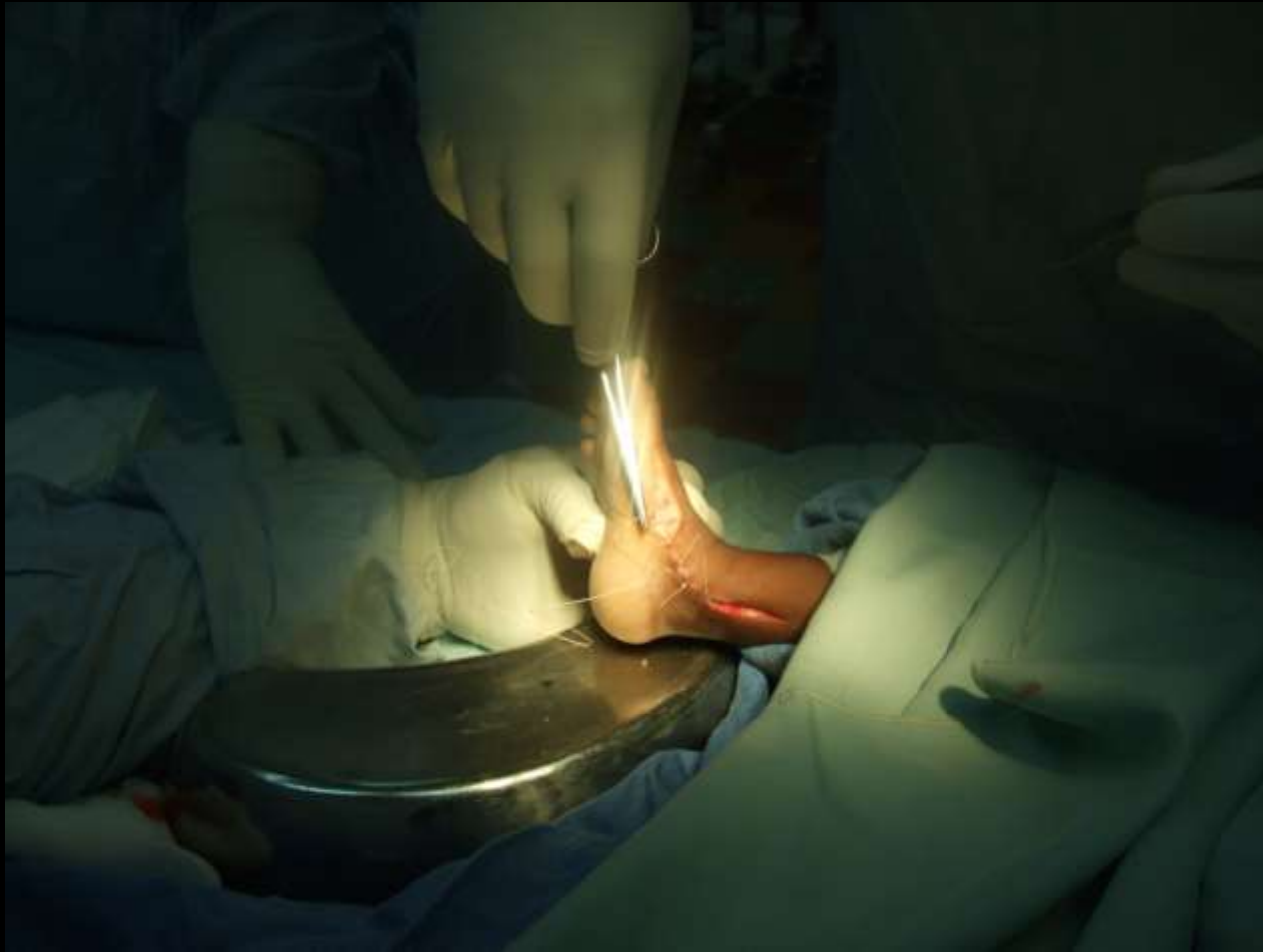Clapping feet not happy feet....yet



These are not the worst



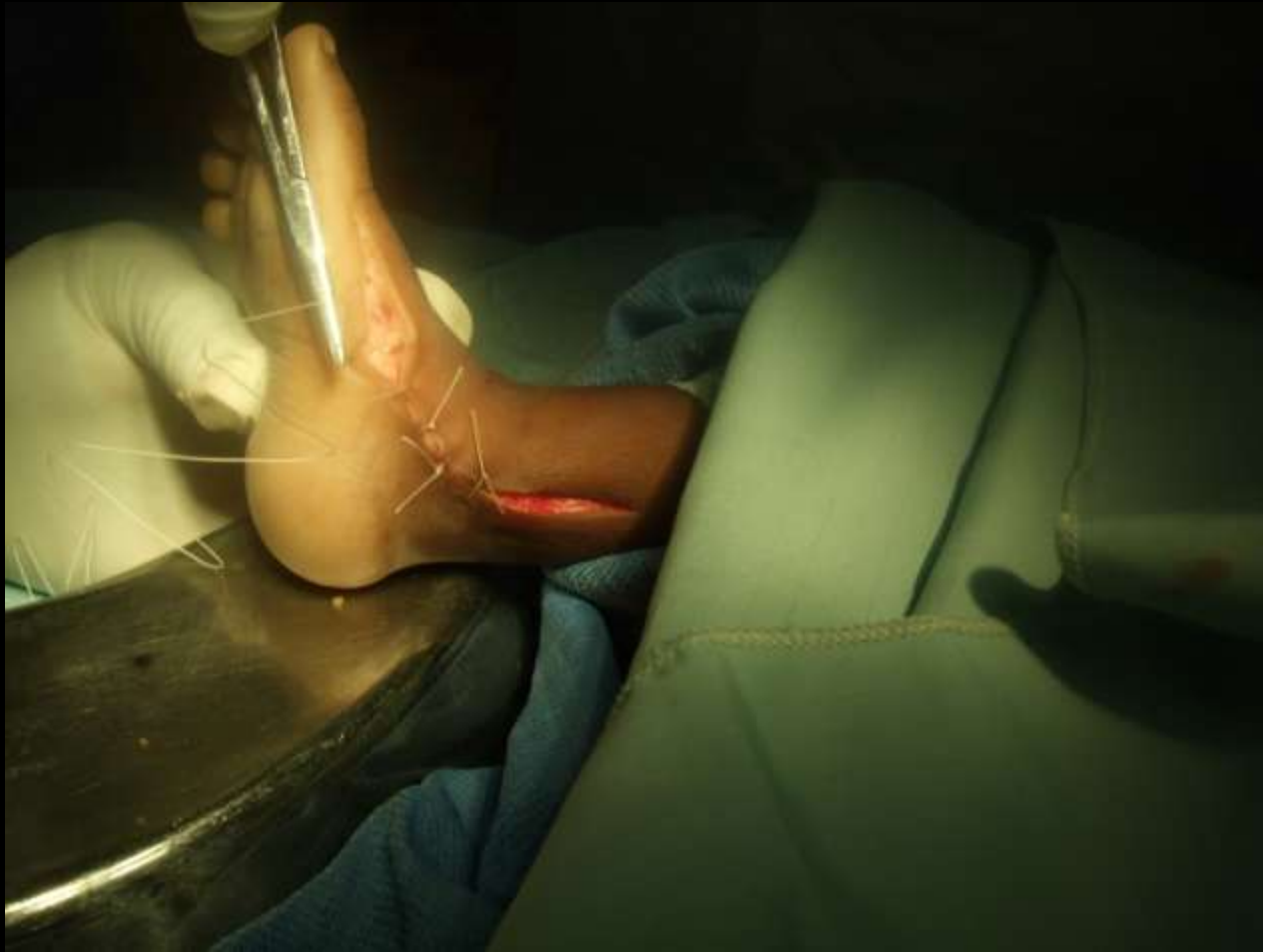# Single stage correction



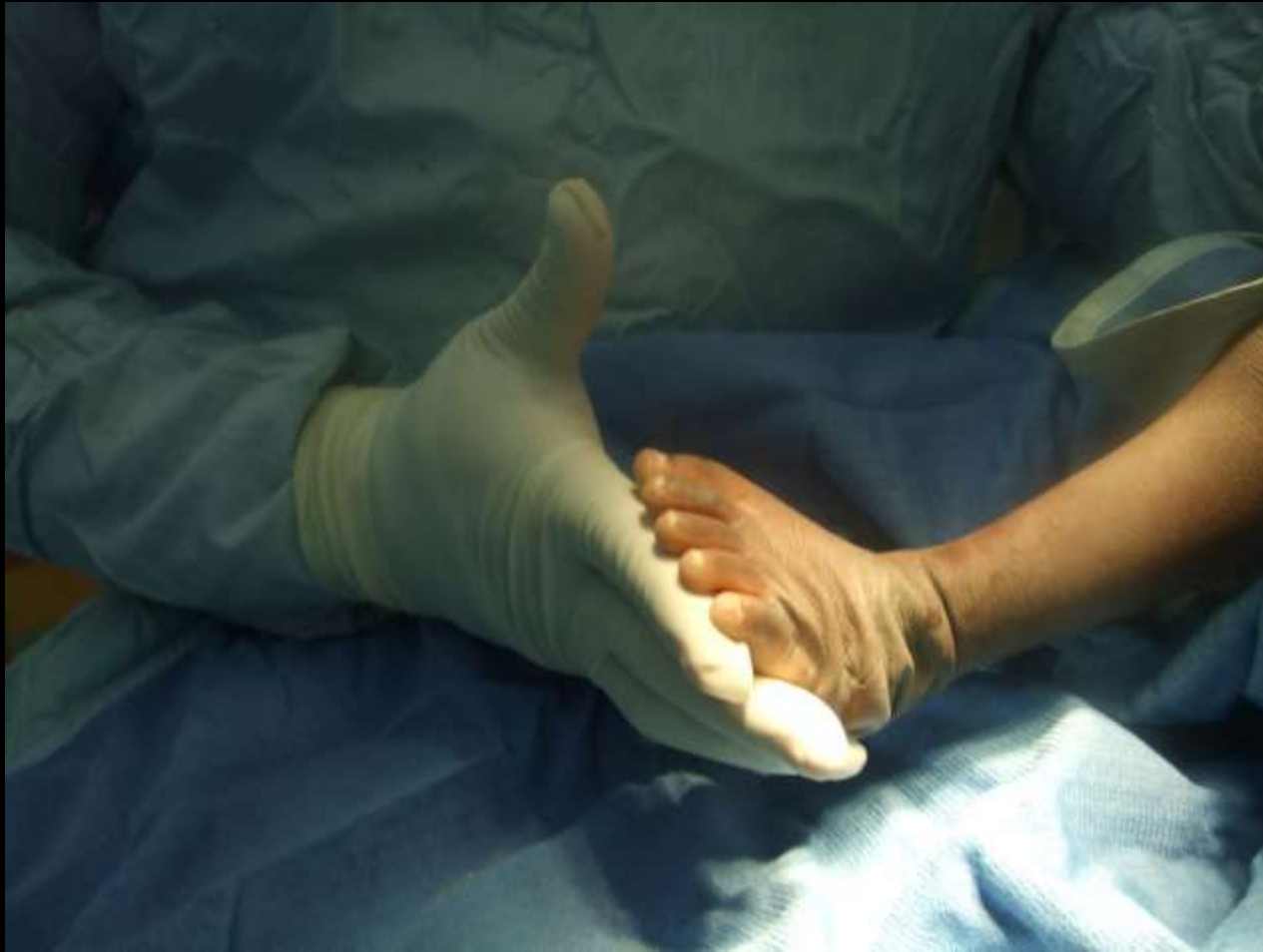# Principles

- Get a plantigrade foot
- Damage as few joints as possible
- Don't cut off the foot.
- Tendons
- Joint capsules
- Ligaments
- Excisions e.g Astragalectomy for syndromic ones

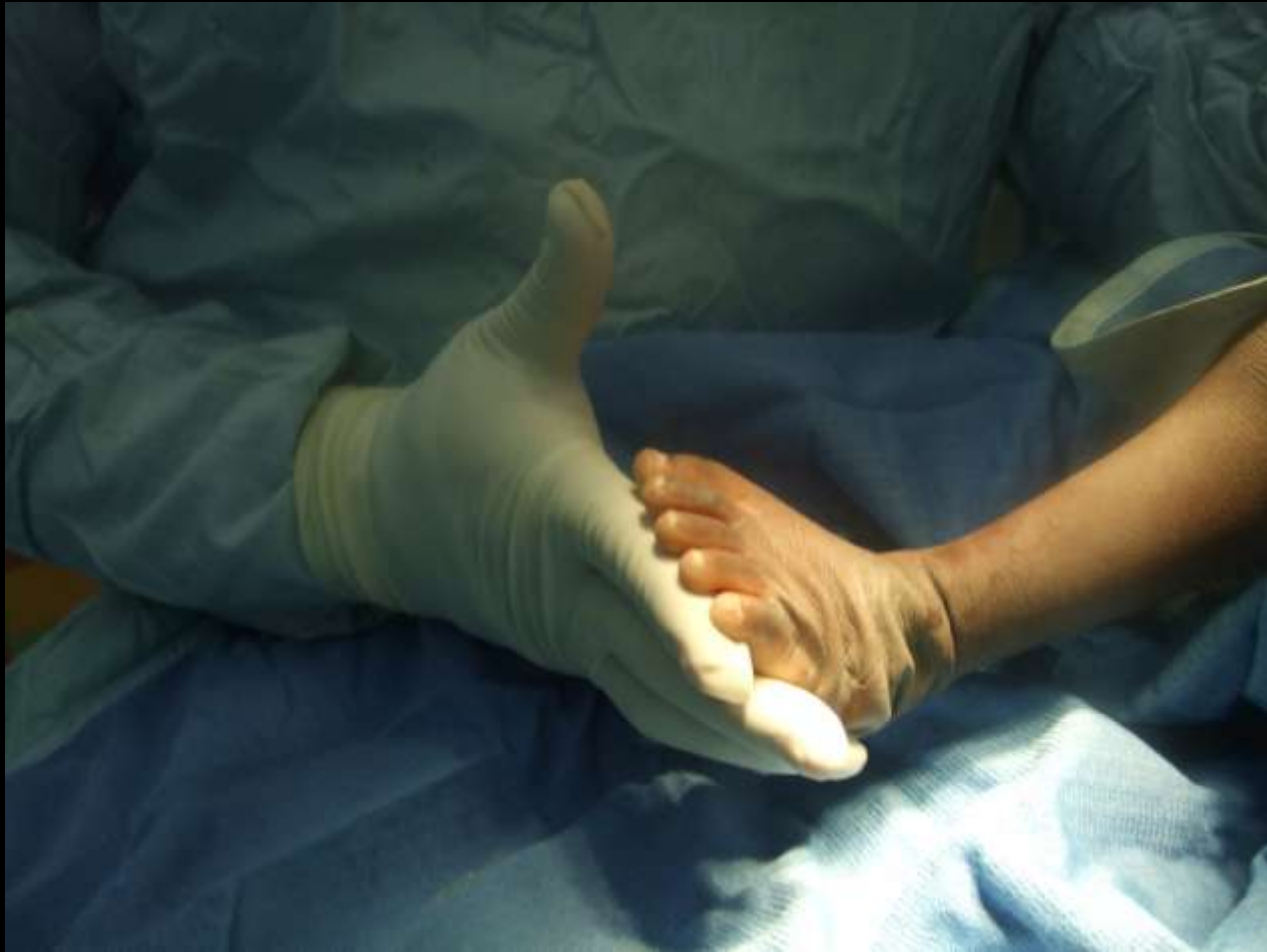# Happiness



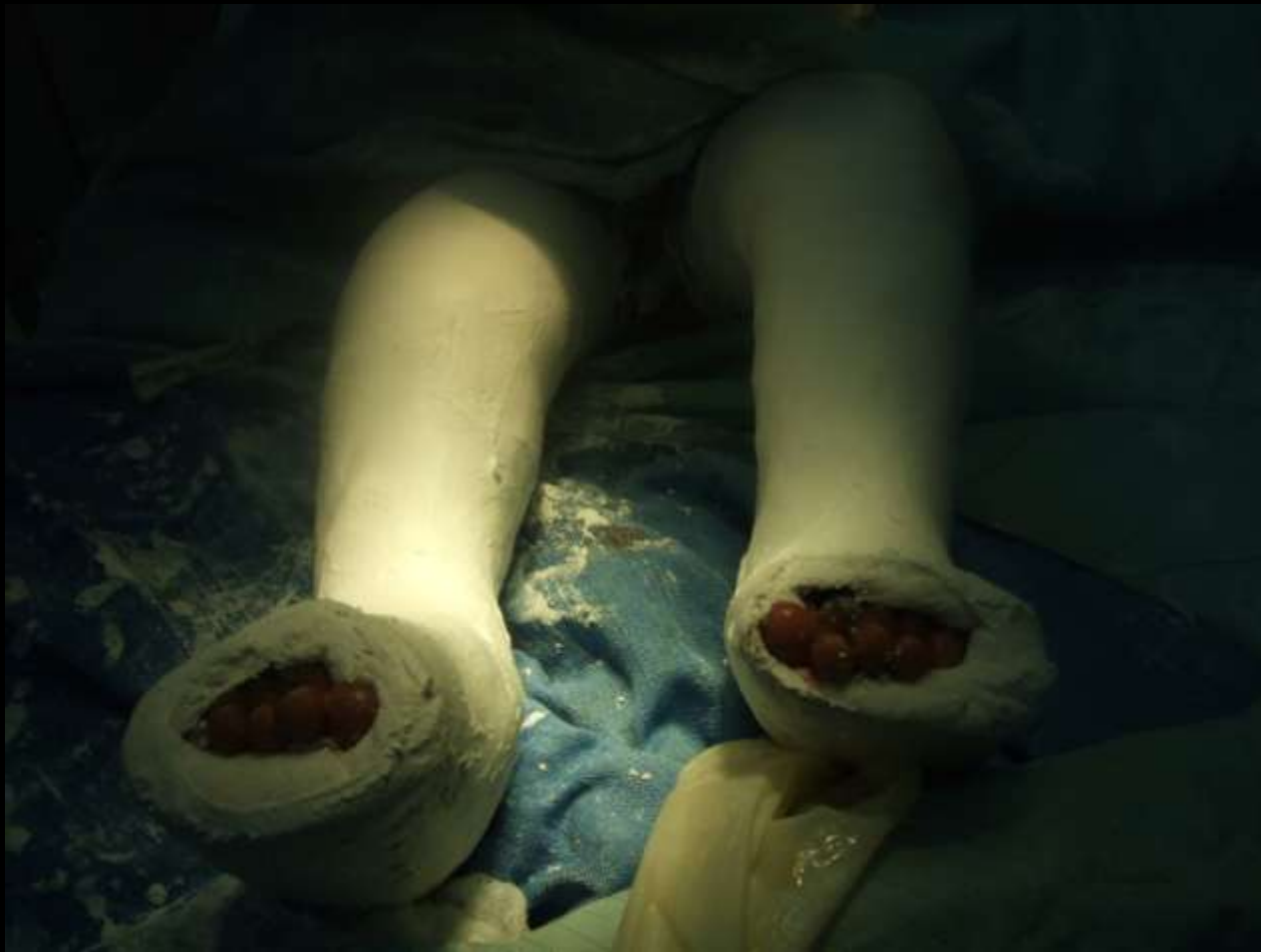If it looks right.....



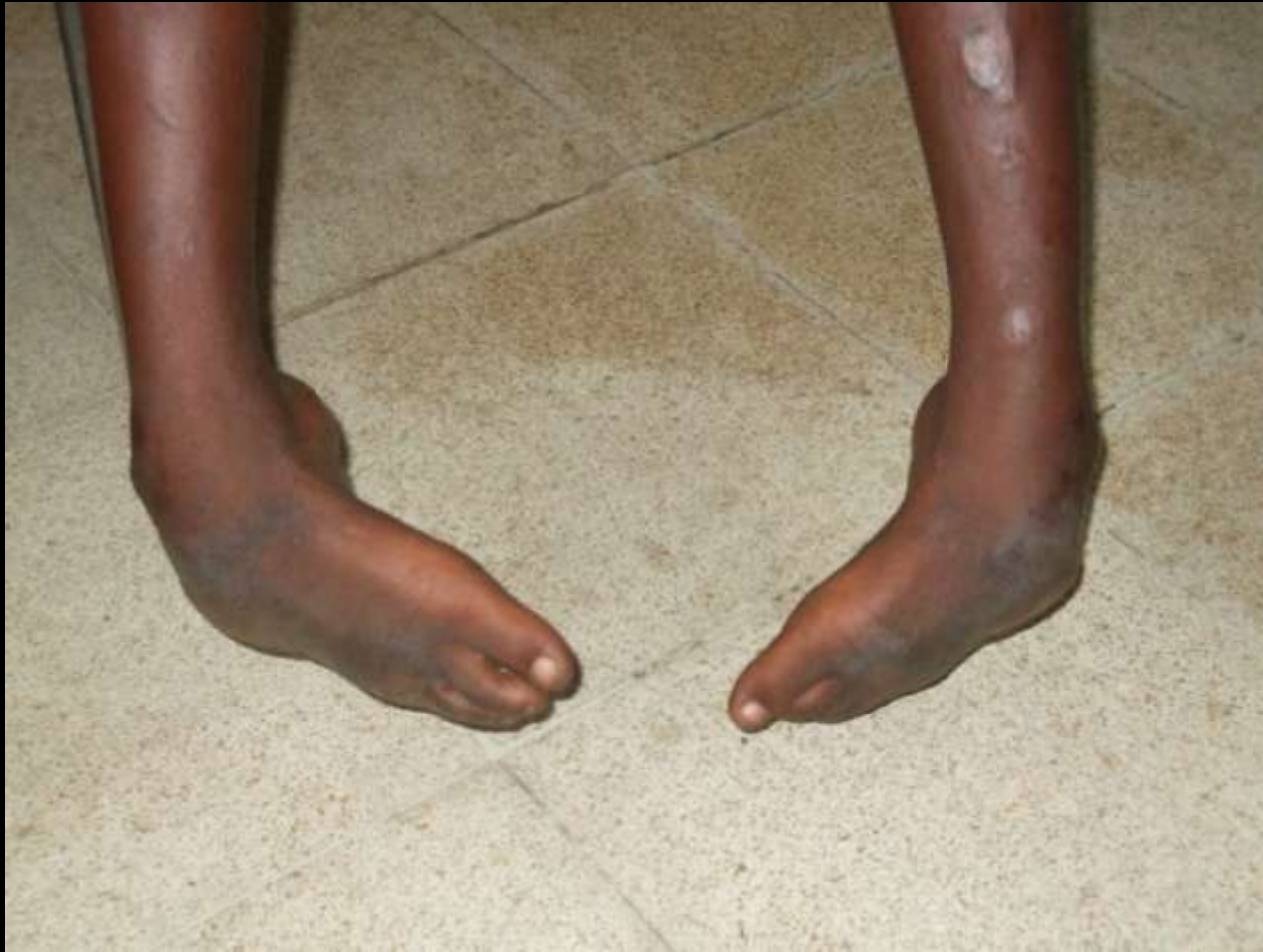All done

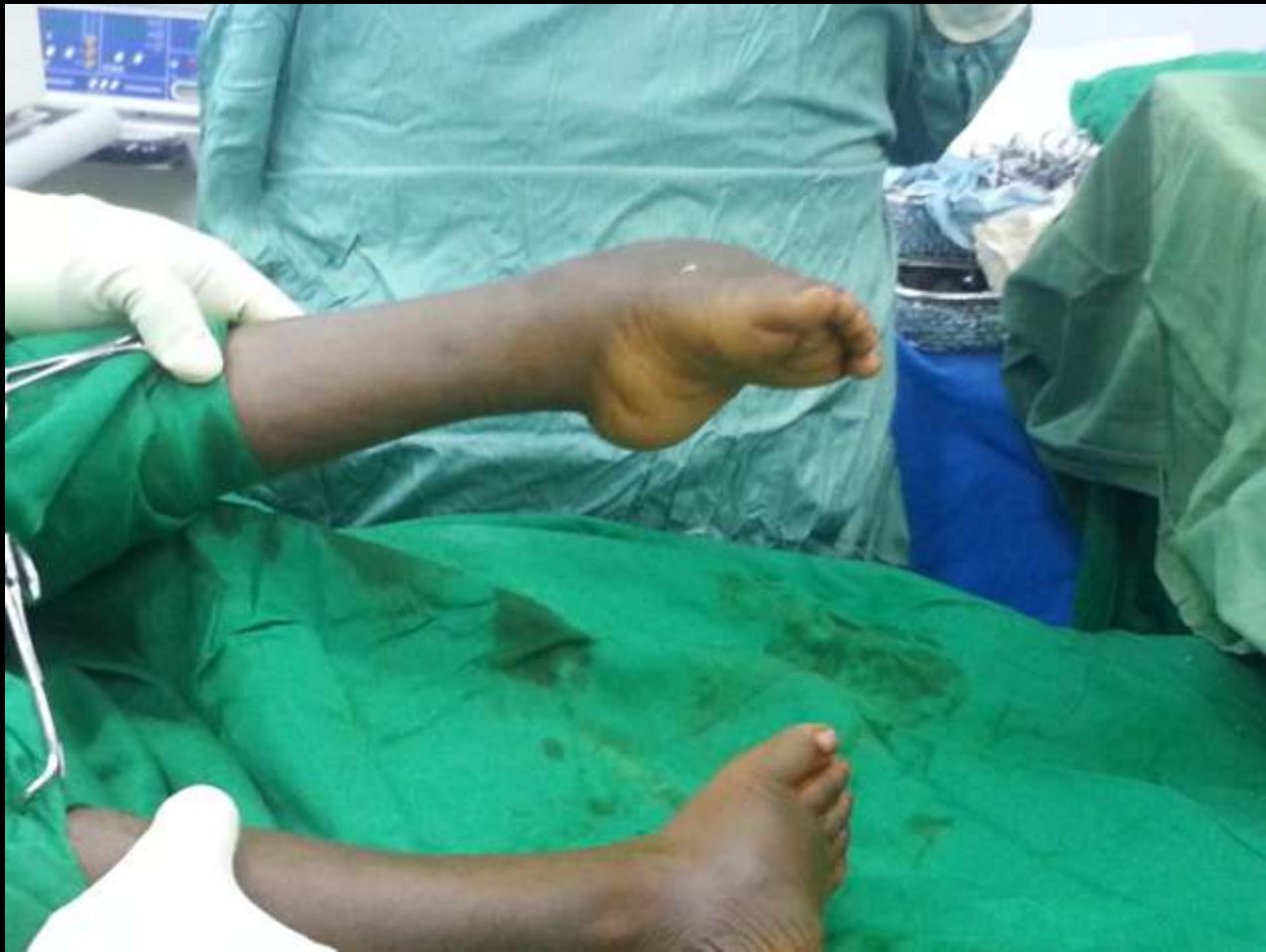

Dont forget the plaster

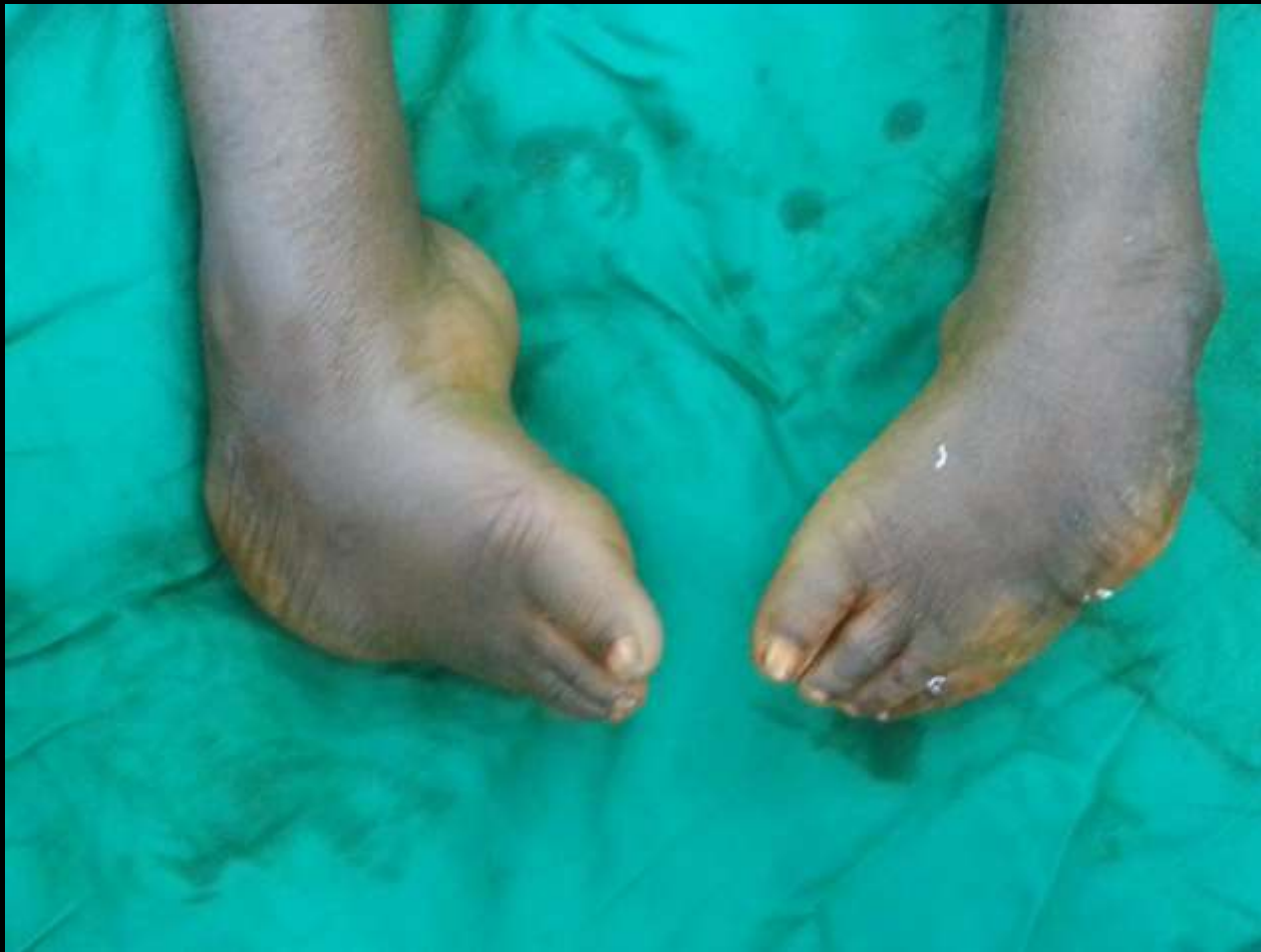

Now what?

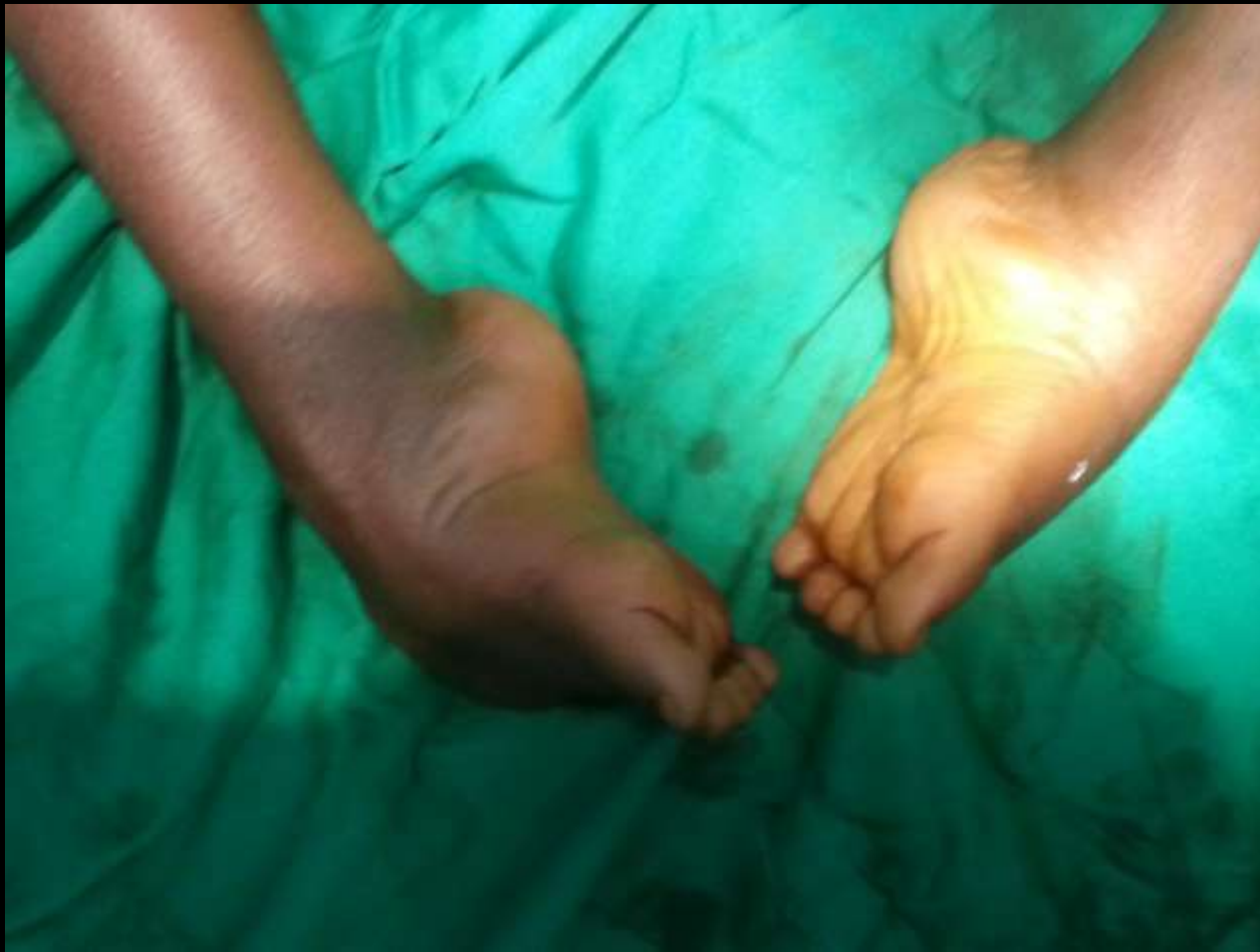


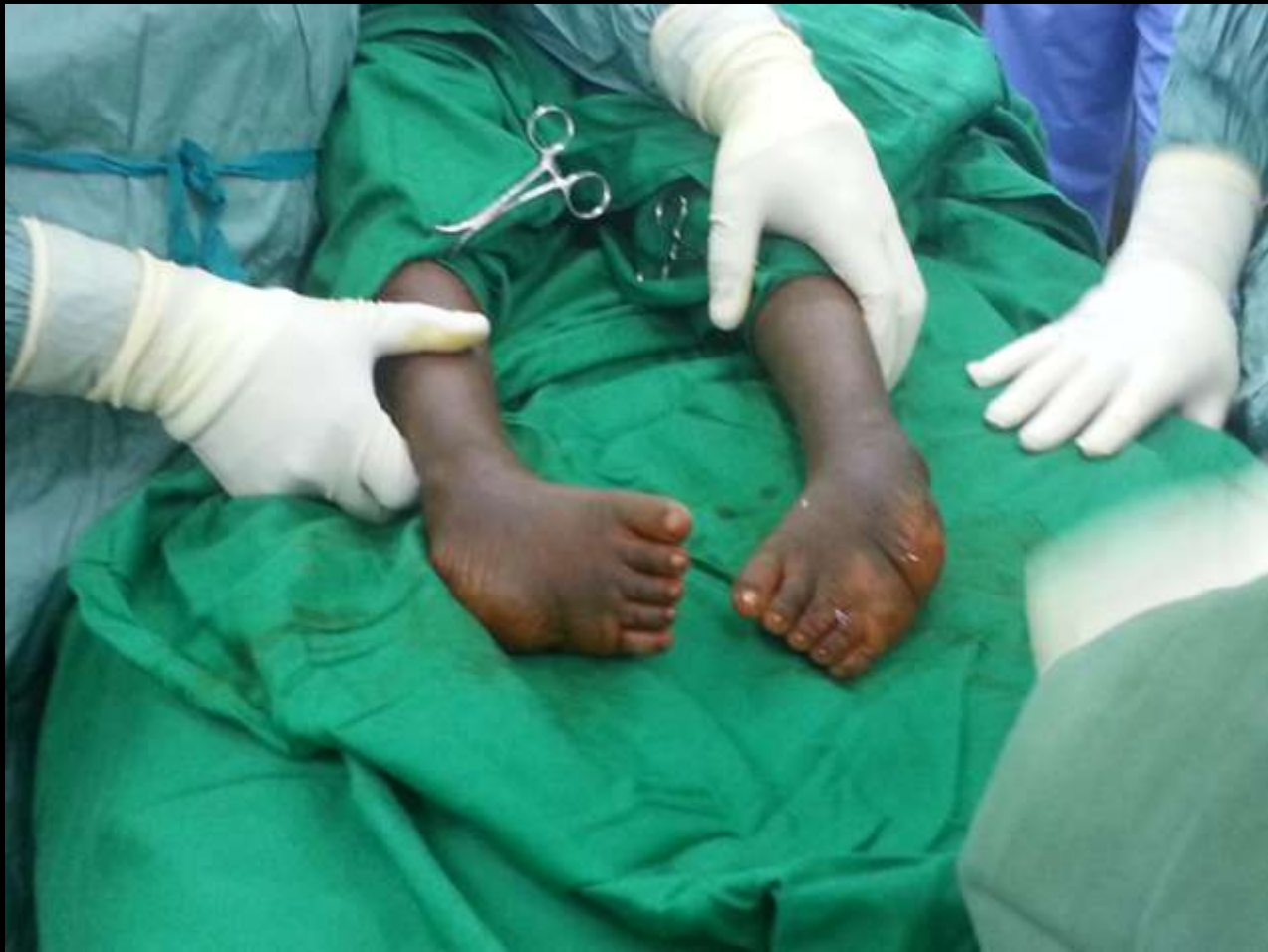
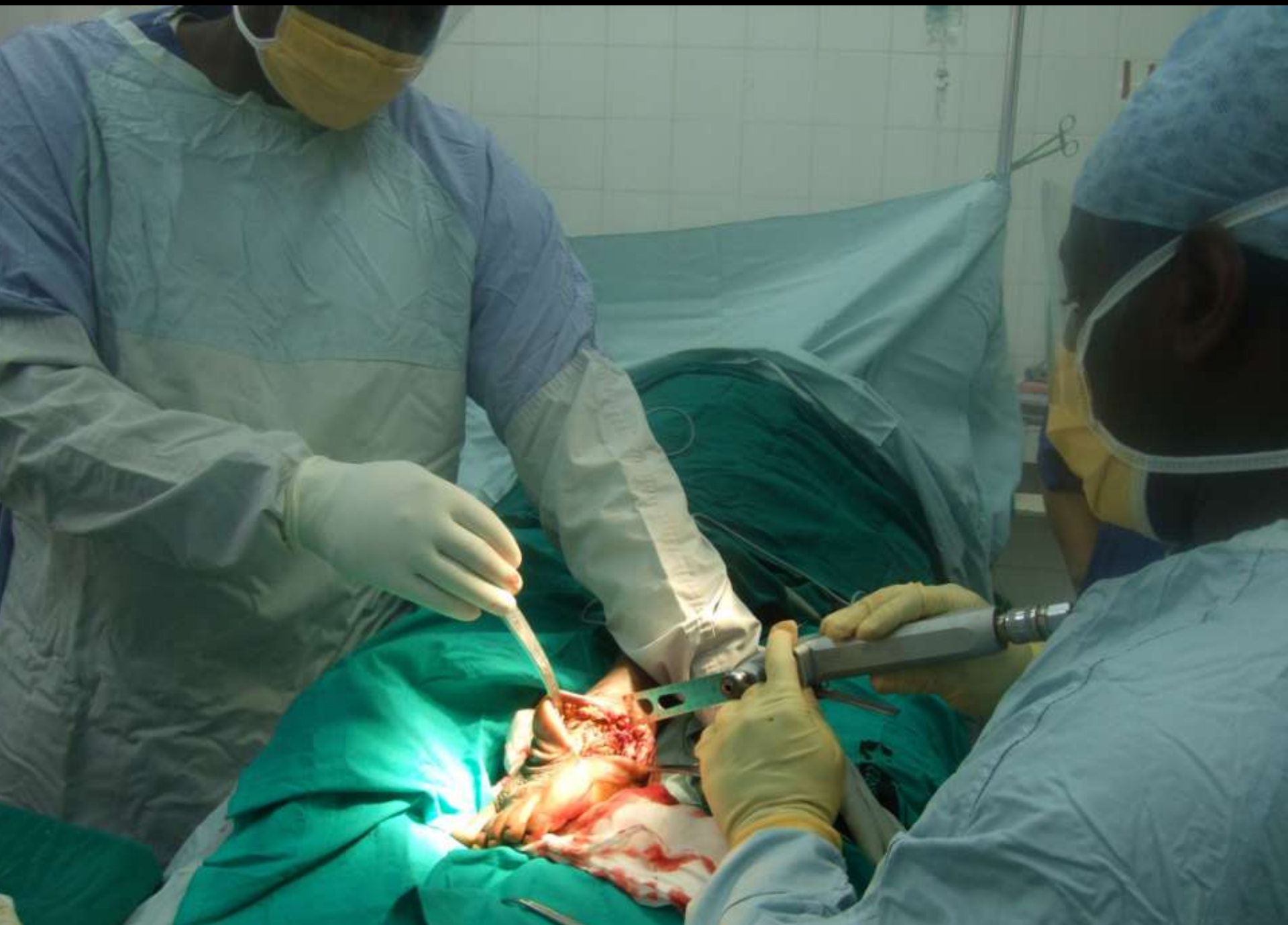This needs something else



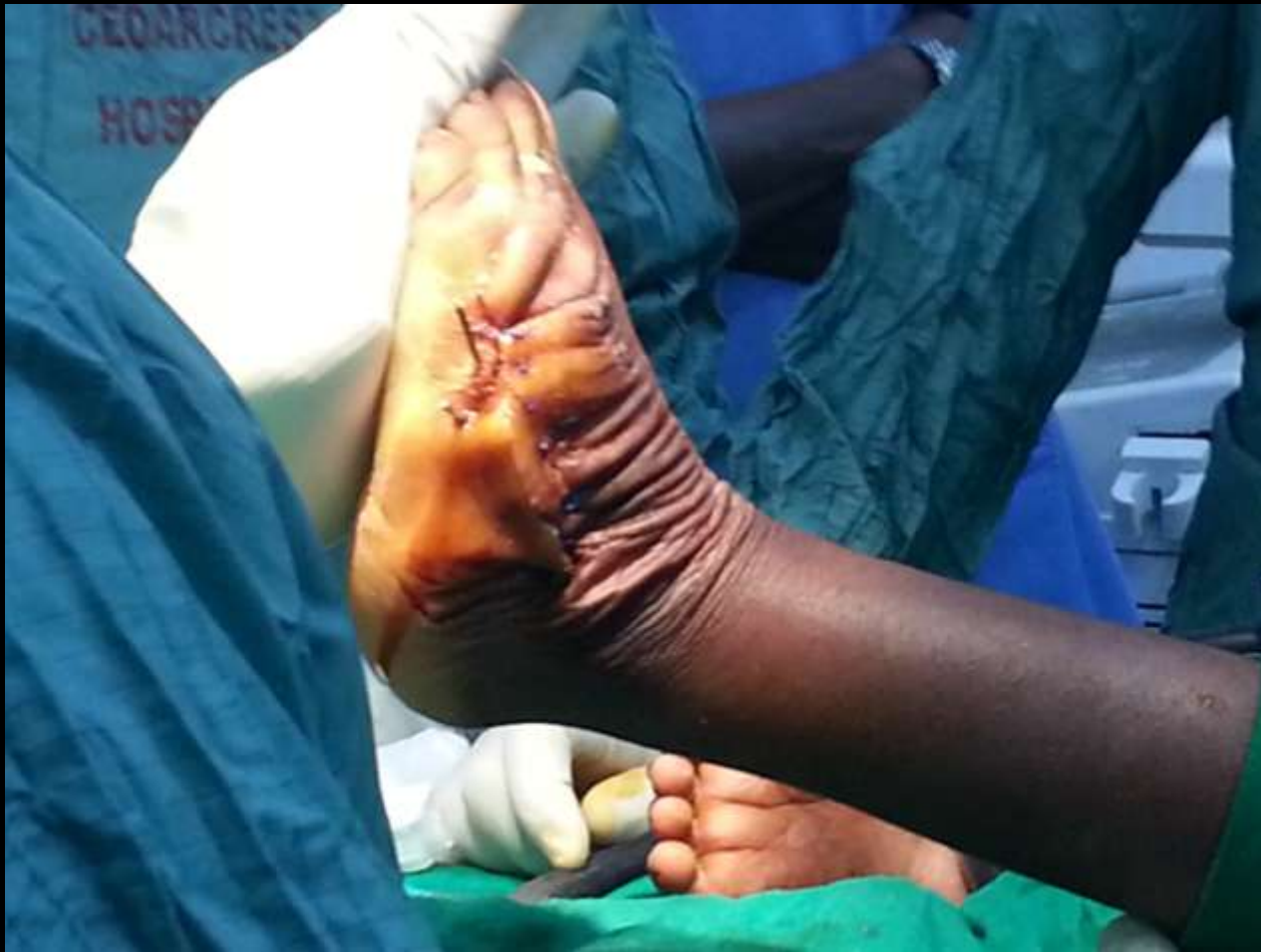# A Corrective extended a lacarte triple fusion

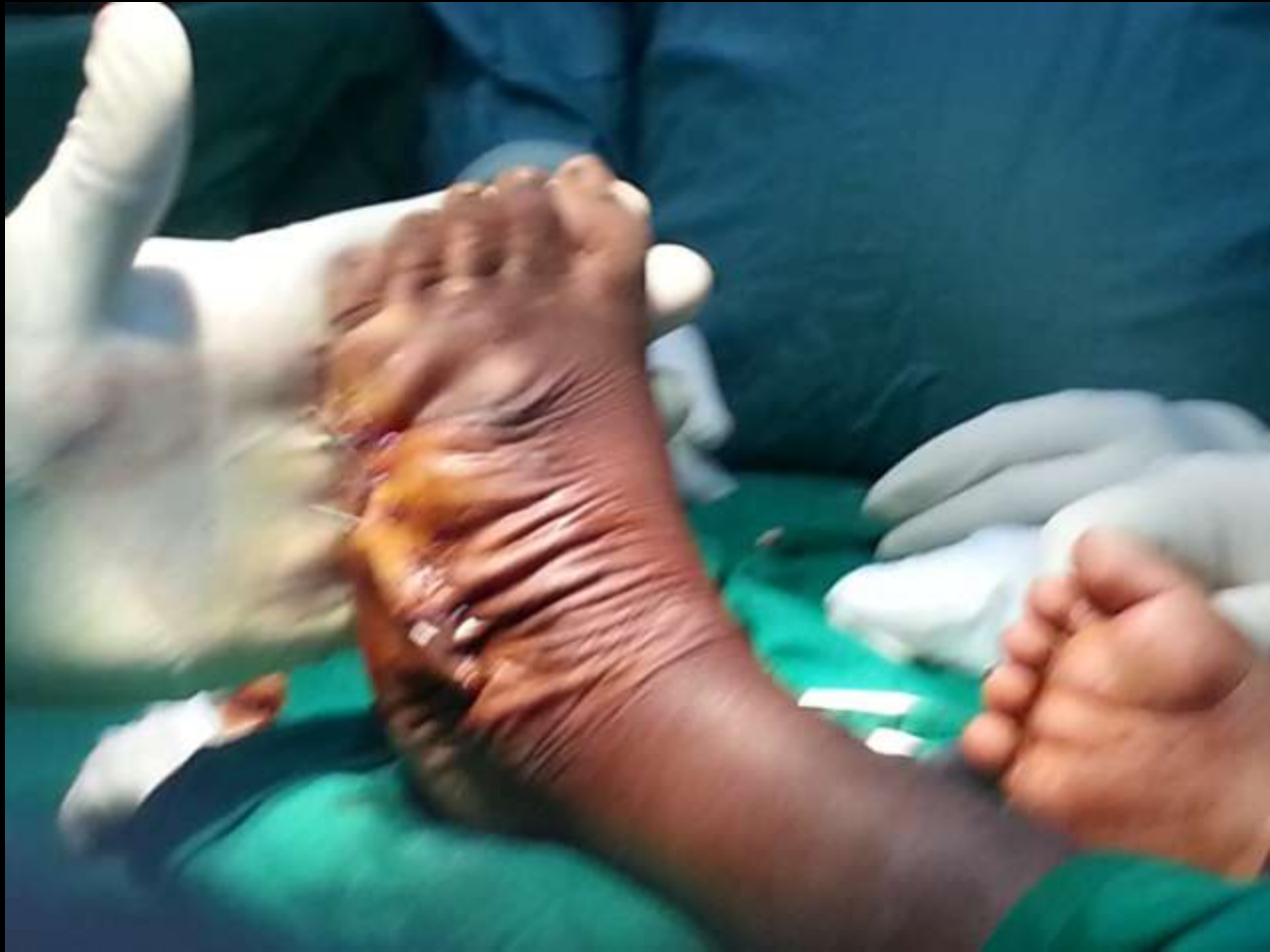


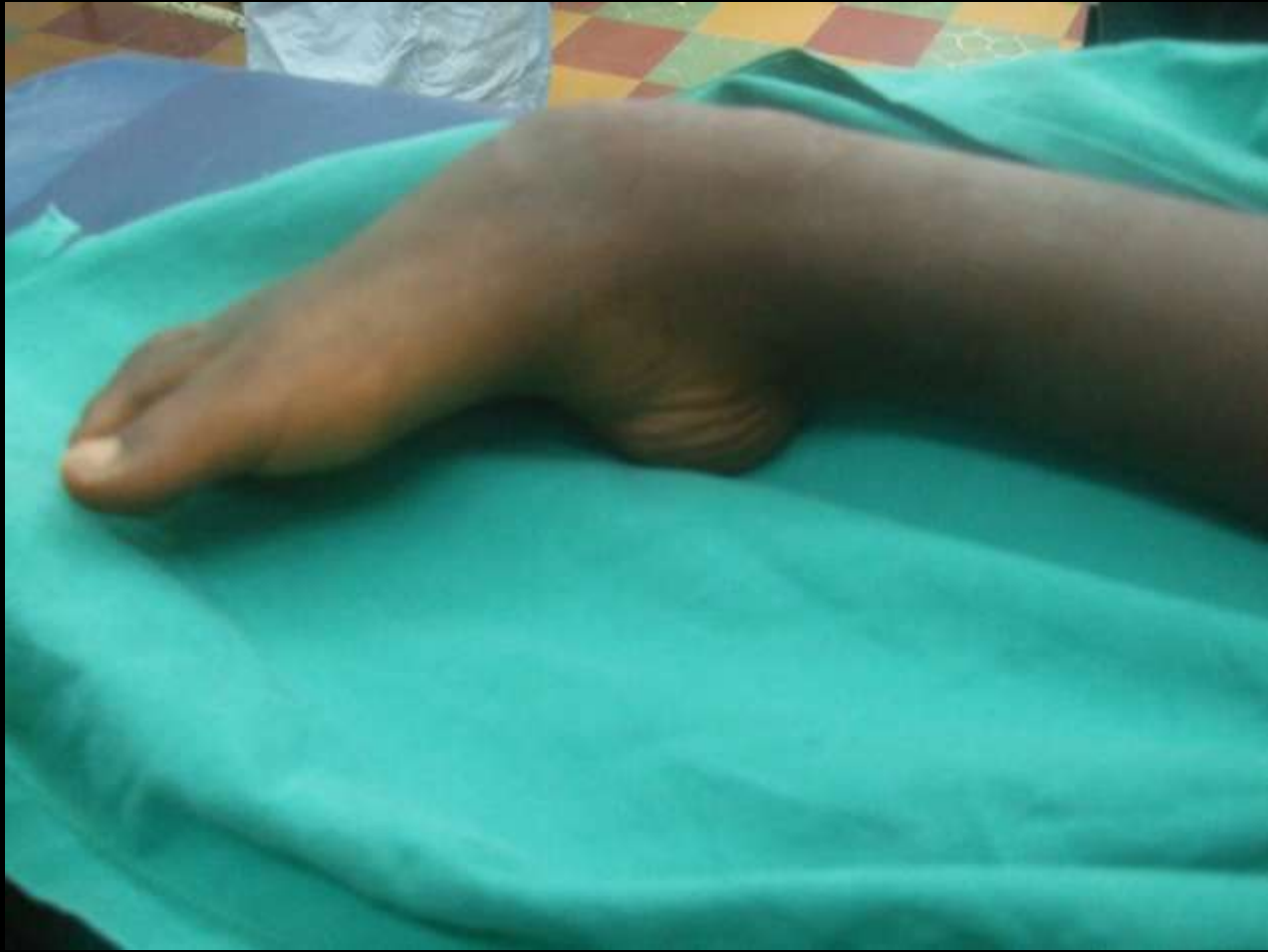


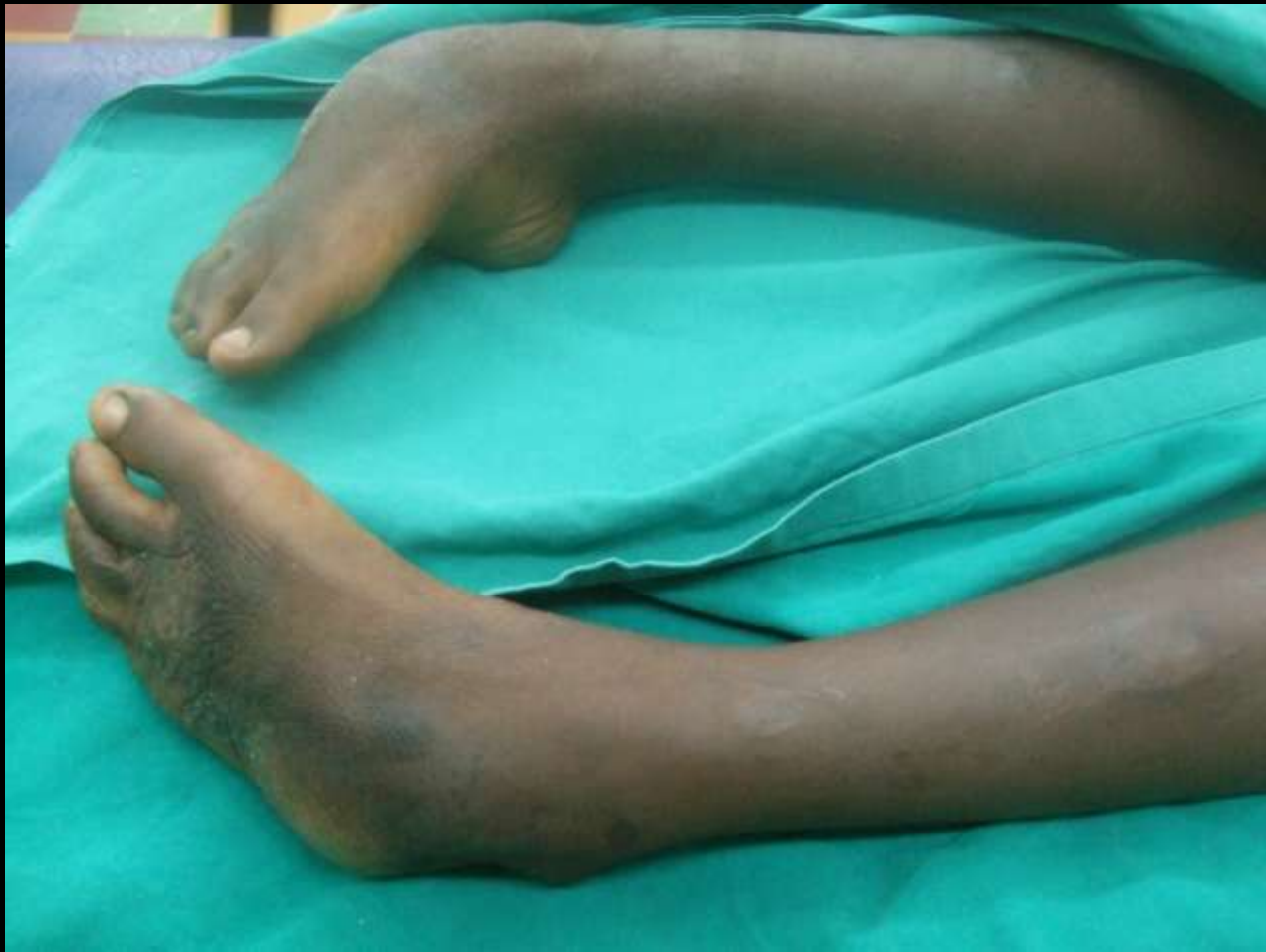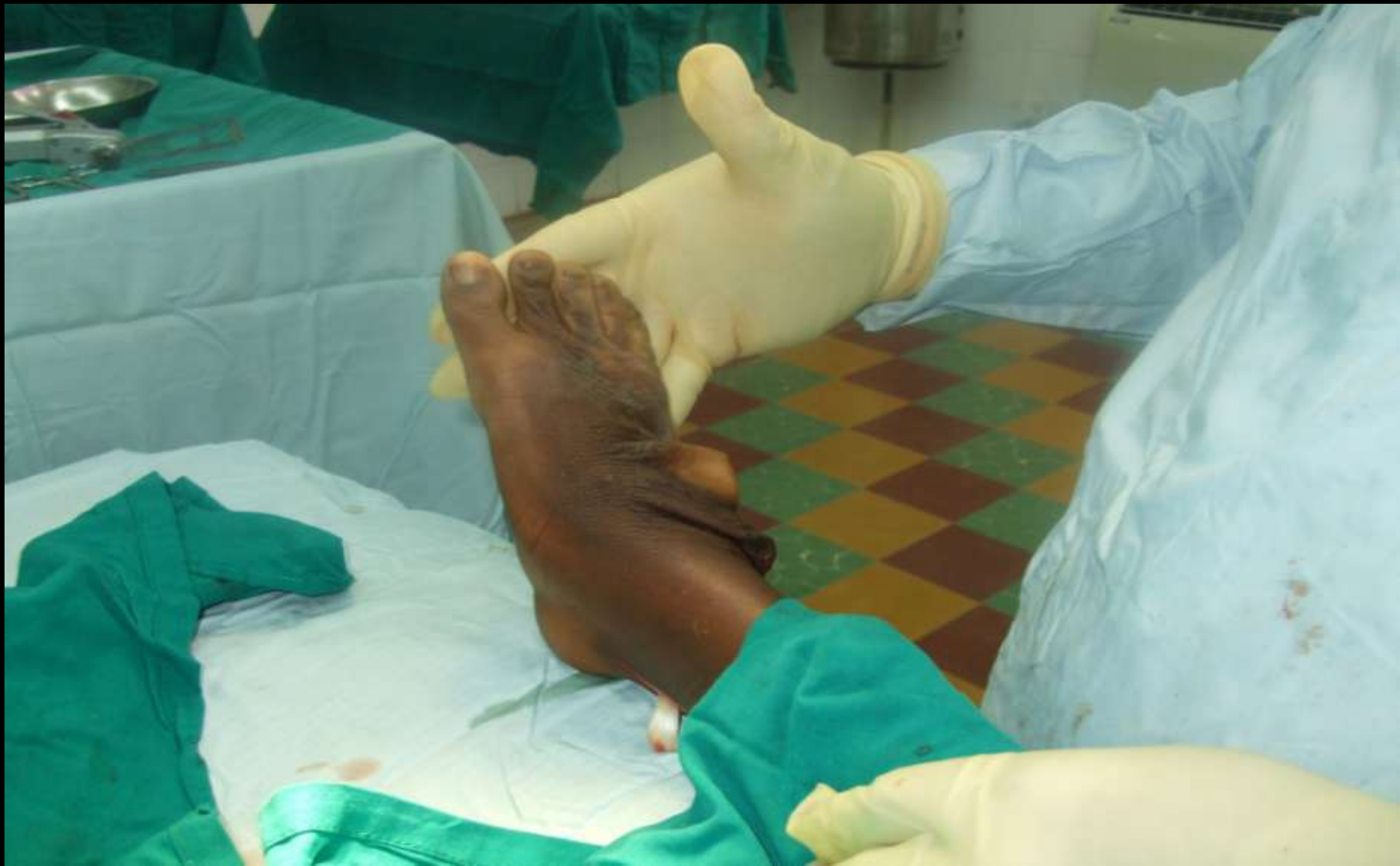# Held with Kwiwires

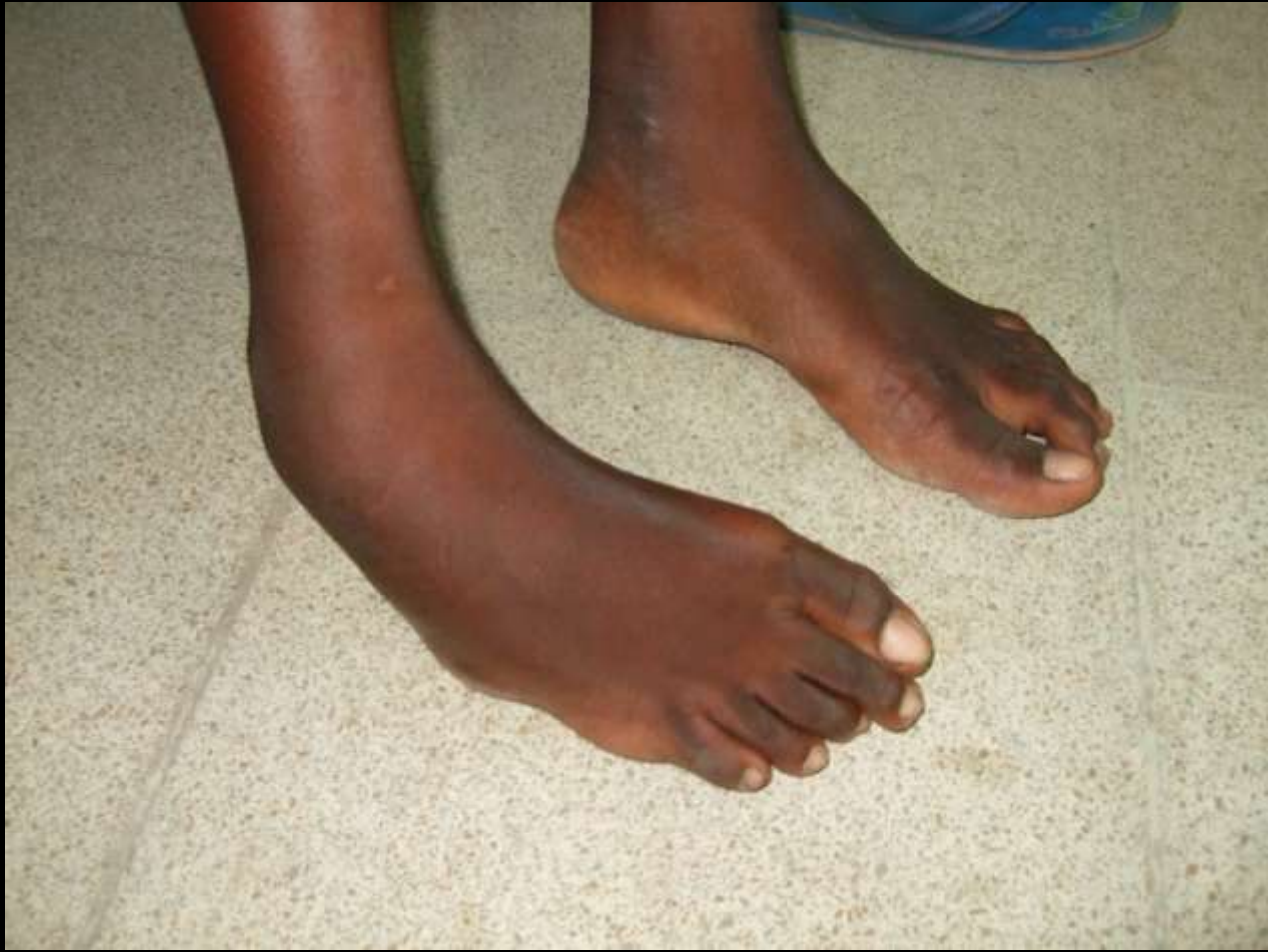




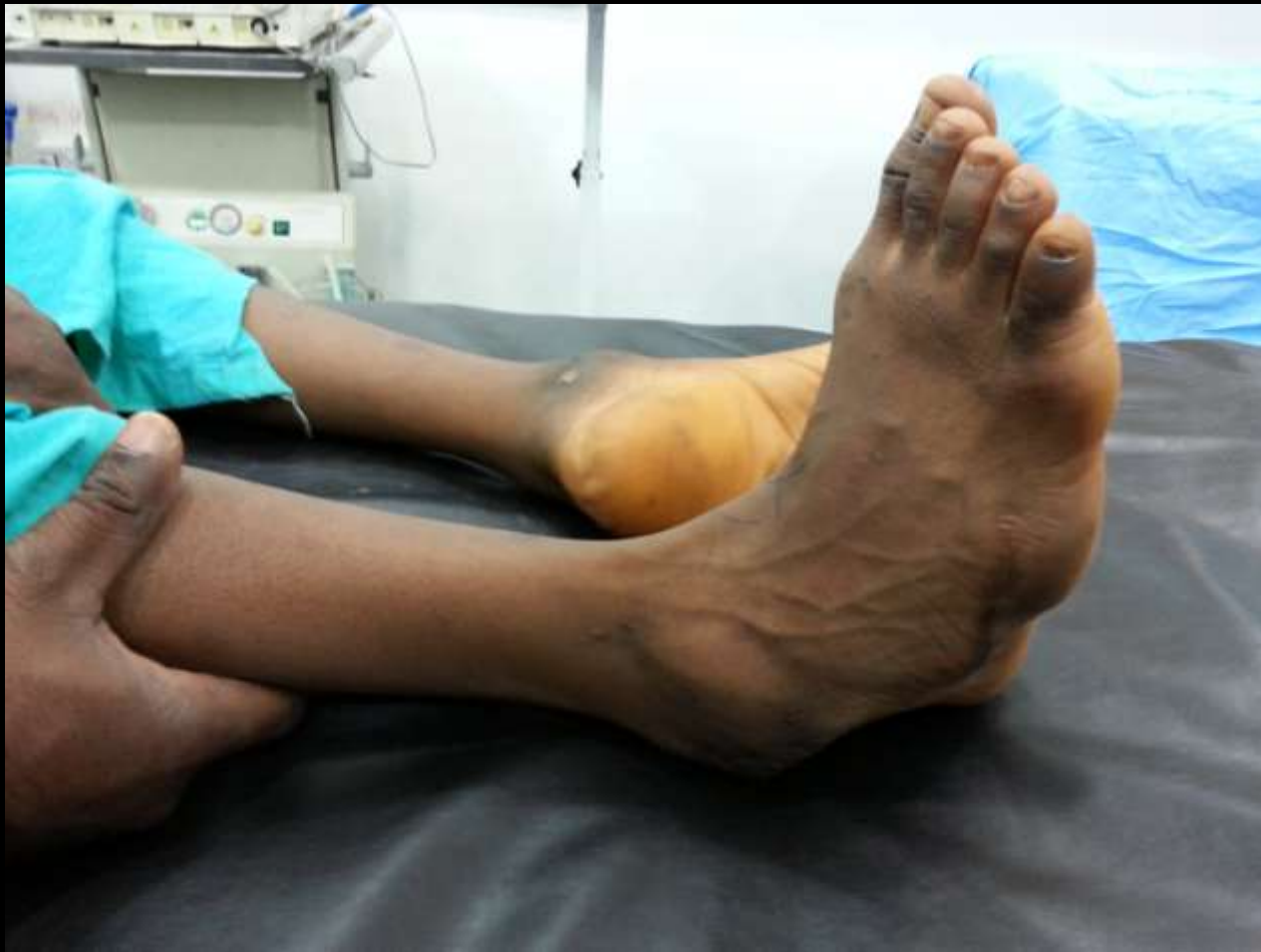






Not every clubfoot is a clubfoot



Thank you