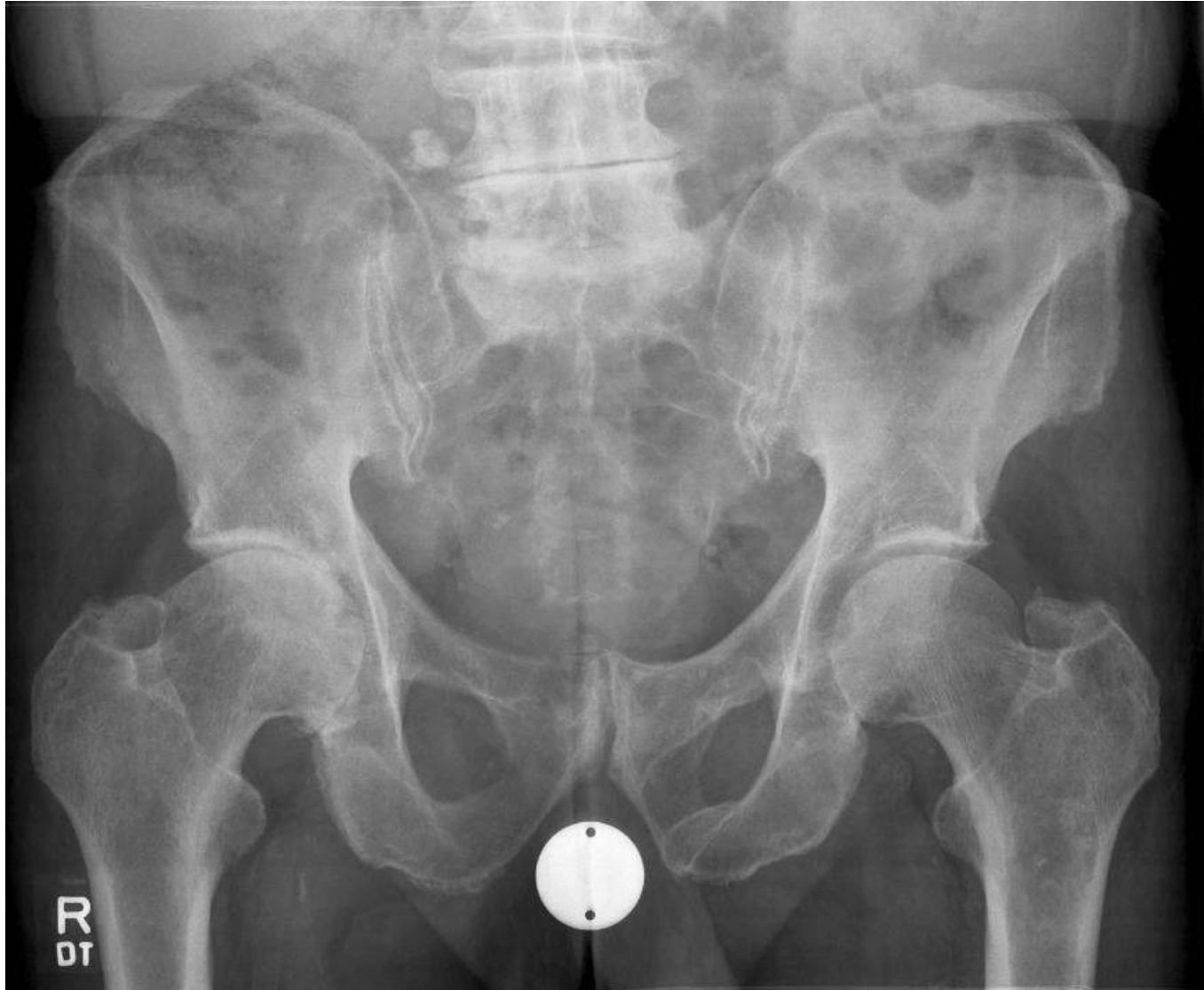


Dislocating hips

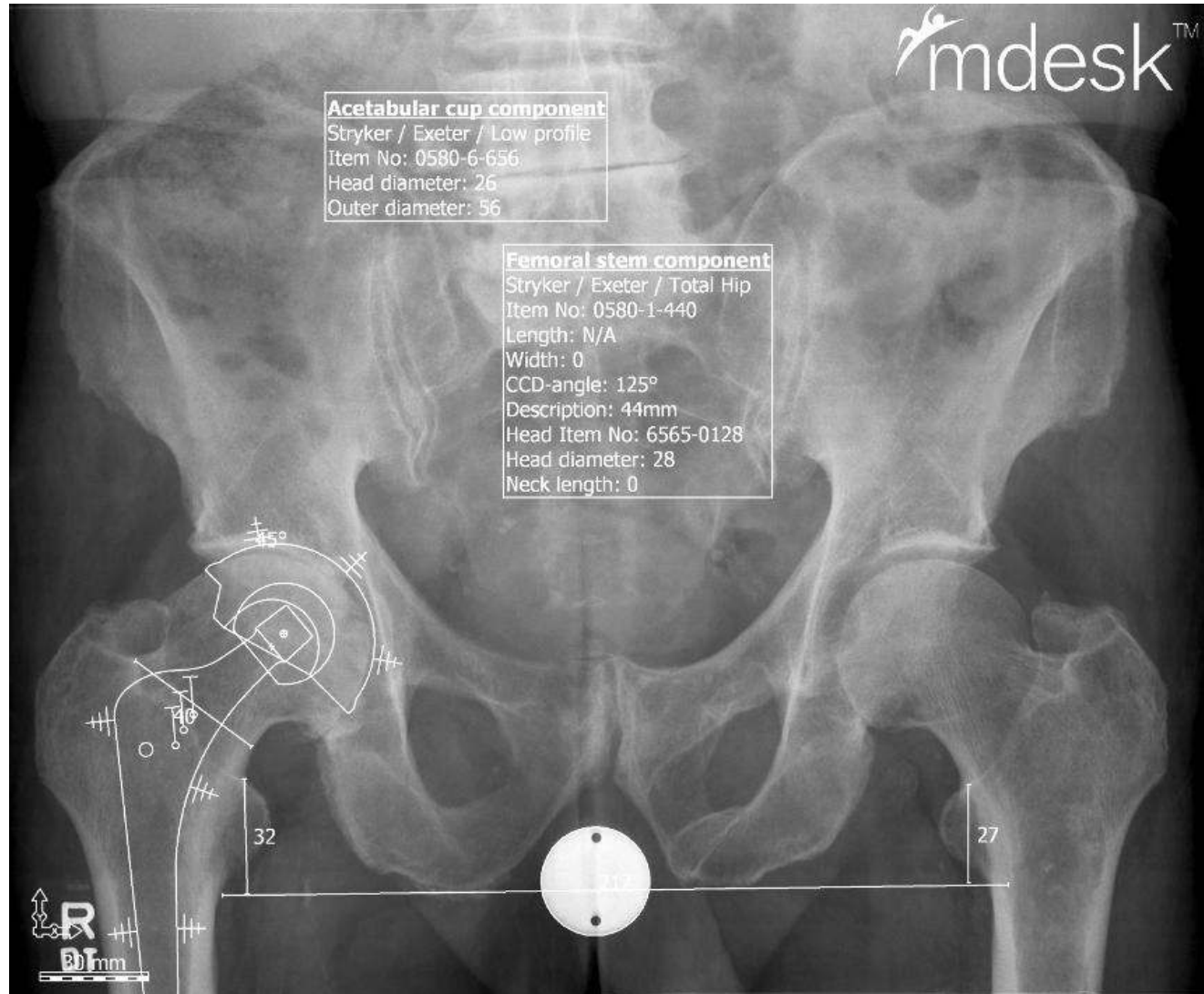
Ian Carluke

Wansbeck Hospital

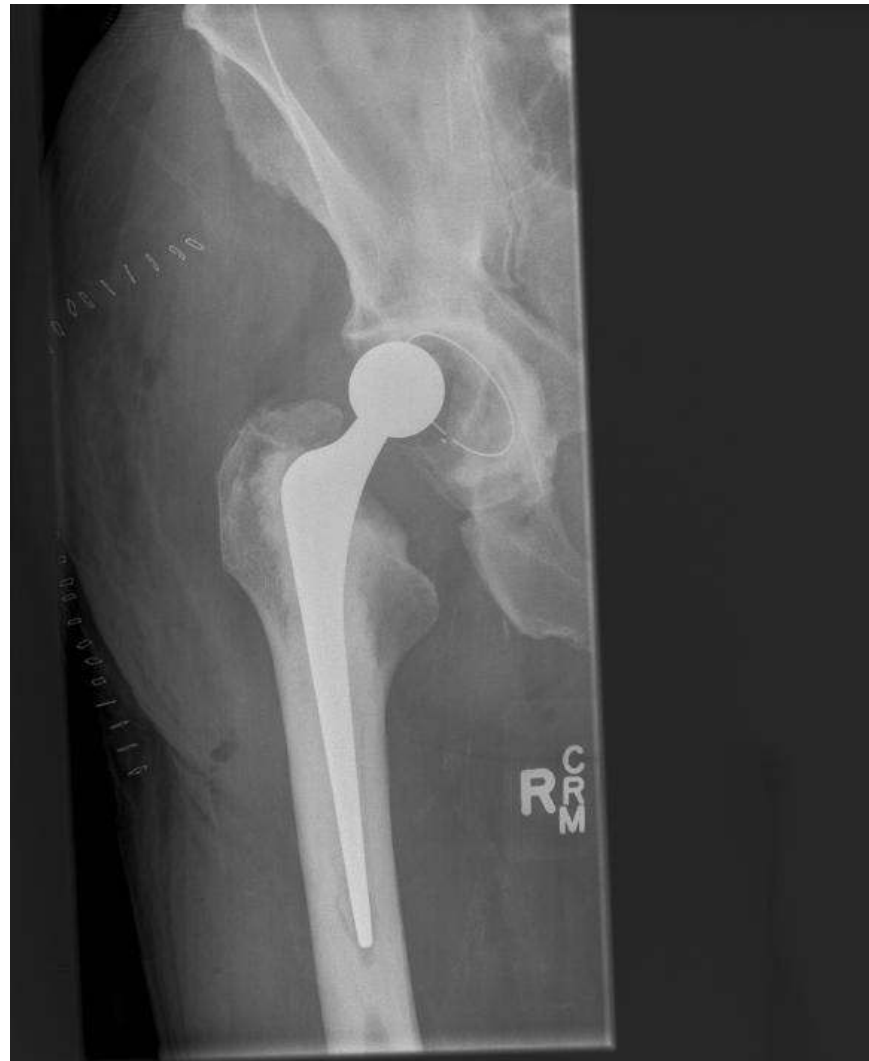Case 1 preop



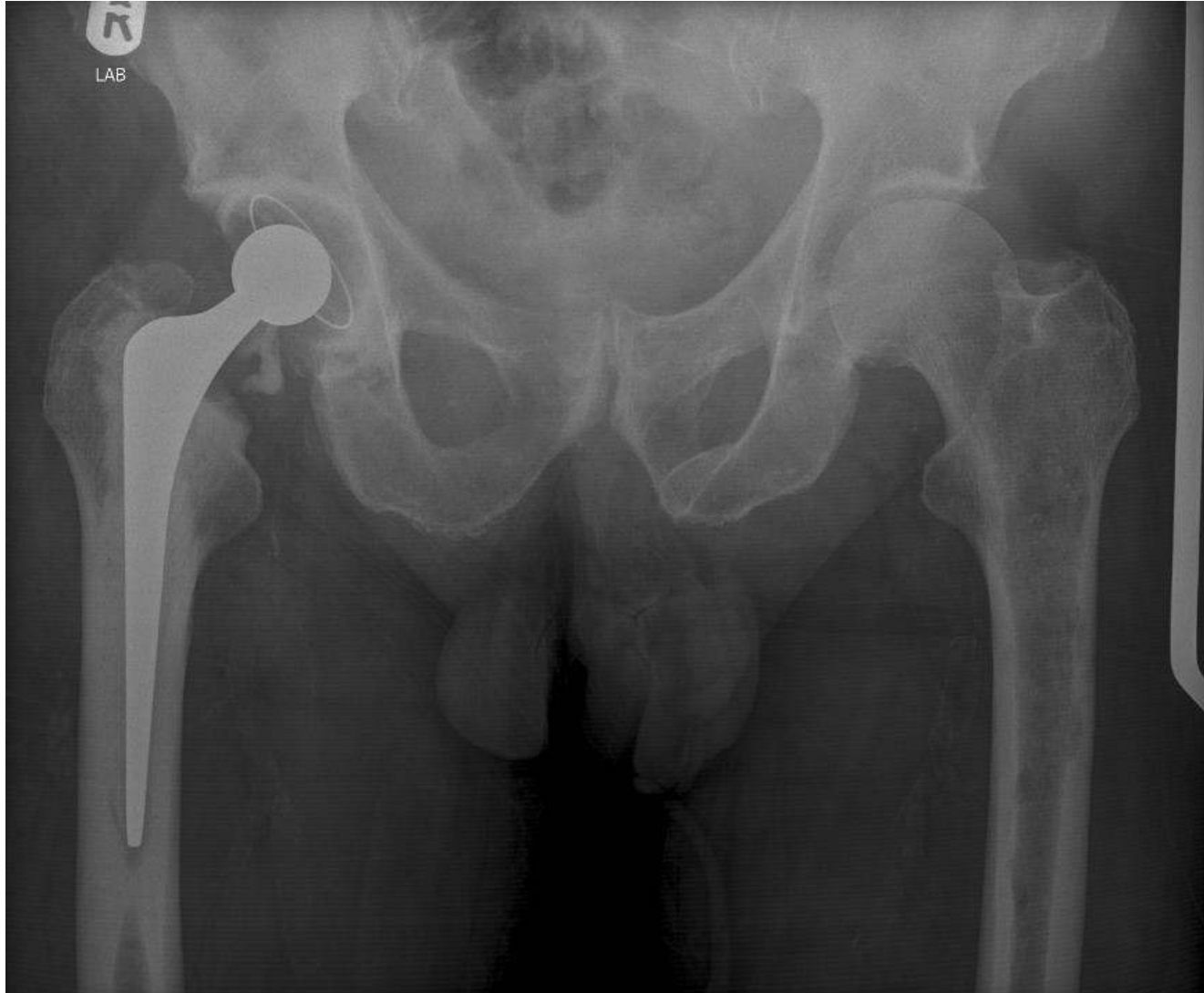Case 1 pre-op template



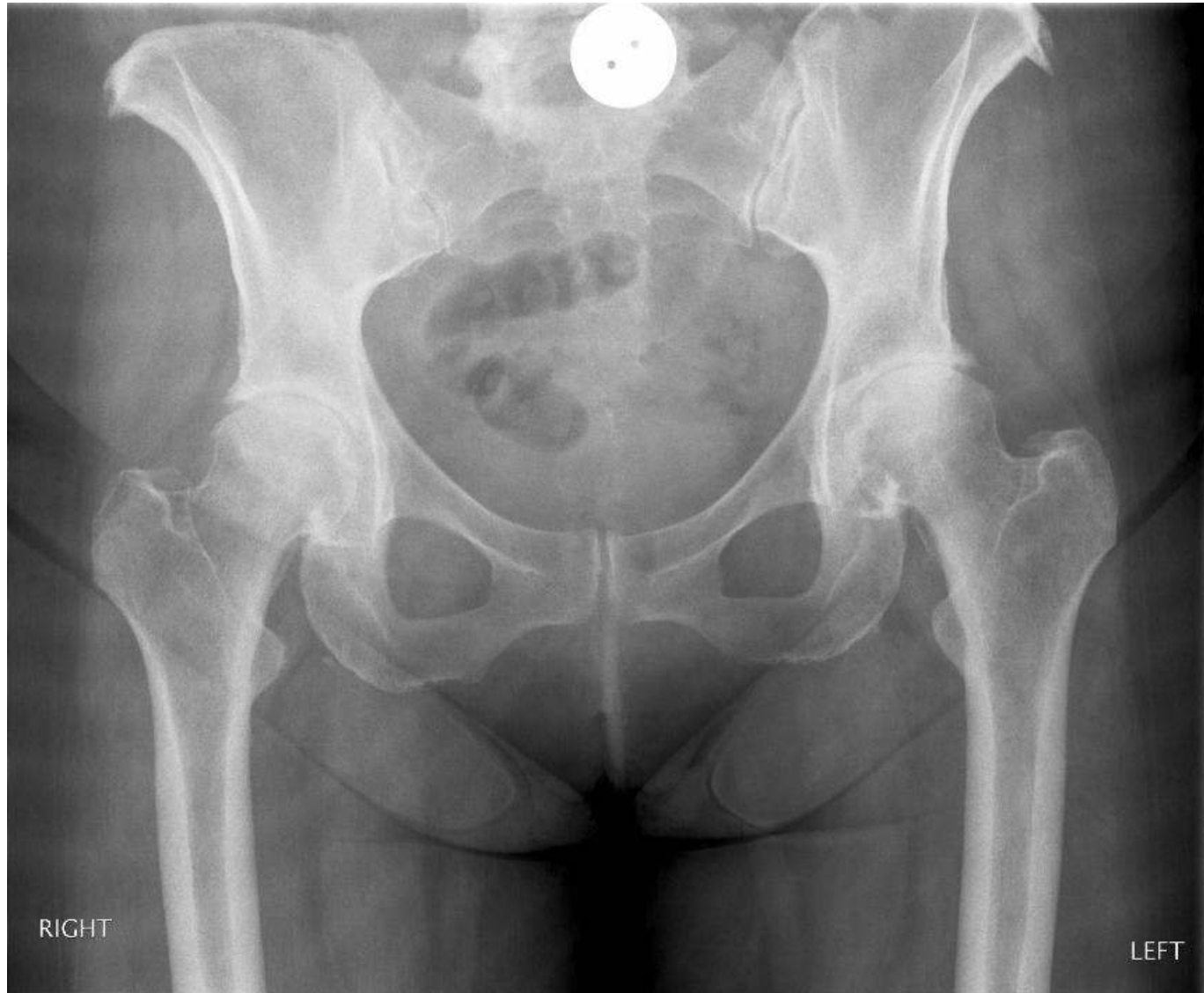Case 1 post op



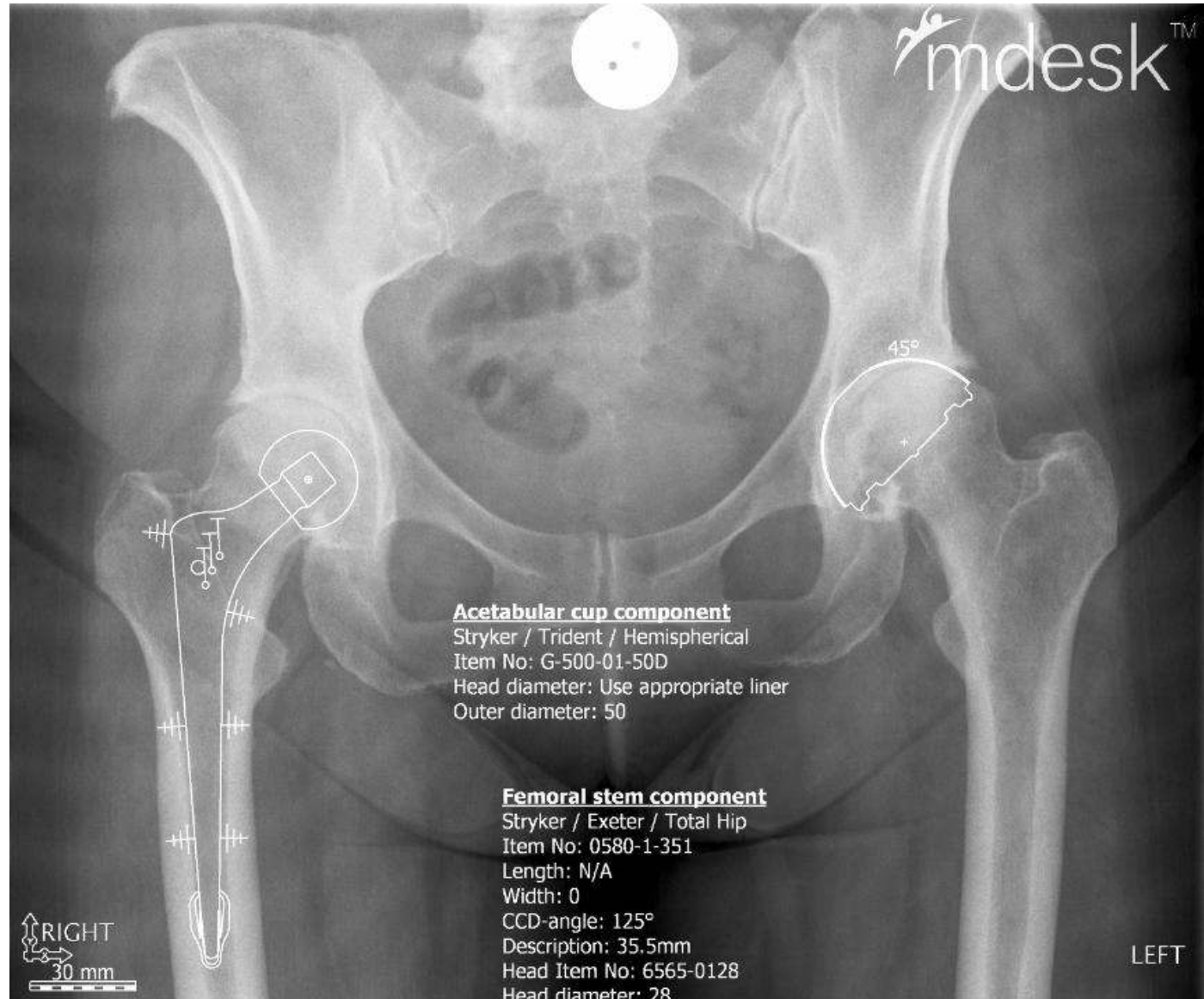Case 1 post op pelvis



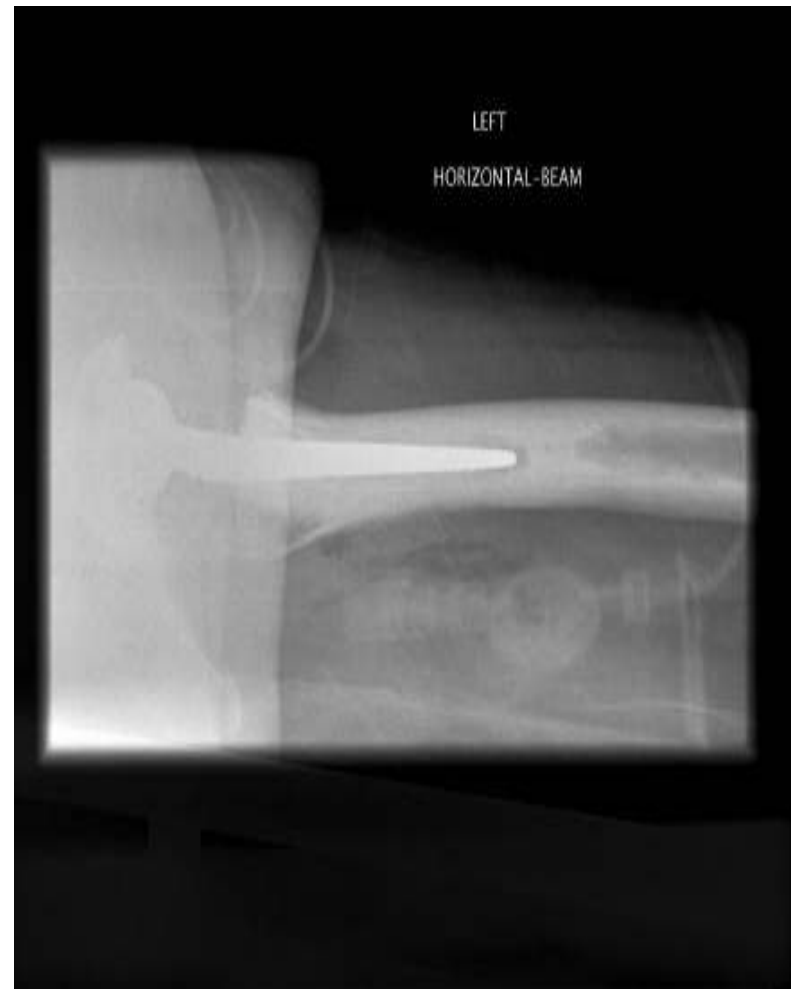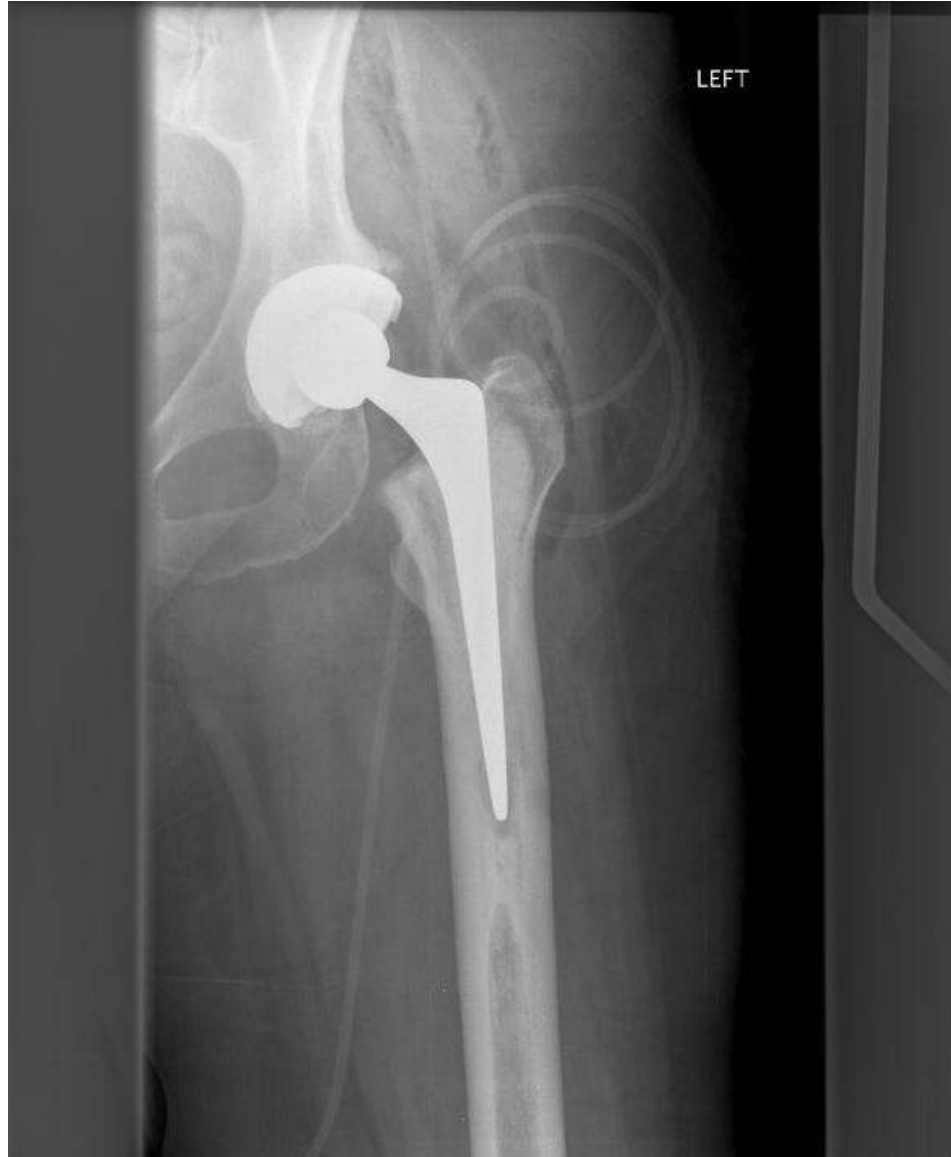Case 2



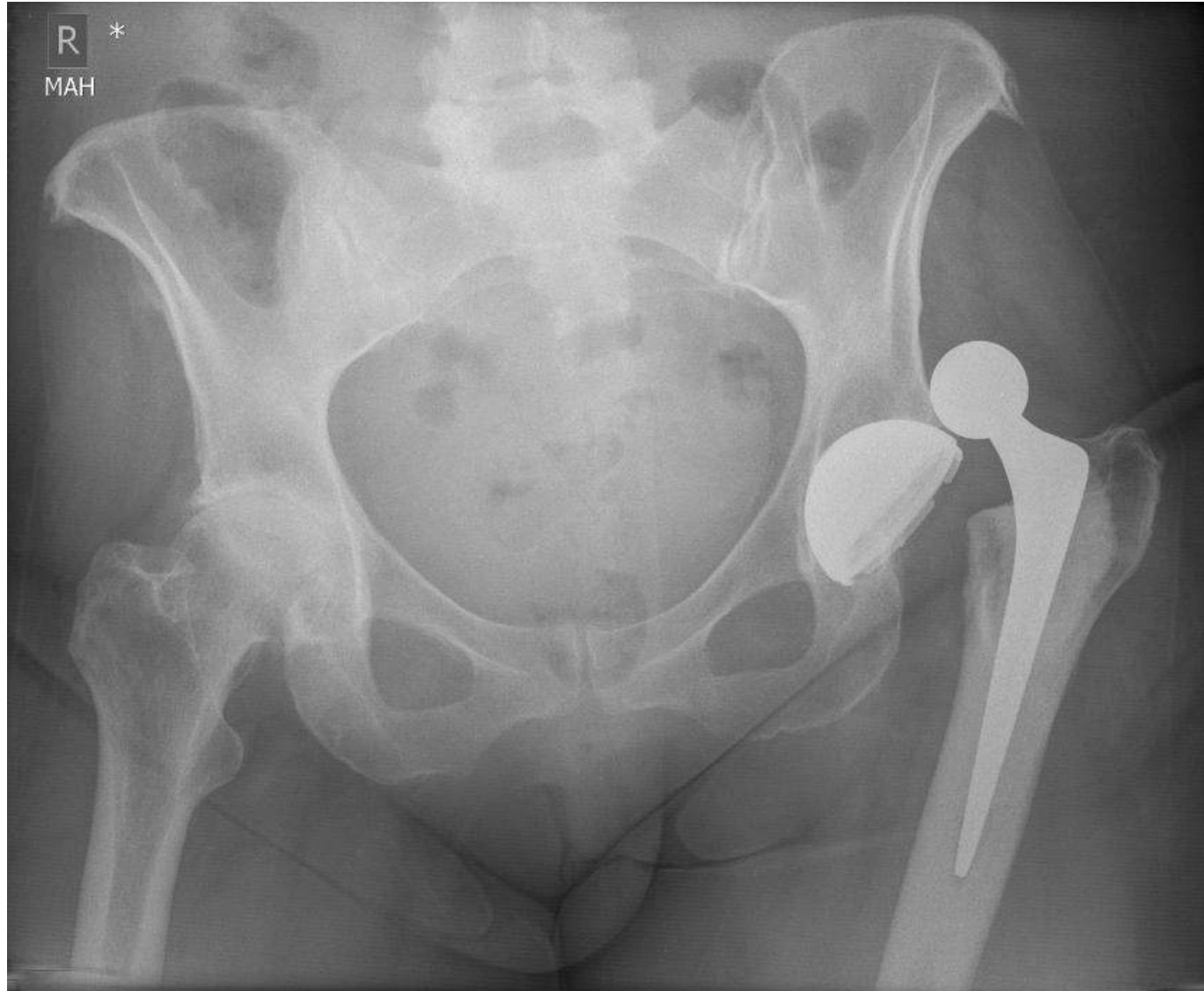
Case 2 templating



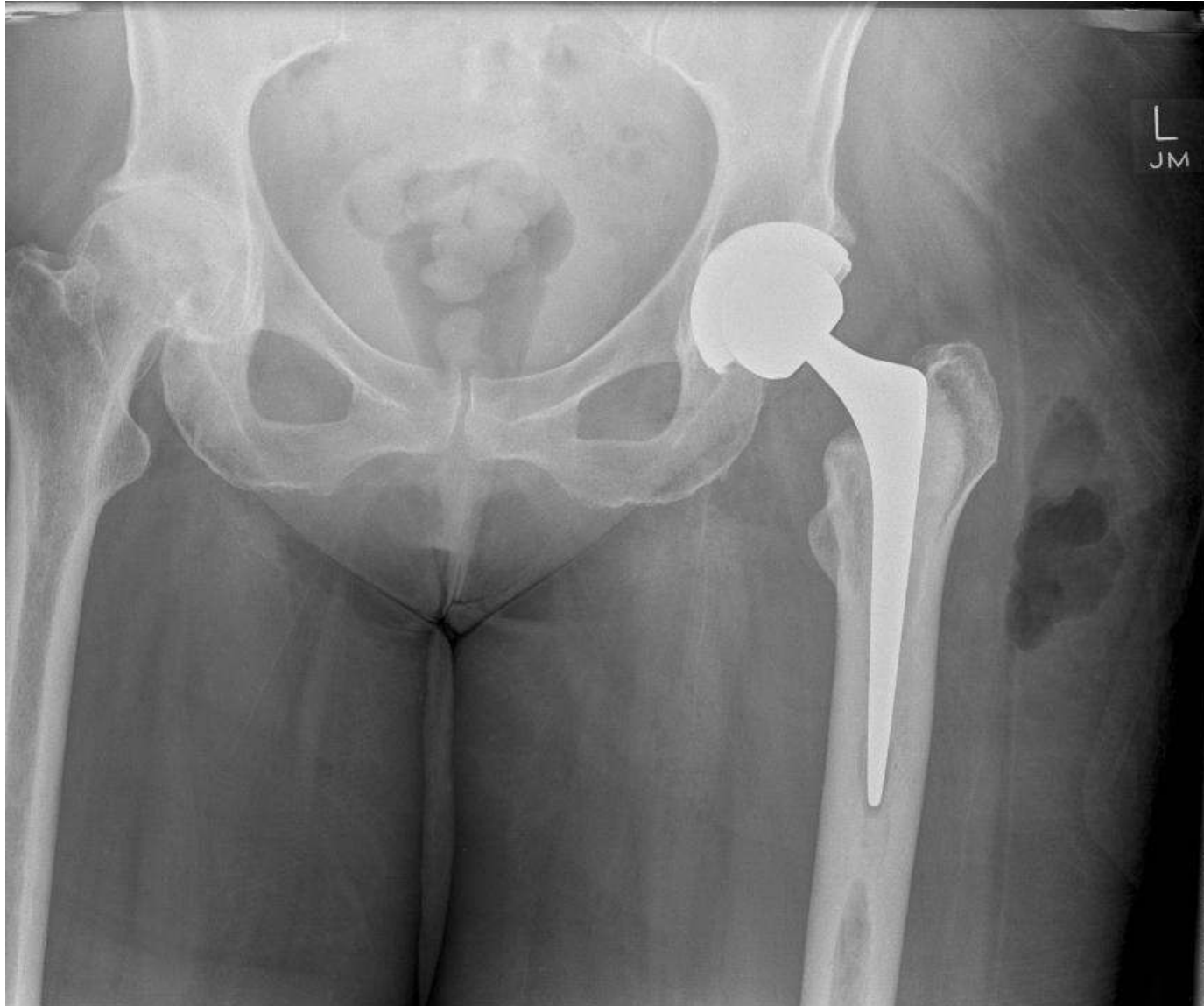
Case 2 post op



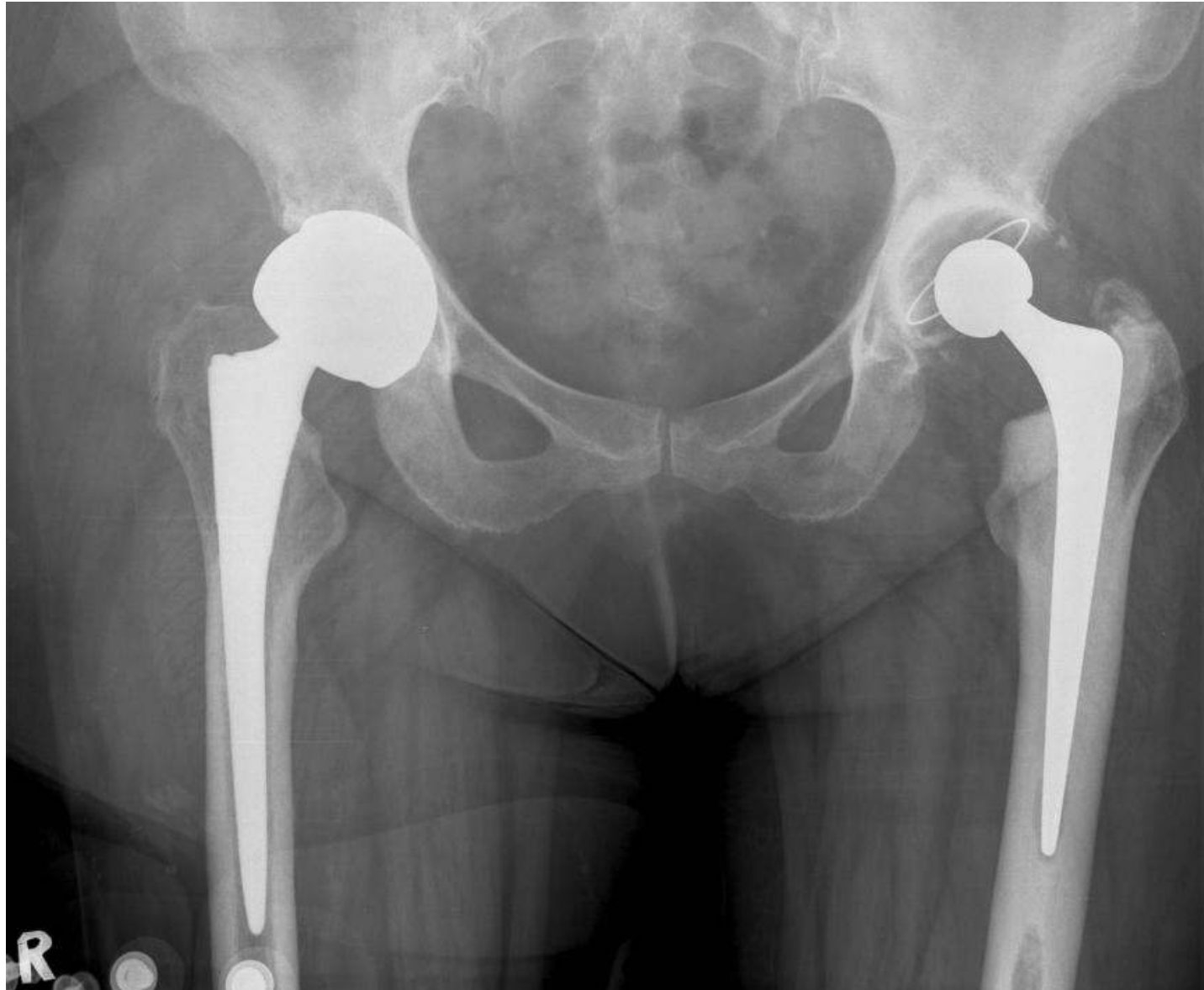Case 2 dislocated



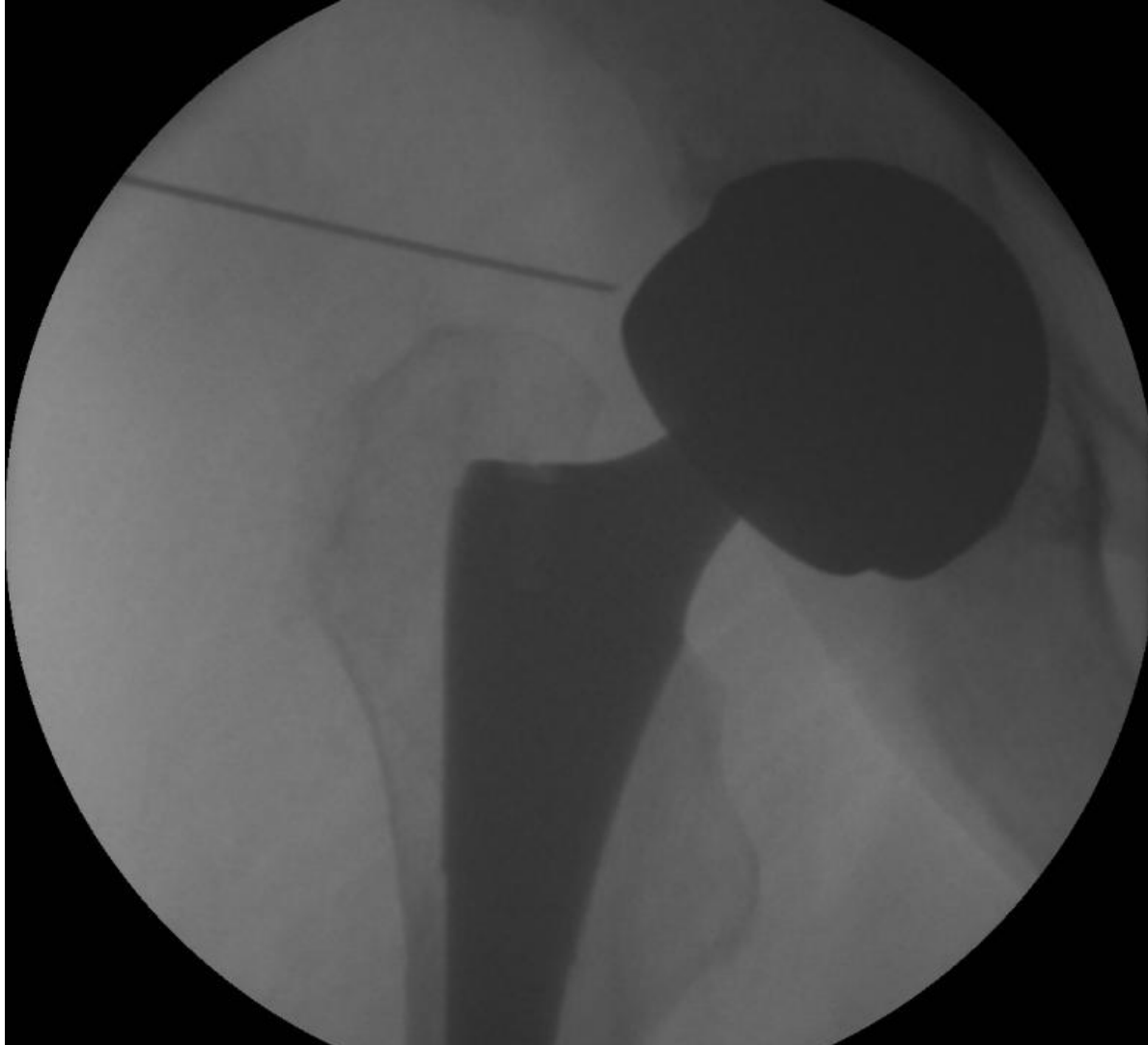Case 2 post op revision



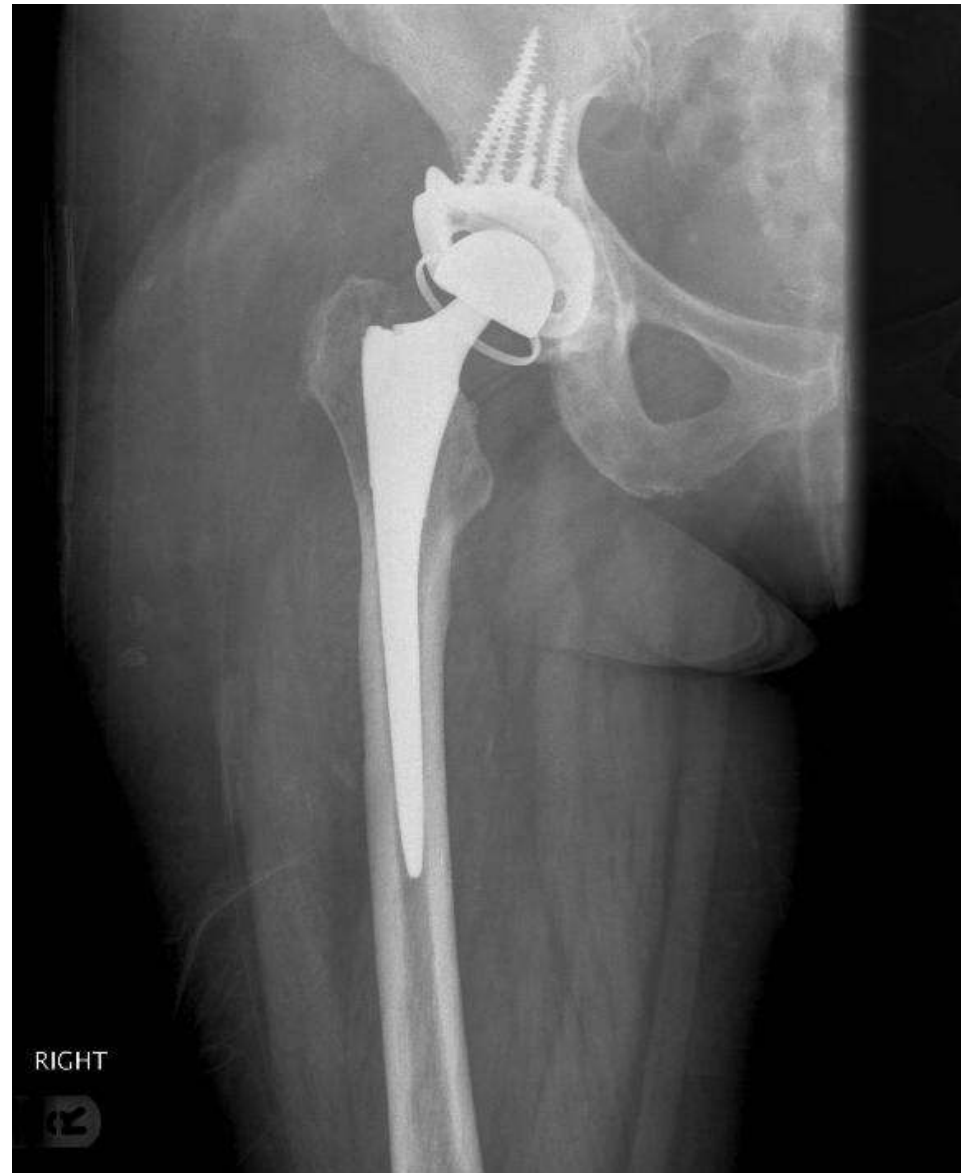Case 3



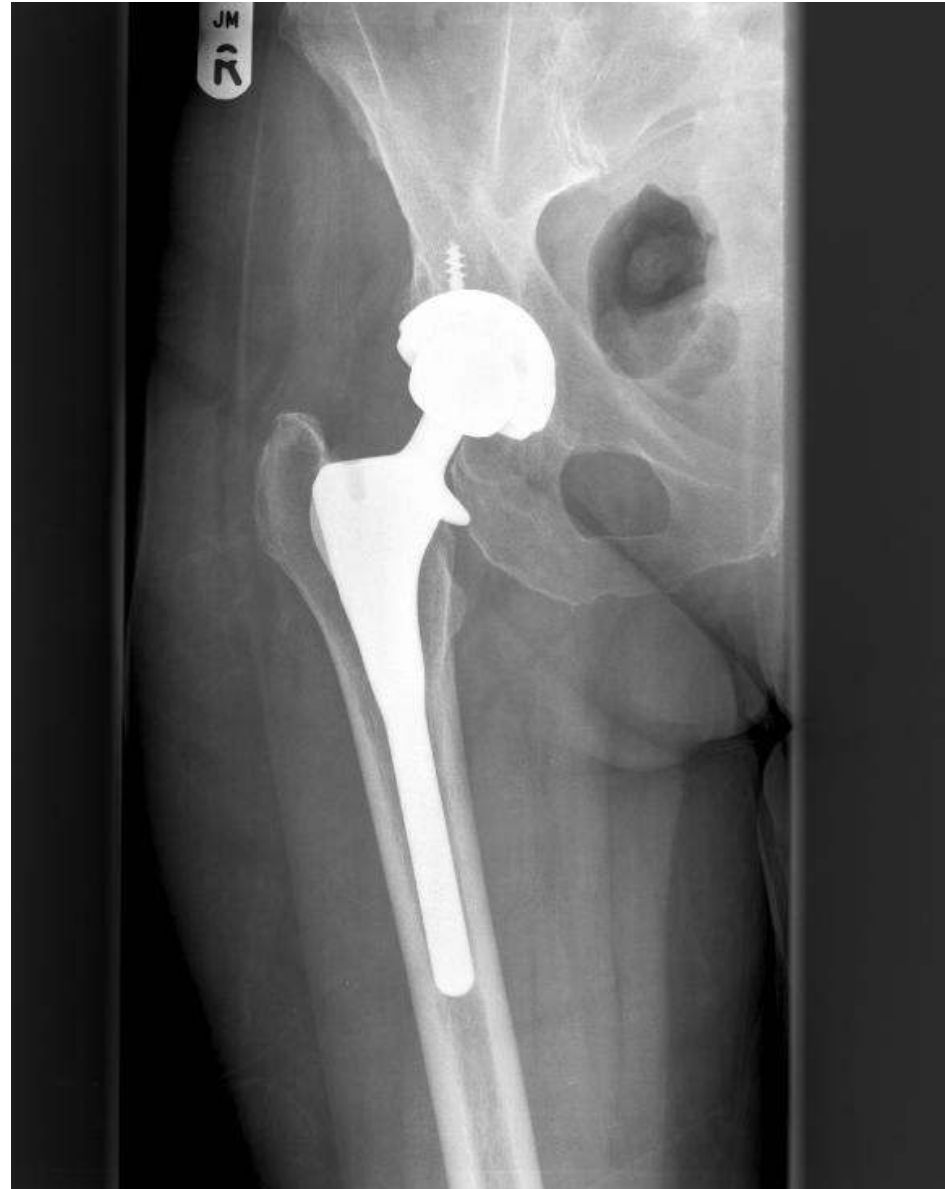Case 3 asp



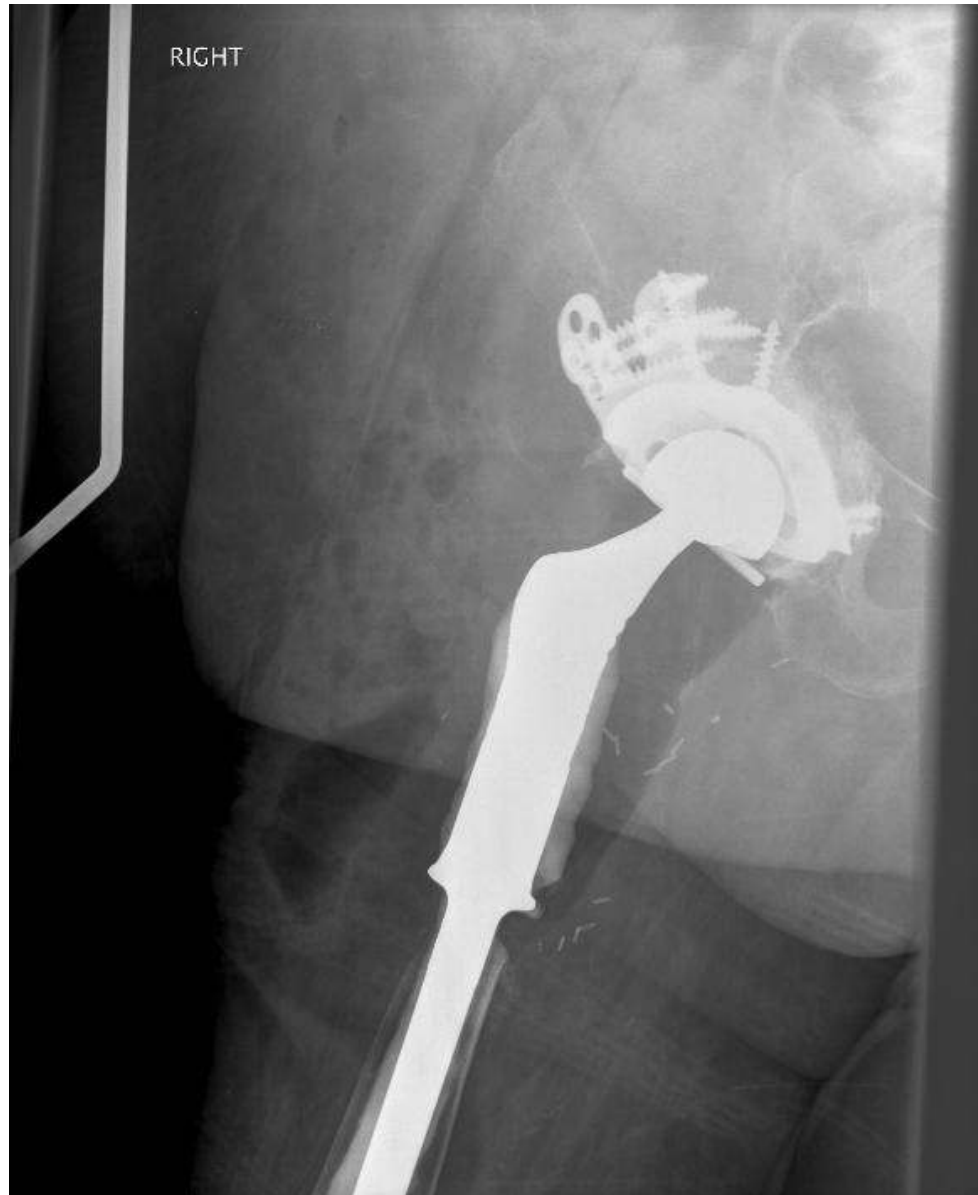Case 3 post op



Case 4



Case 5



Case 6

