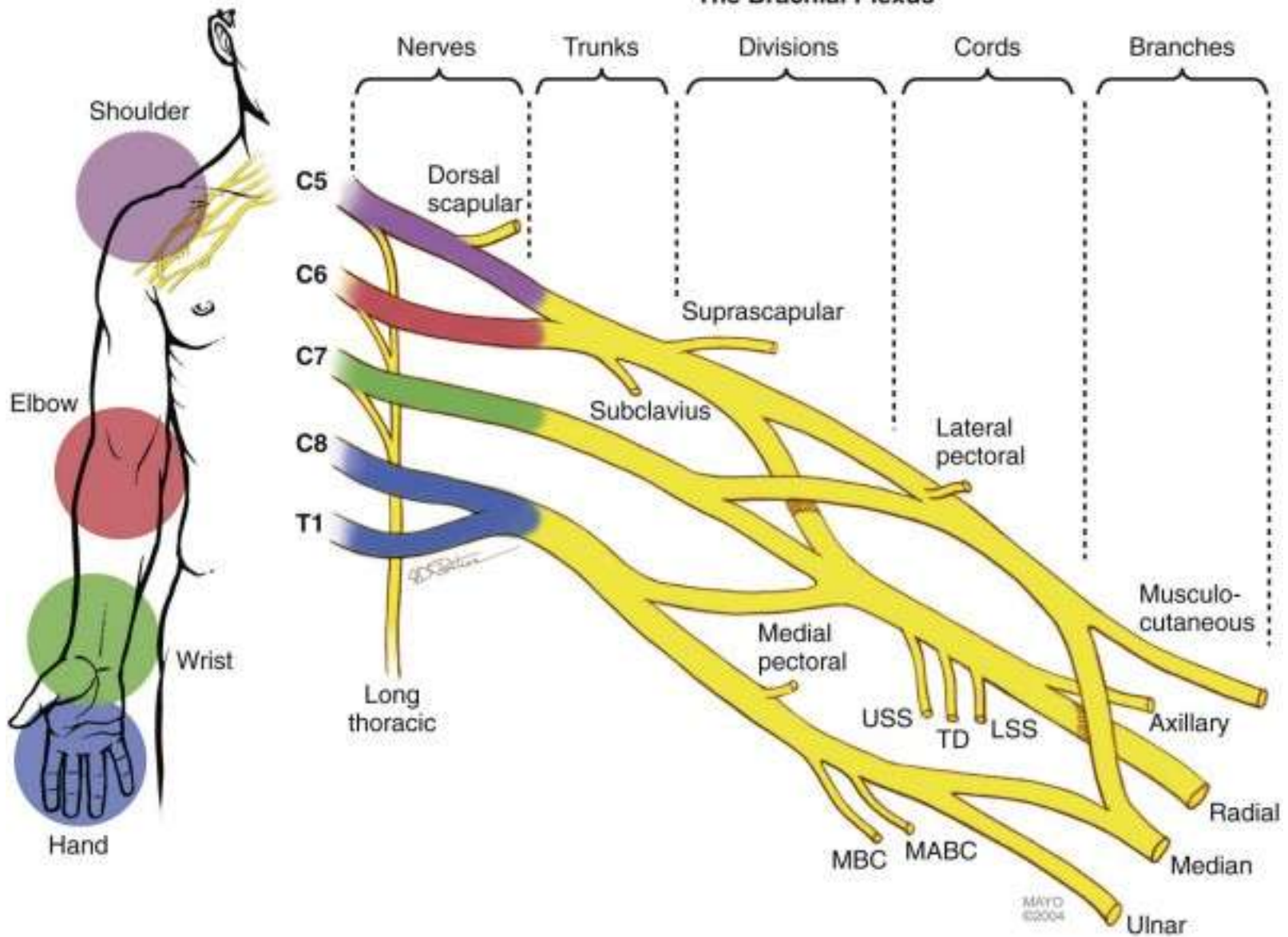


# CLINICAL EXAMINATION

Mr S Miranda



# The Brachial Plexus



# Case 1 - RB

- DOI 18/03/2013
- Fall in garden & left shoulder dislocation

## Case 2 - GF

- Painful arm
  - spontaneous onset with developing weakness.

# Case 3 - LT

- Spinal cord injury - tetraplegia

# Case 4 - SS

- Brachial plexus injury 1974 and flail right arm