

Minimally Invasive OsCalcis # Fixation

A N Murty

+ Simon Jones

Buckley RCT

- Bohlers Angle = Height.
- IA Step upto 2mm allowable
- Heel width

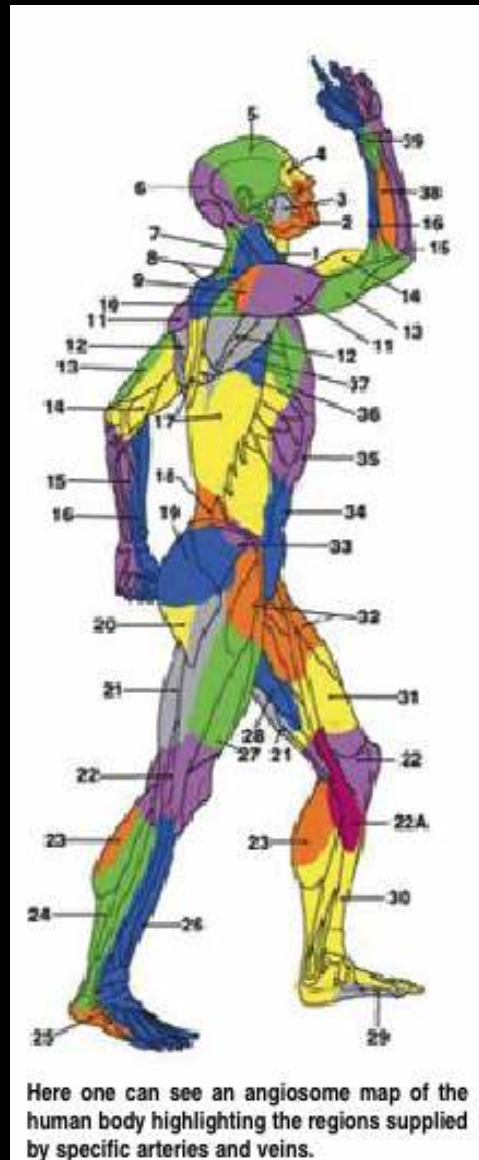
Soft Tissue injury determines outcome

- Smokers
- Co-morbidities
- Pi-----ks

Literature

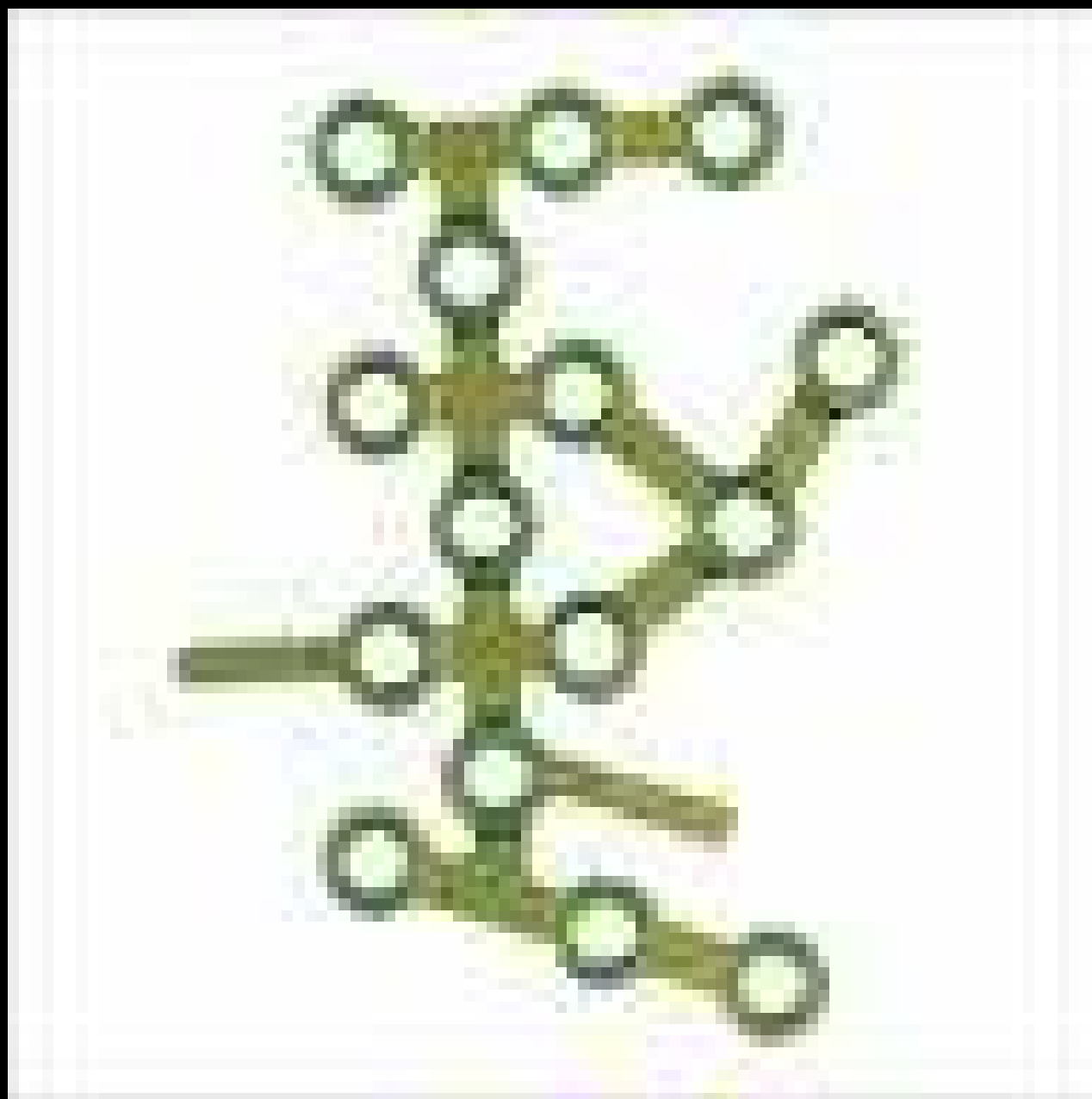
- Helfet et al Extrarticular dimensions of Calcaneum.
- Forgon and Zedvarecz 1983 – Distractors
- Weber (JBJS 2008) – limited approach

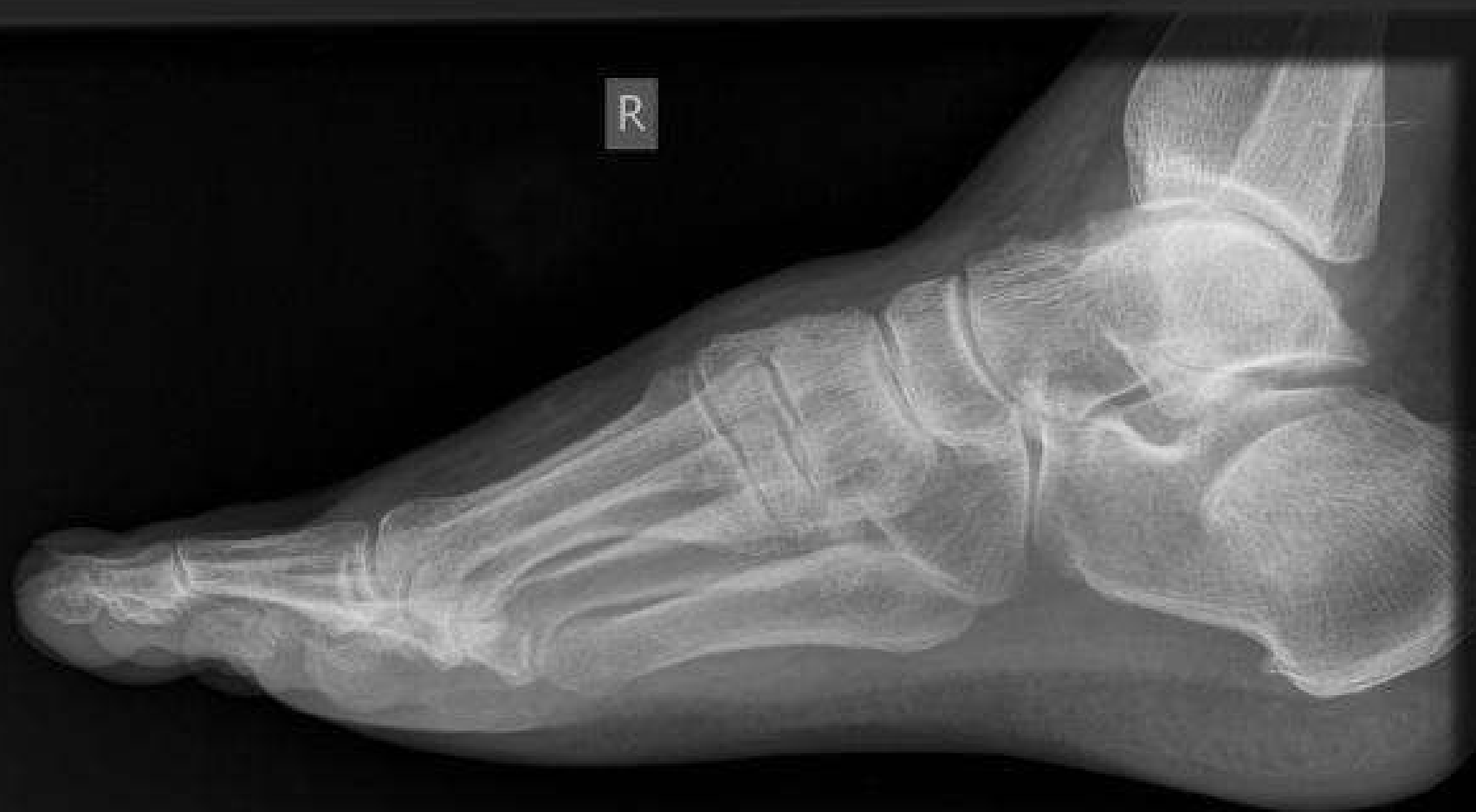Angiosomes

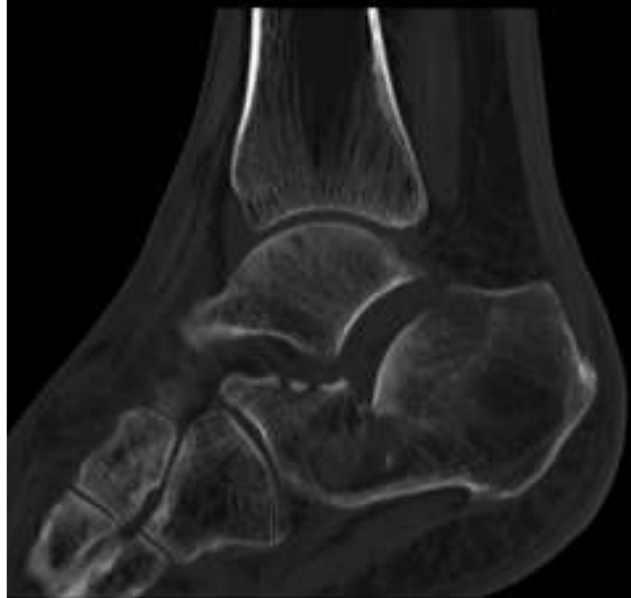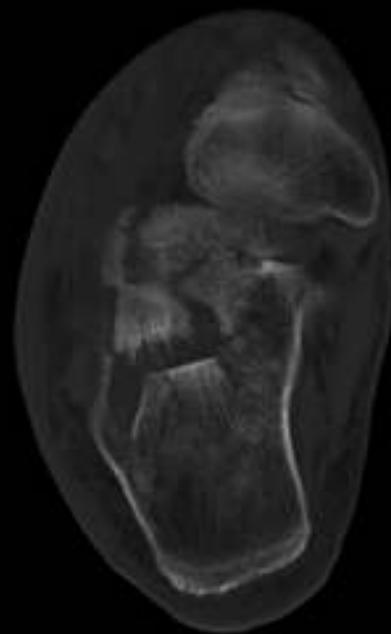
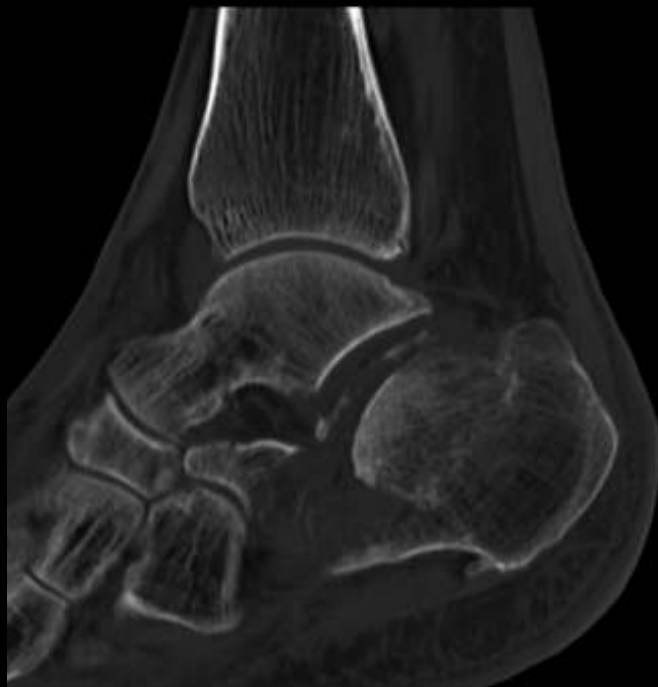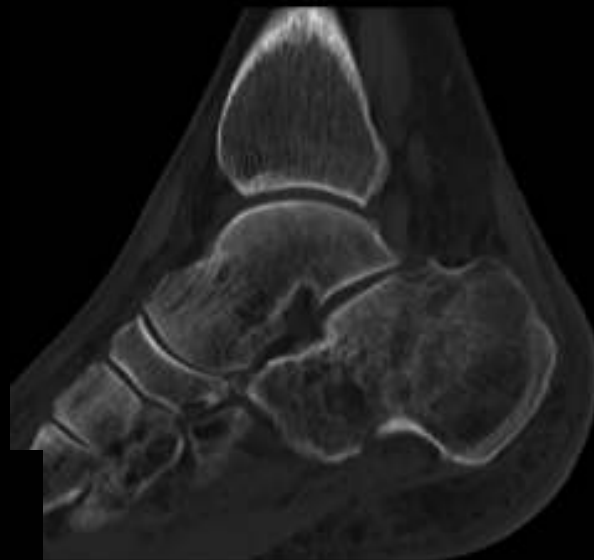


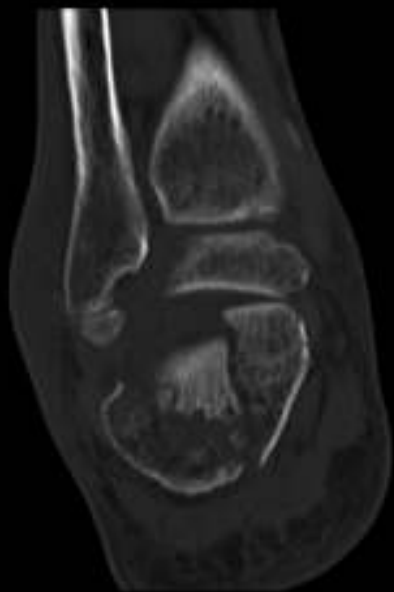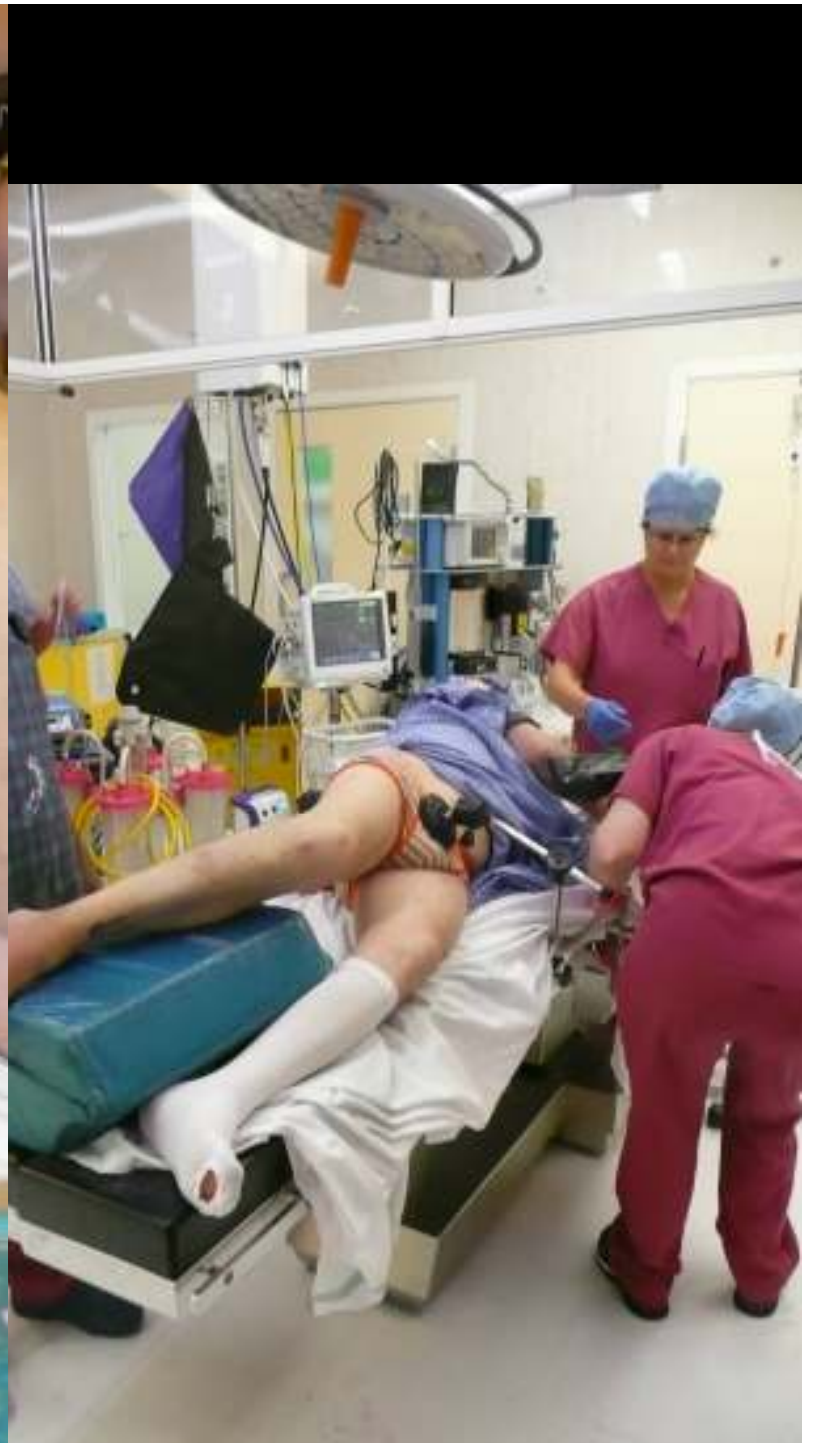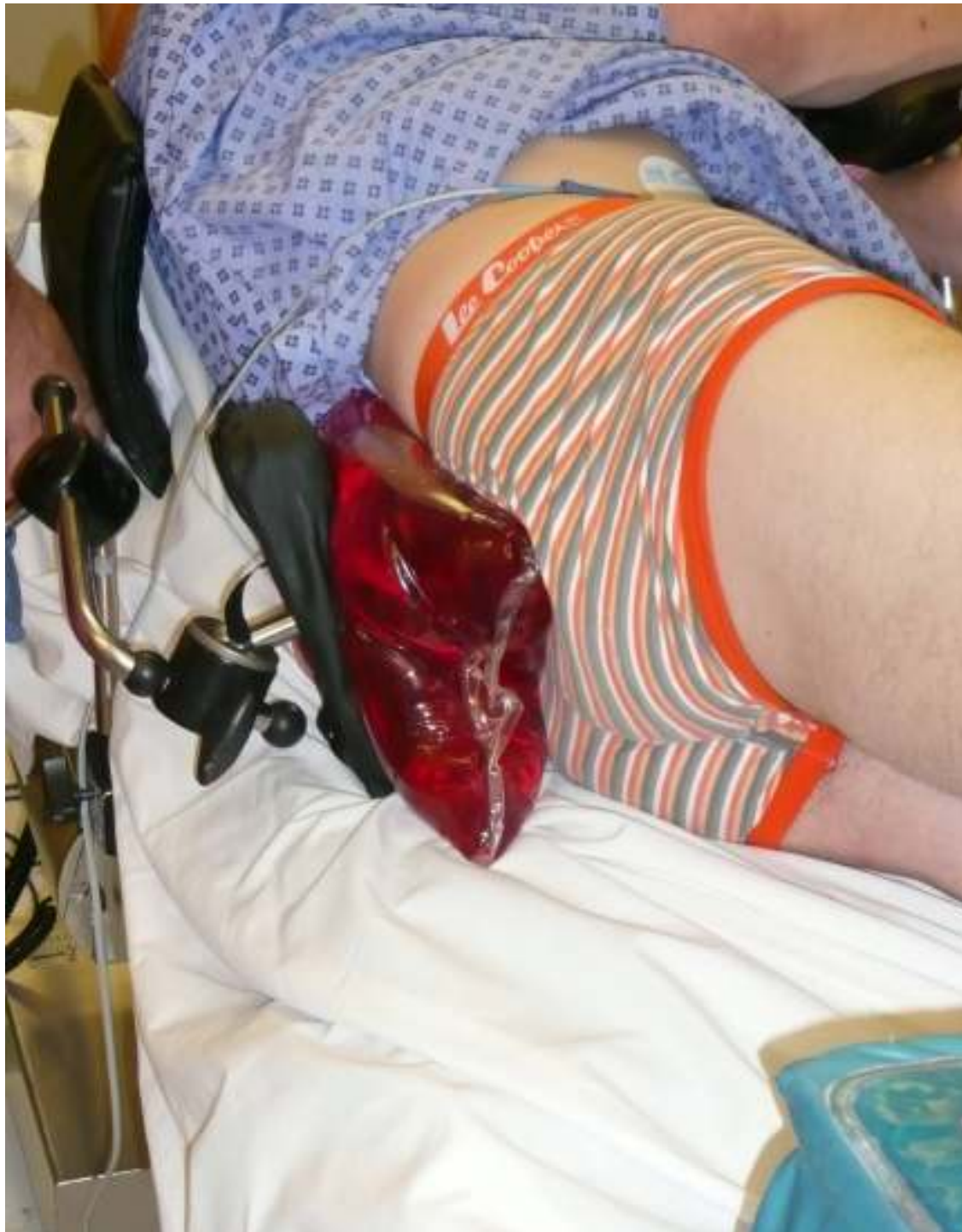Plan

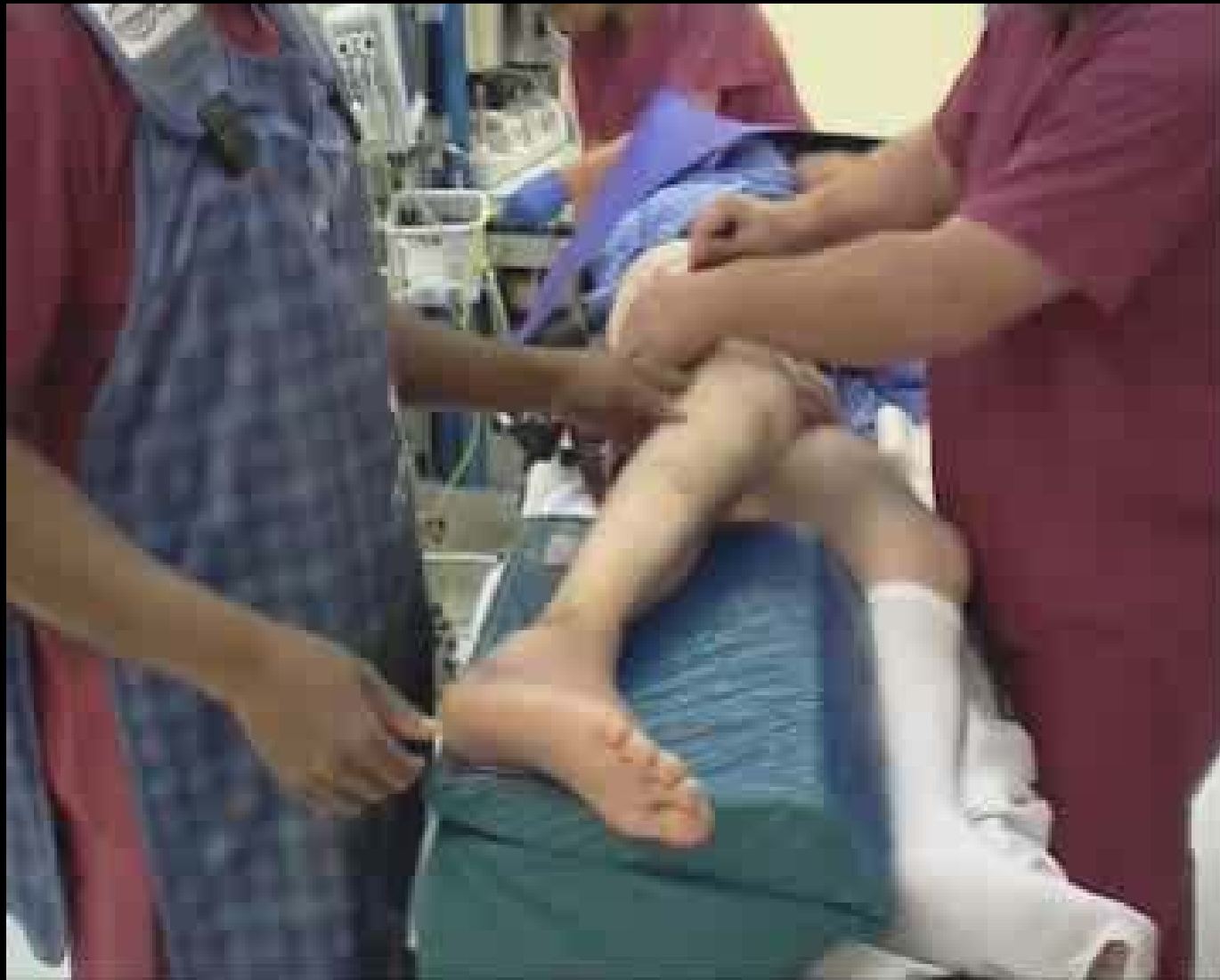- Fracture pattern - CT
- Approaches
- Soft tissues – Sural nerve,
Medial Plantar Nerve
- Timing
- Implants

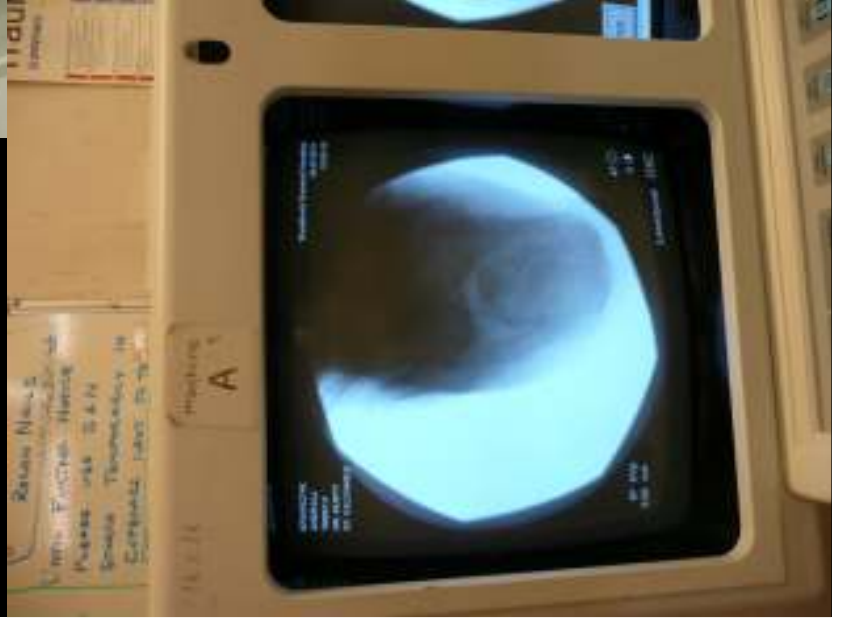
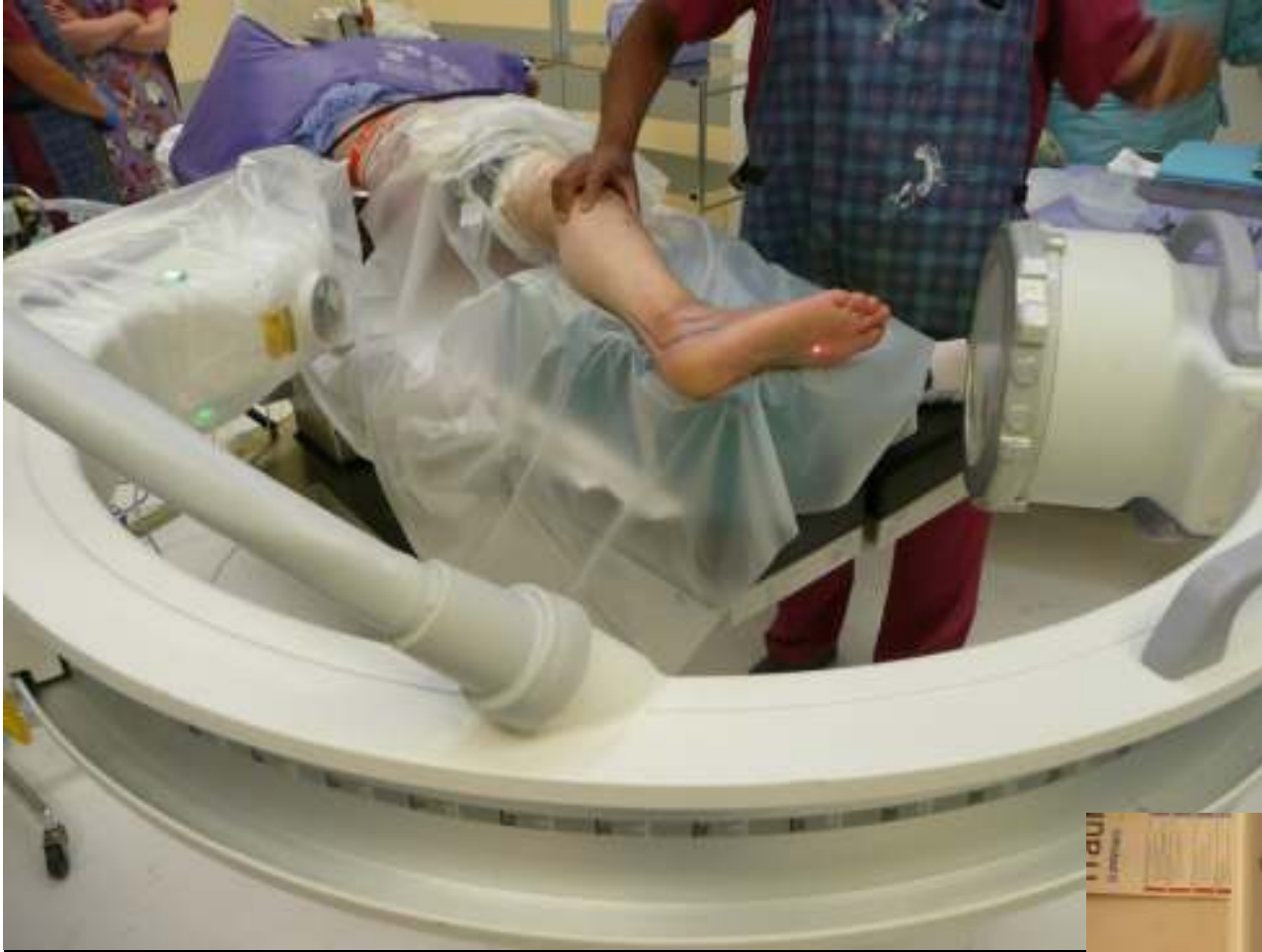


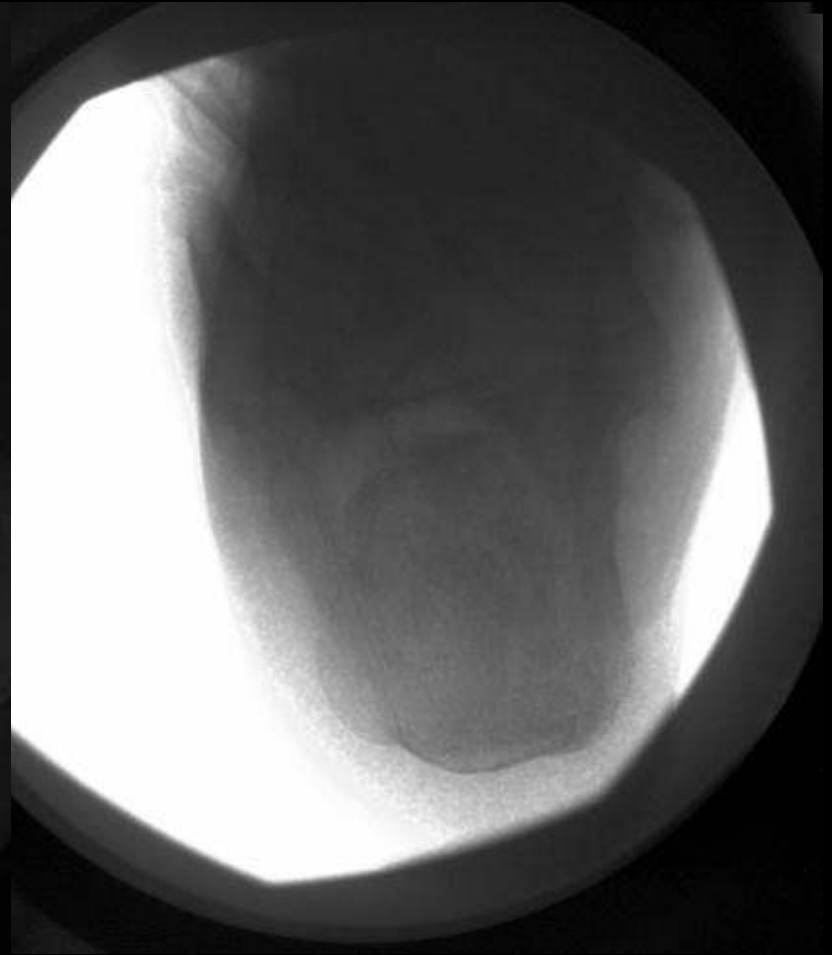
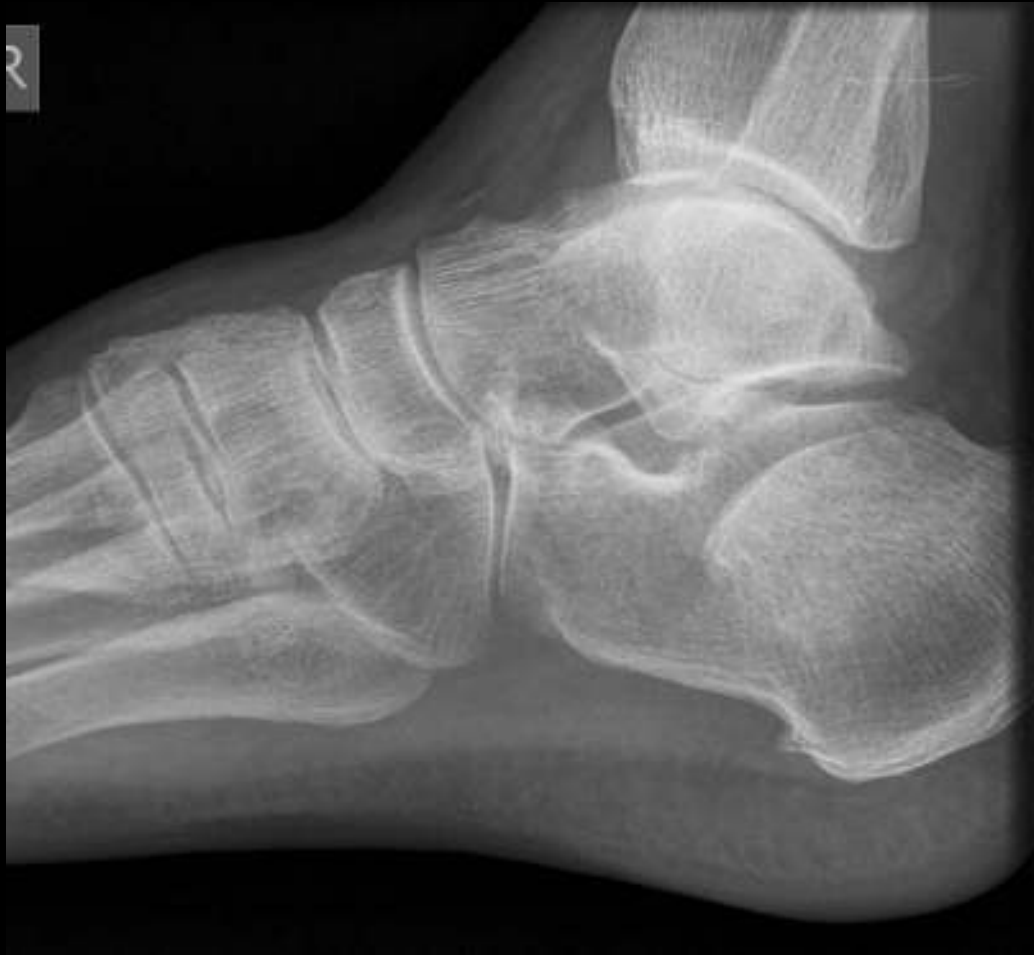


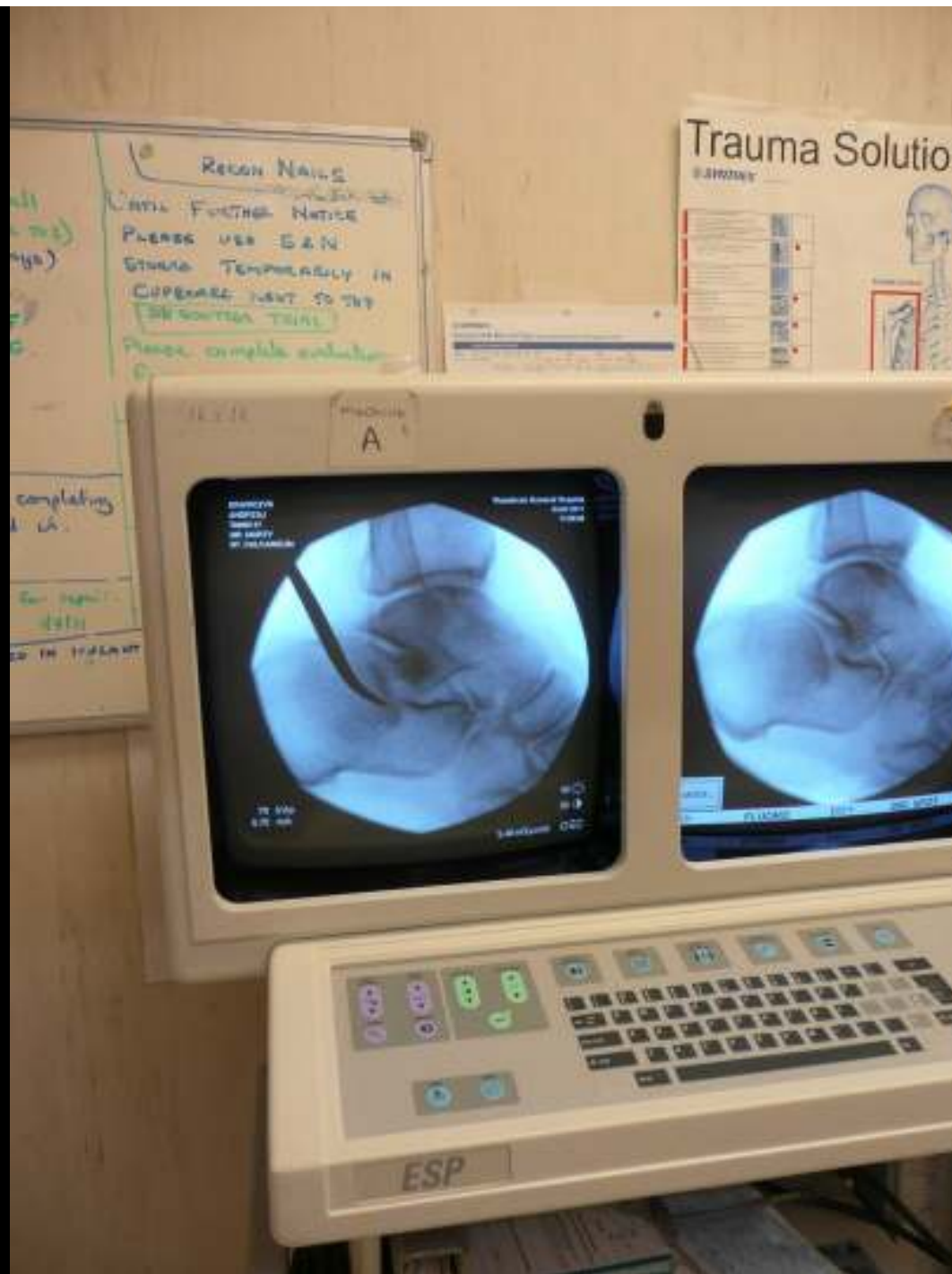


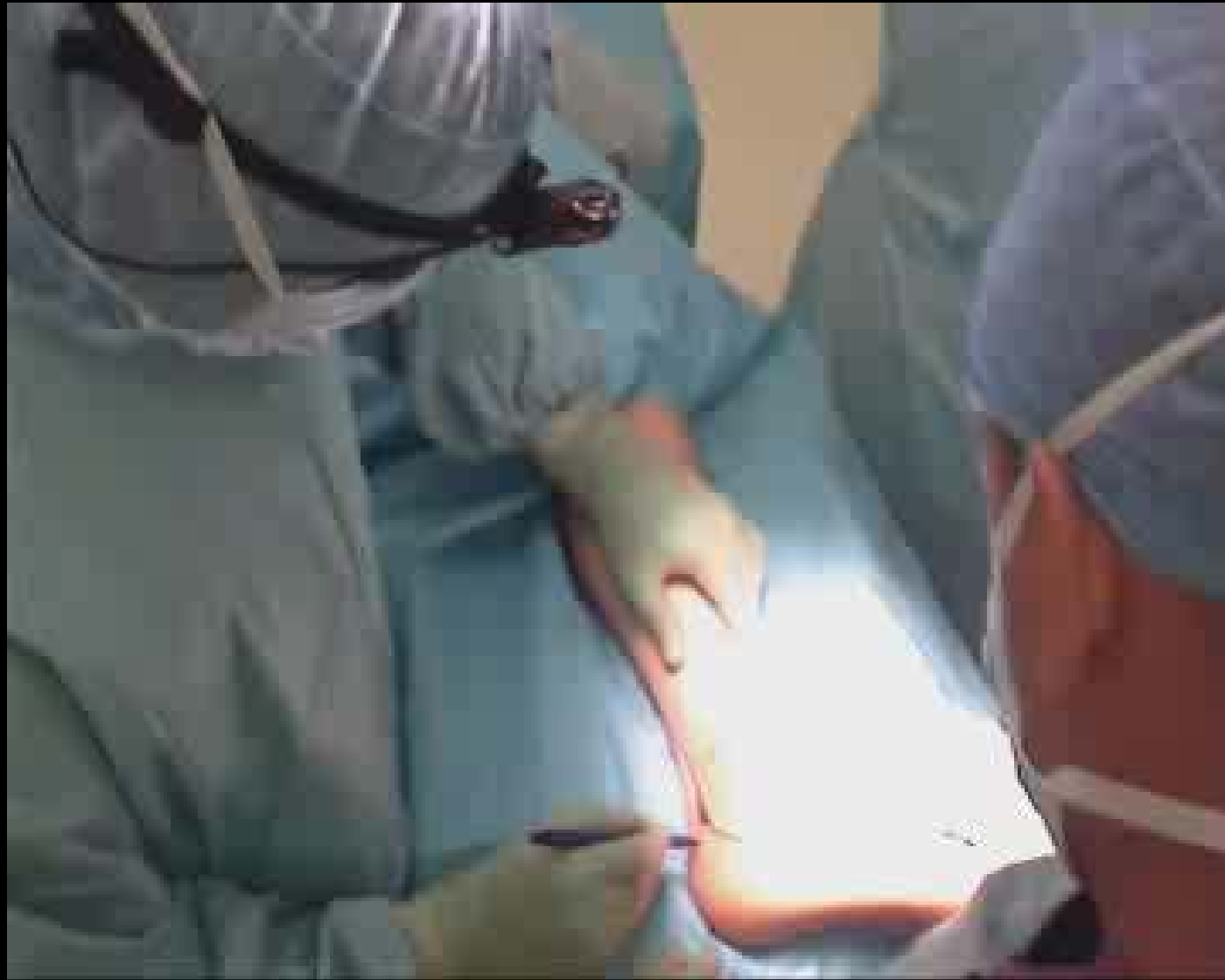


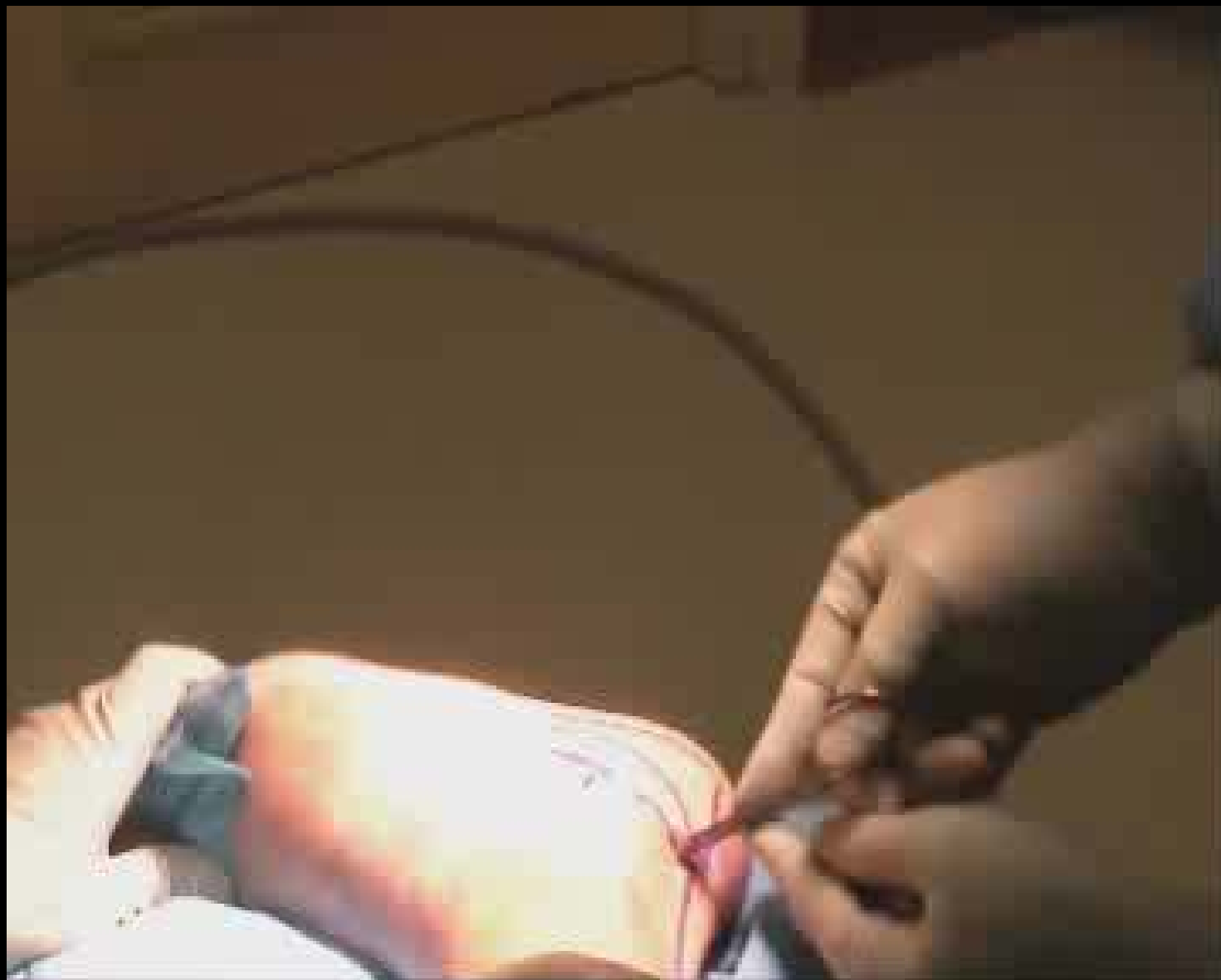


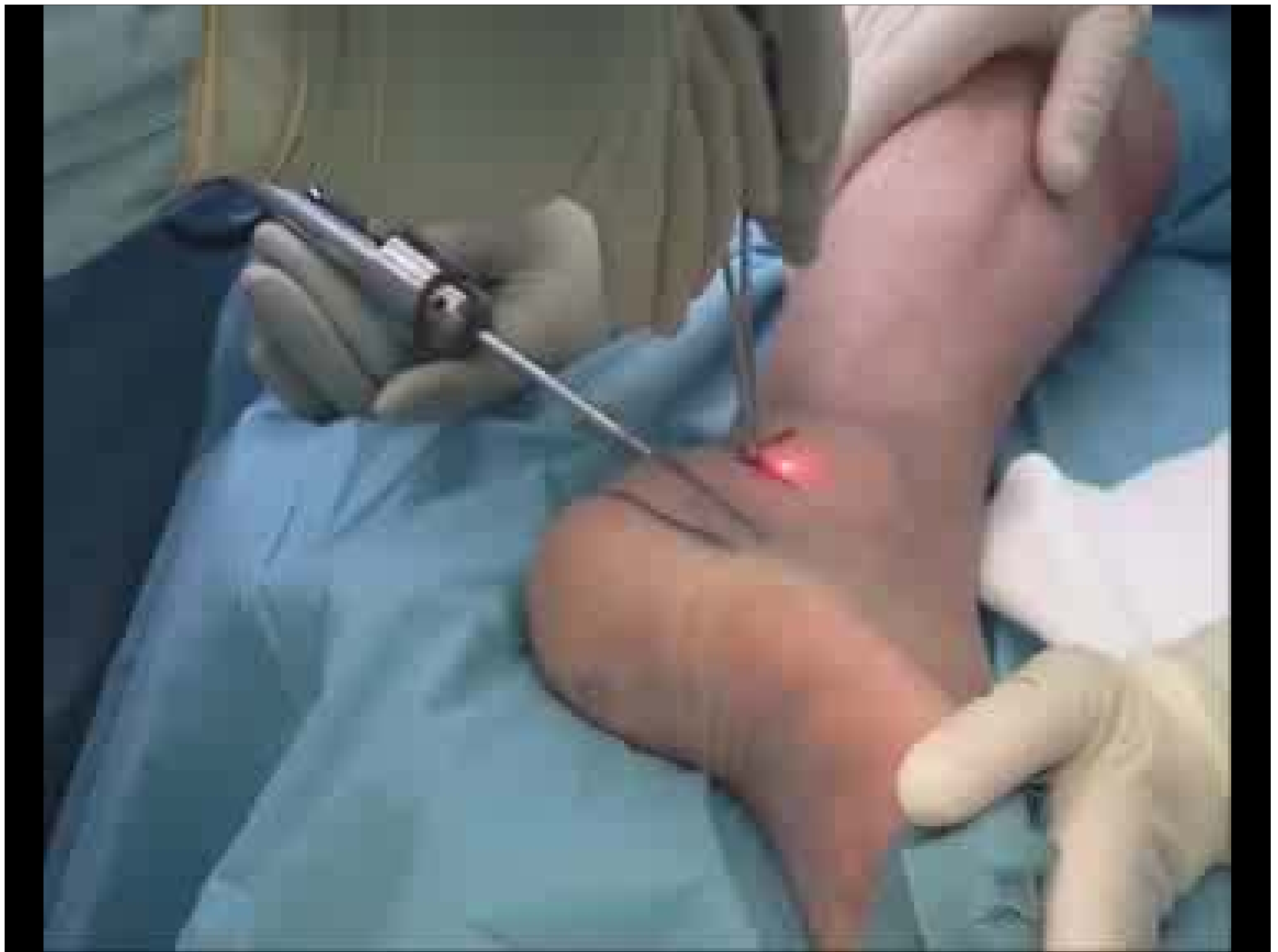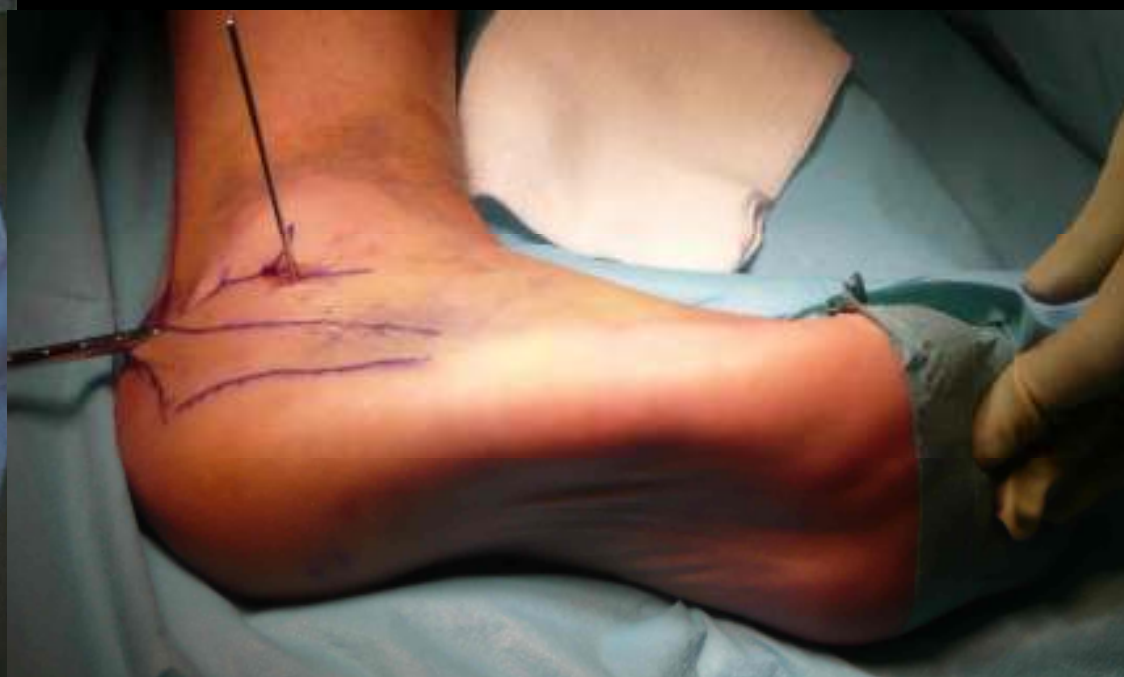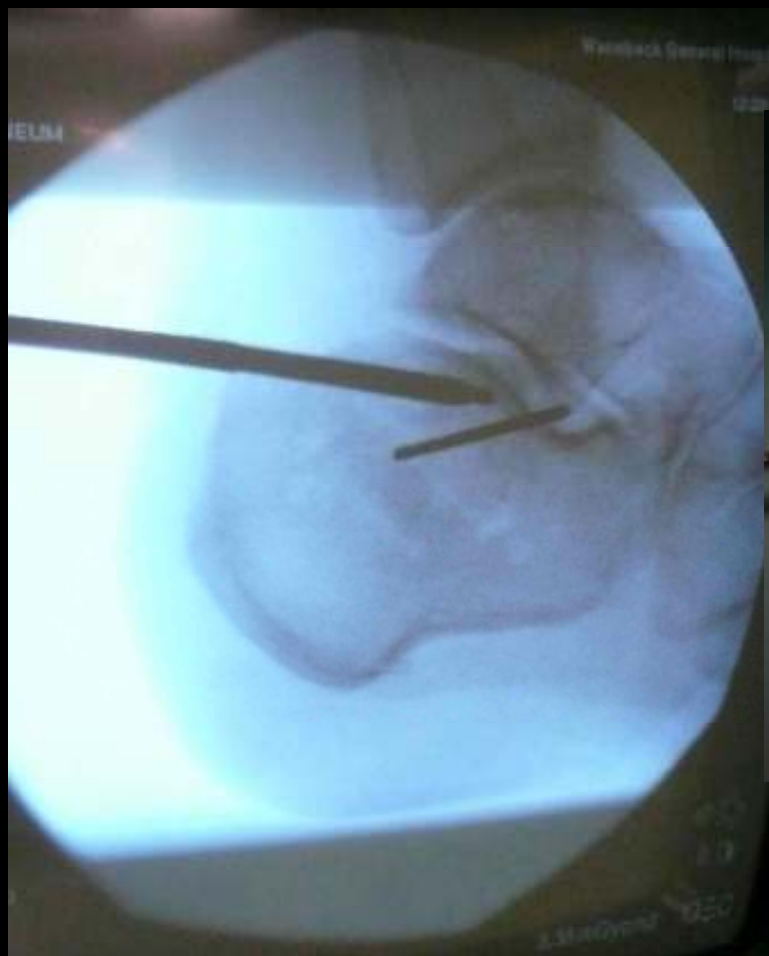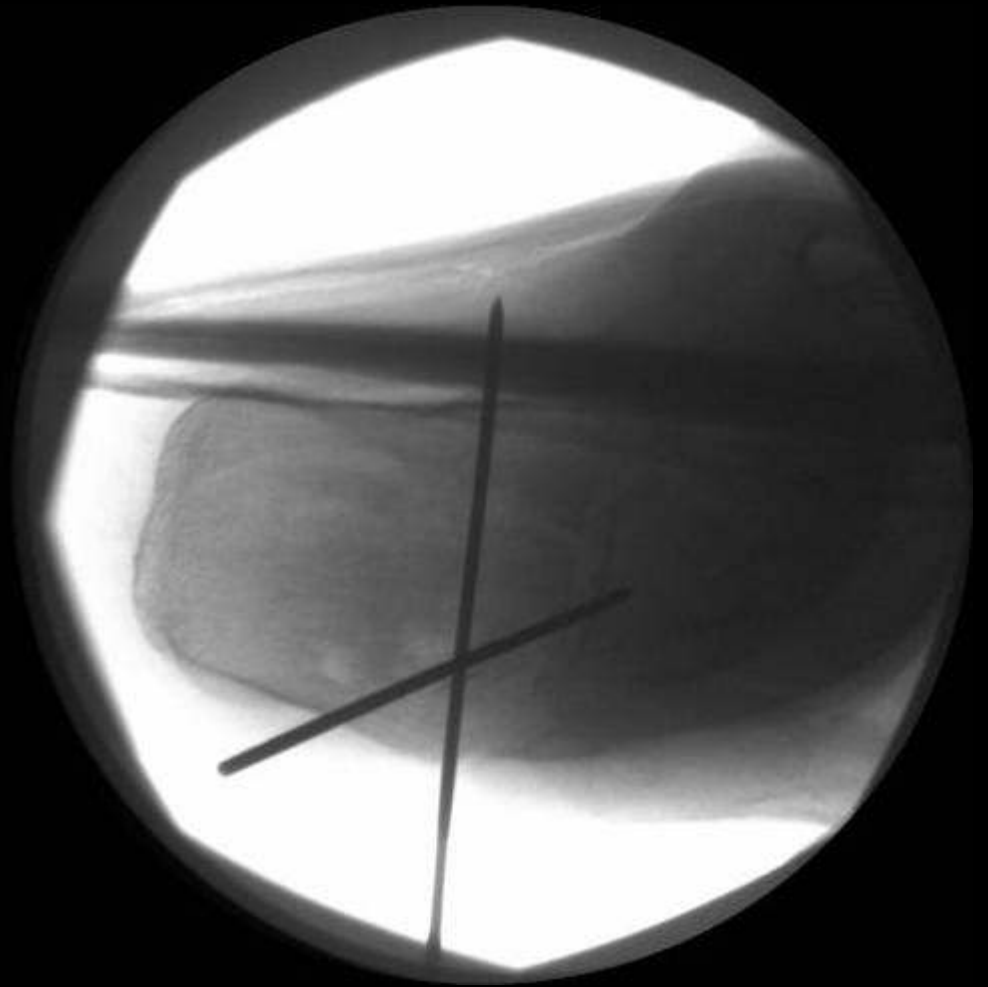






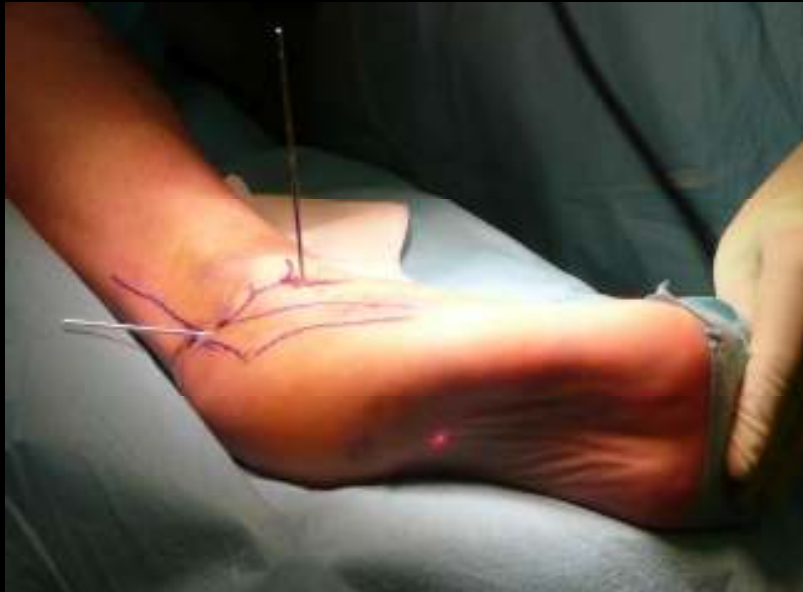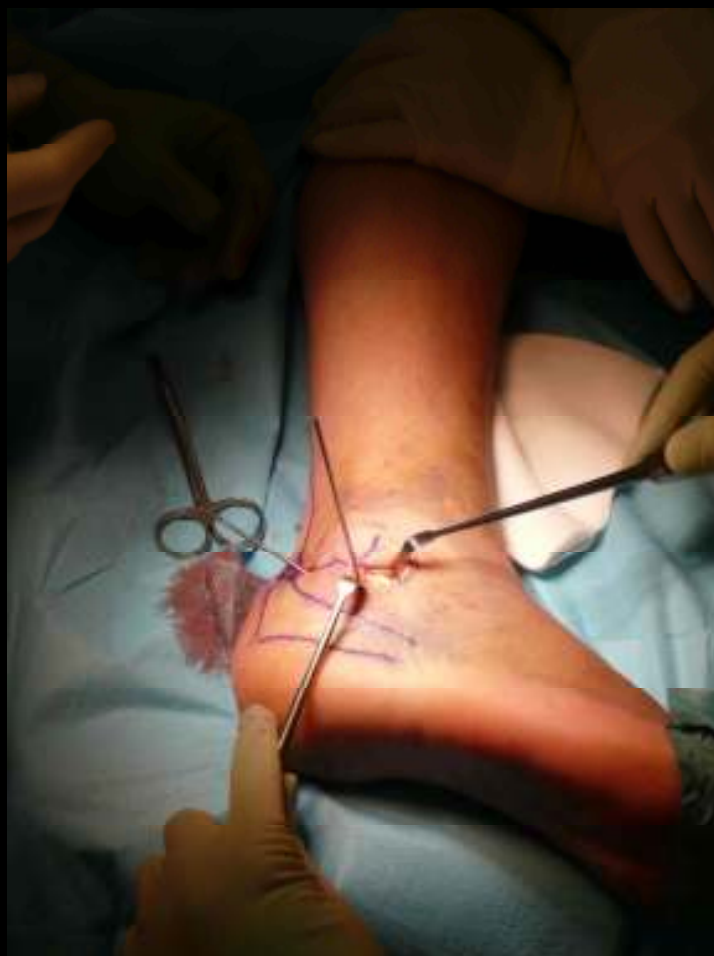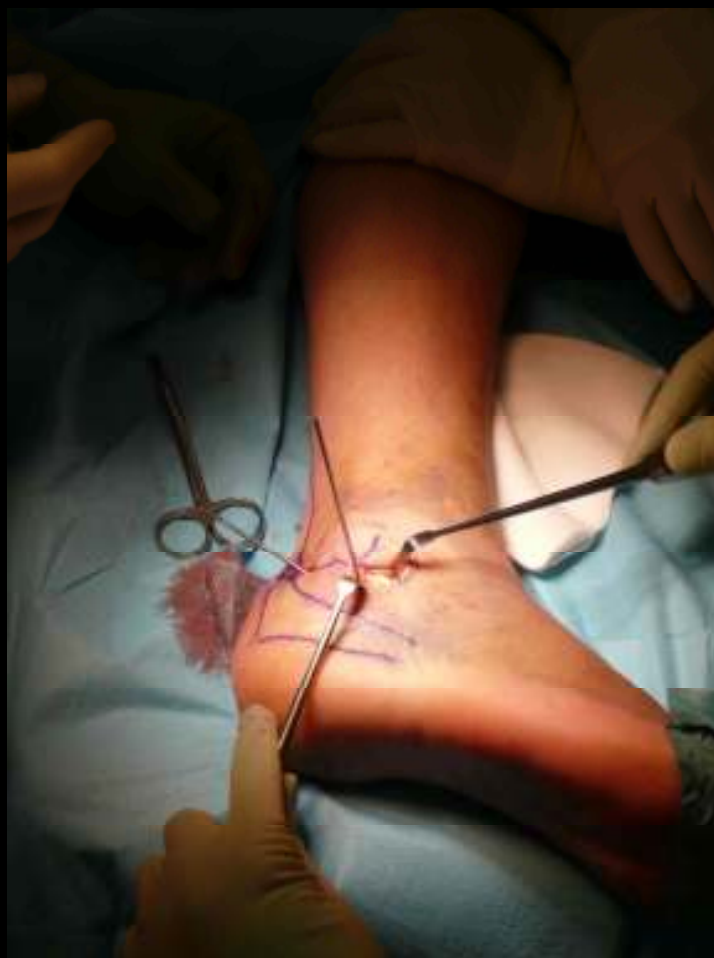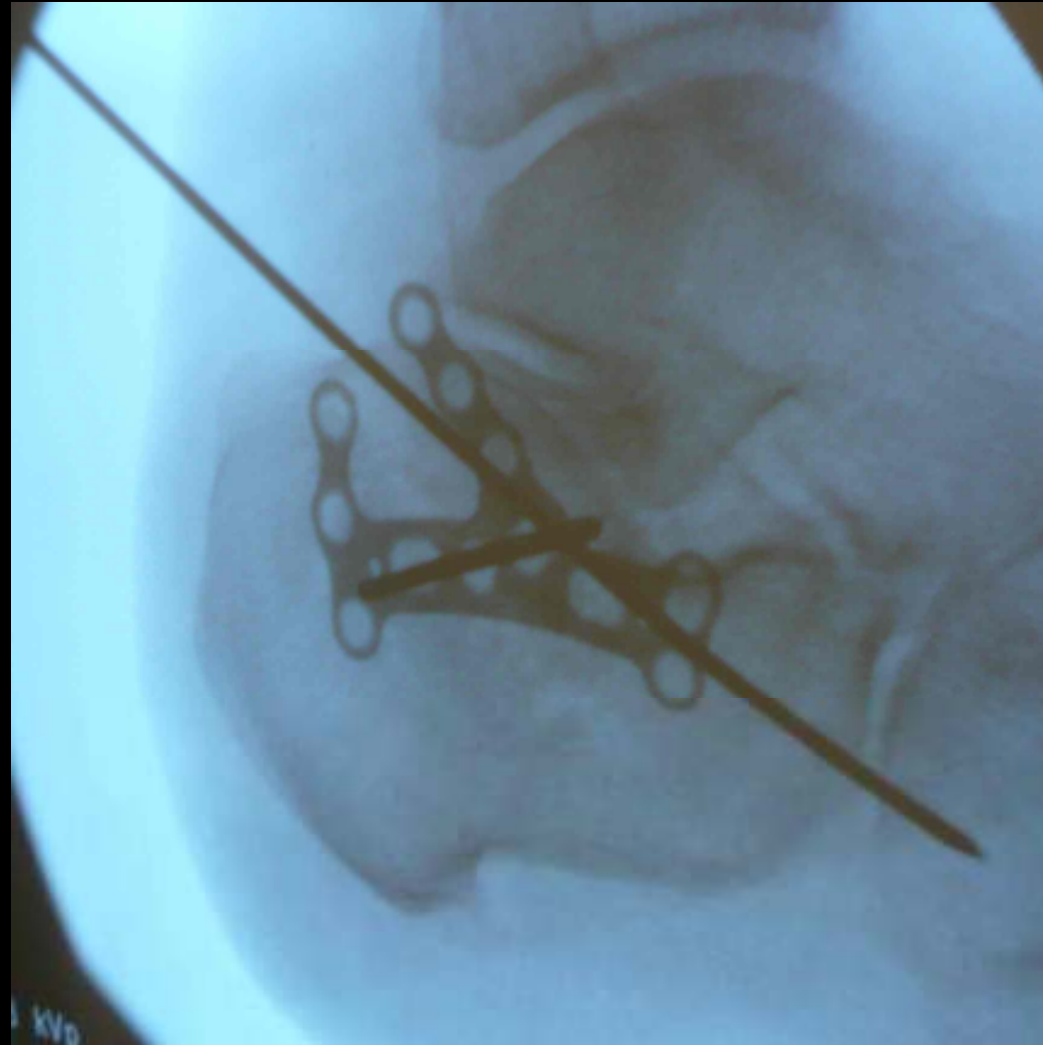




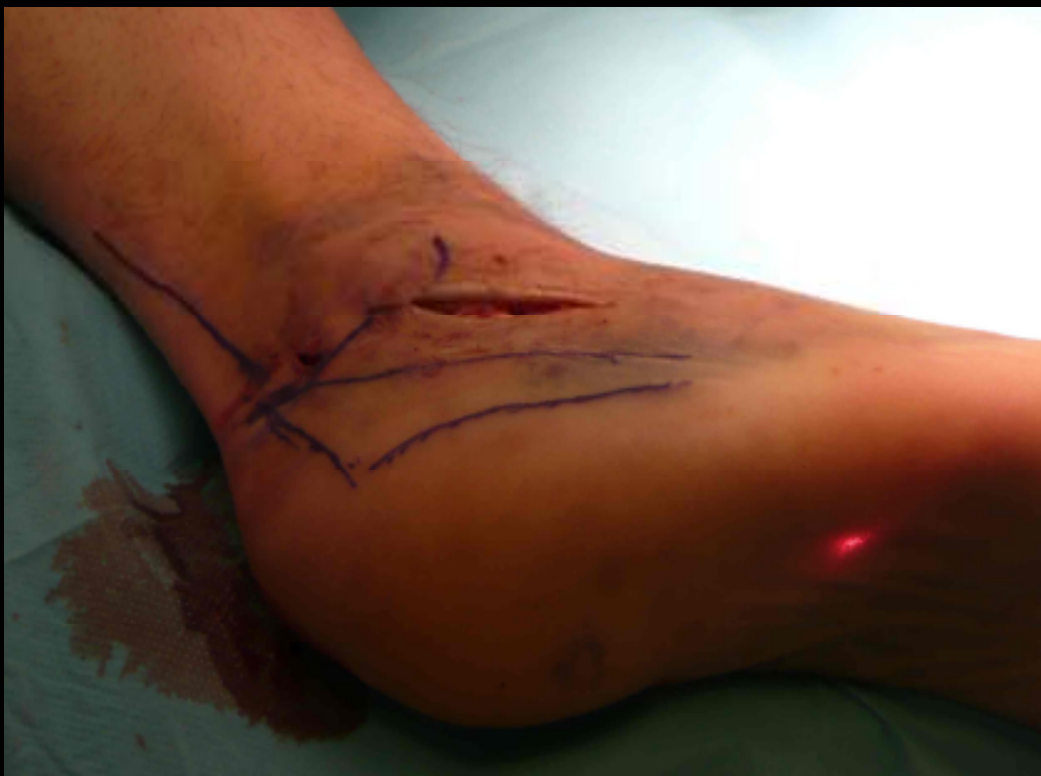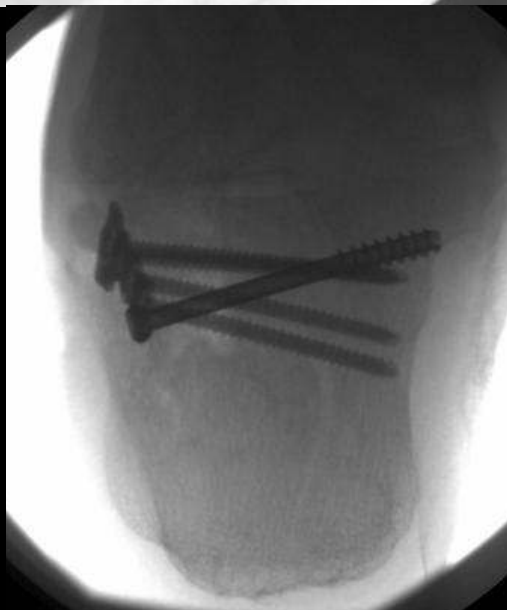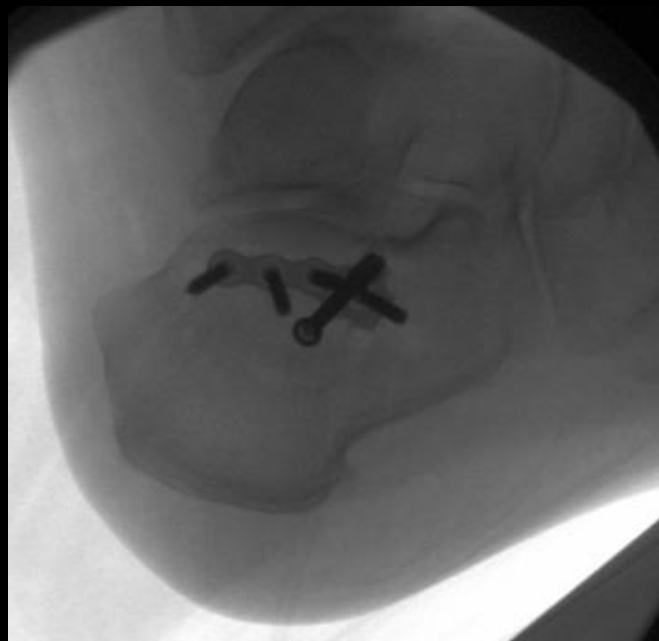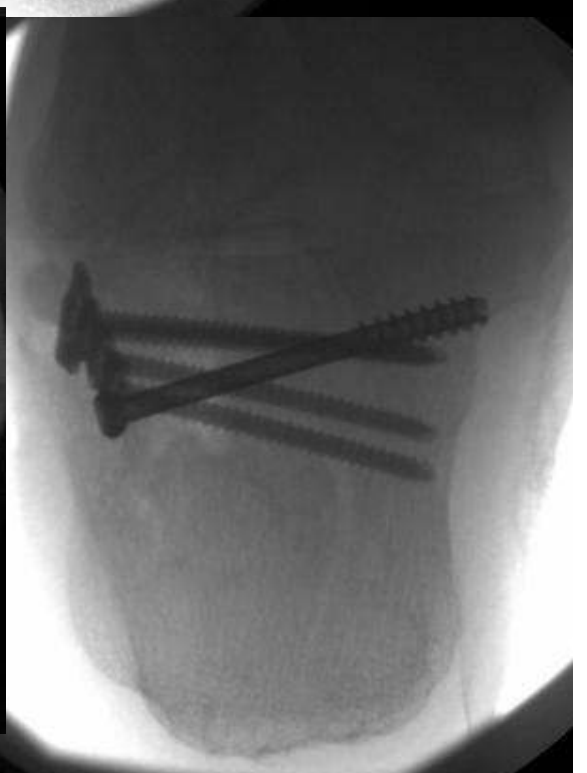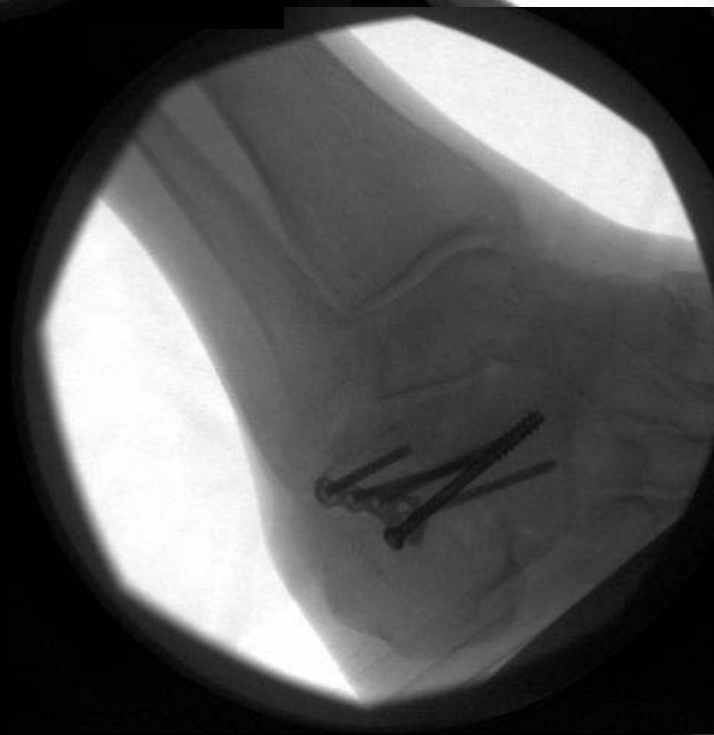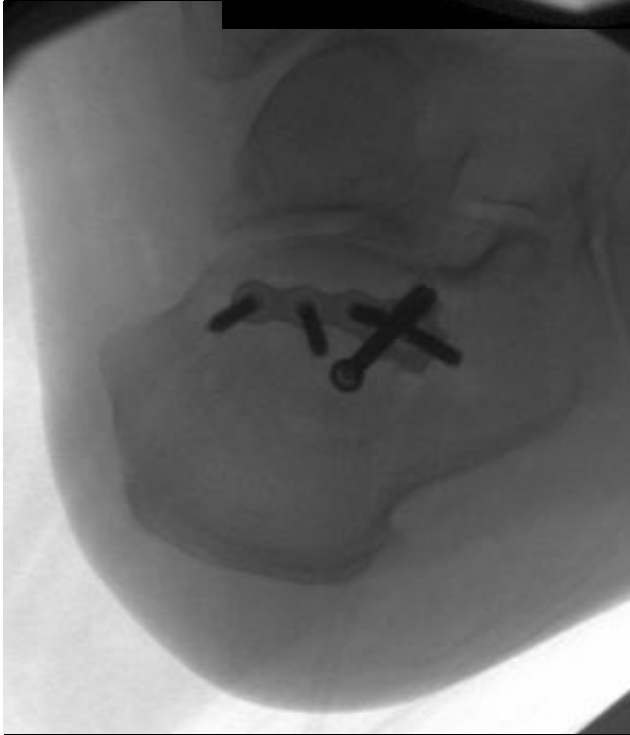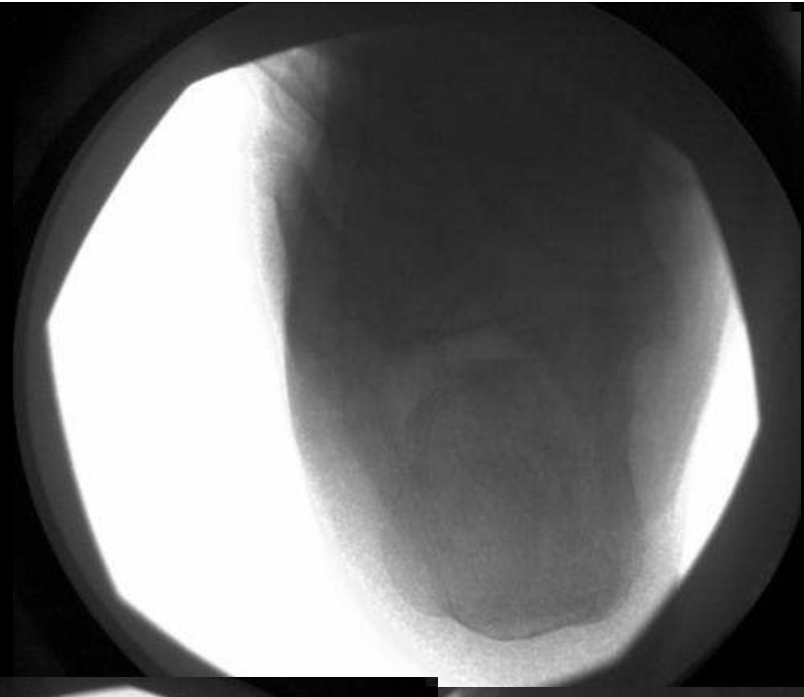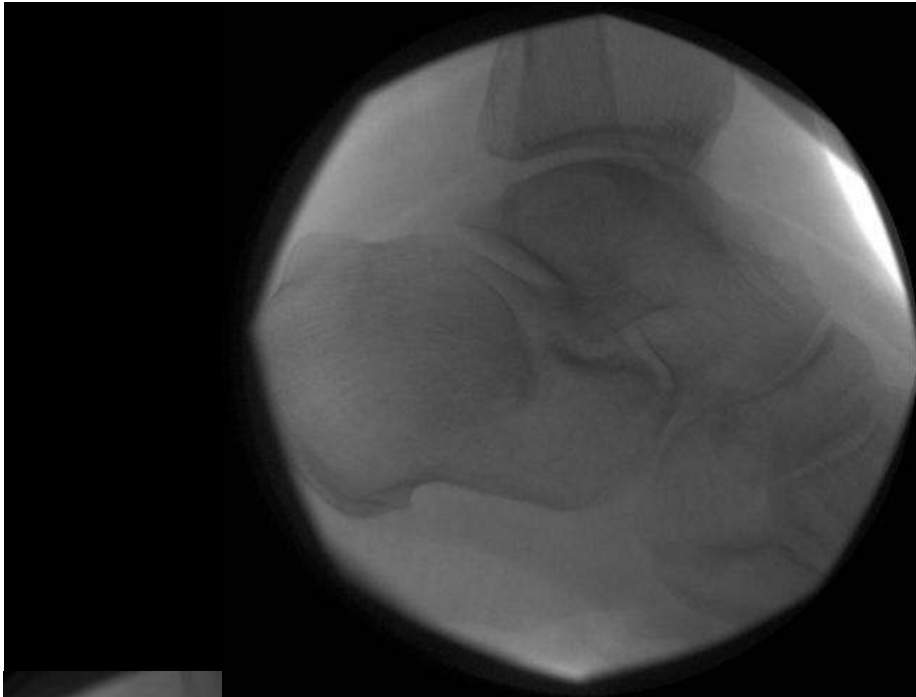




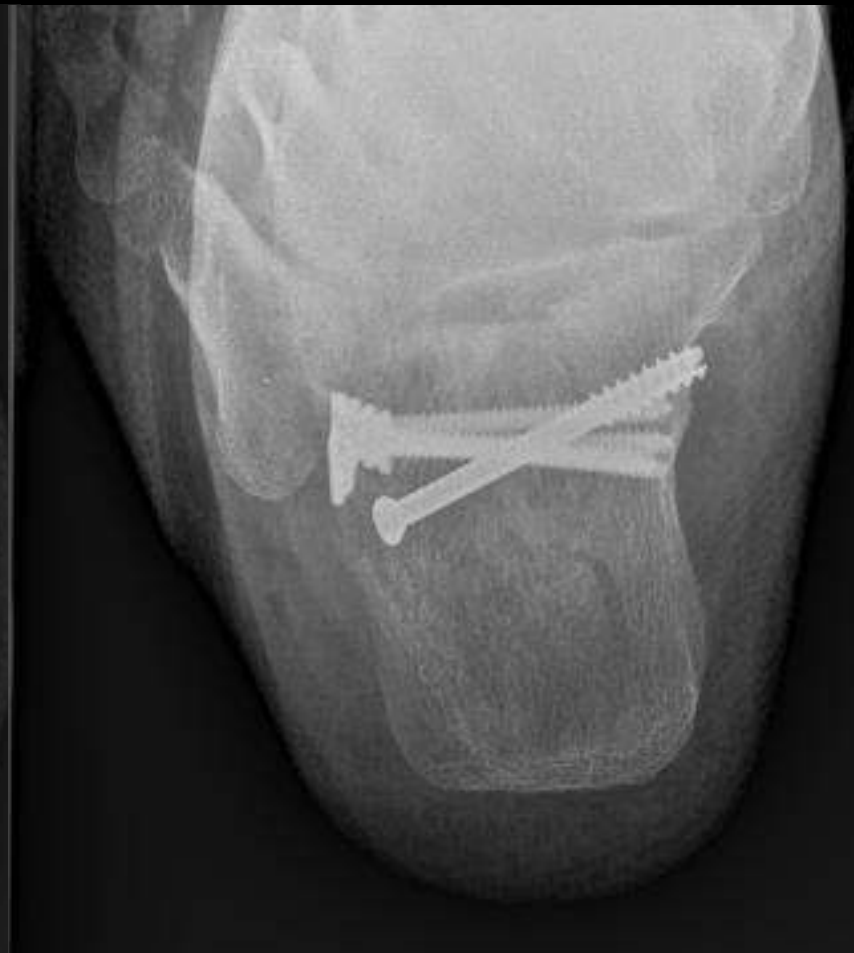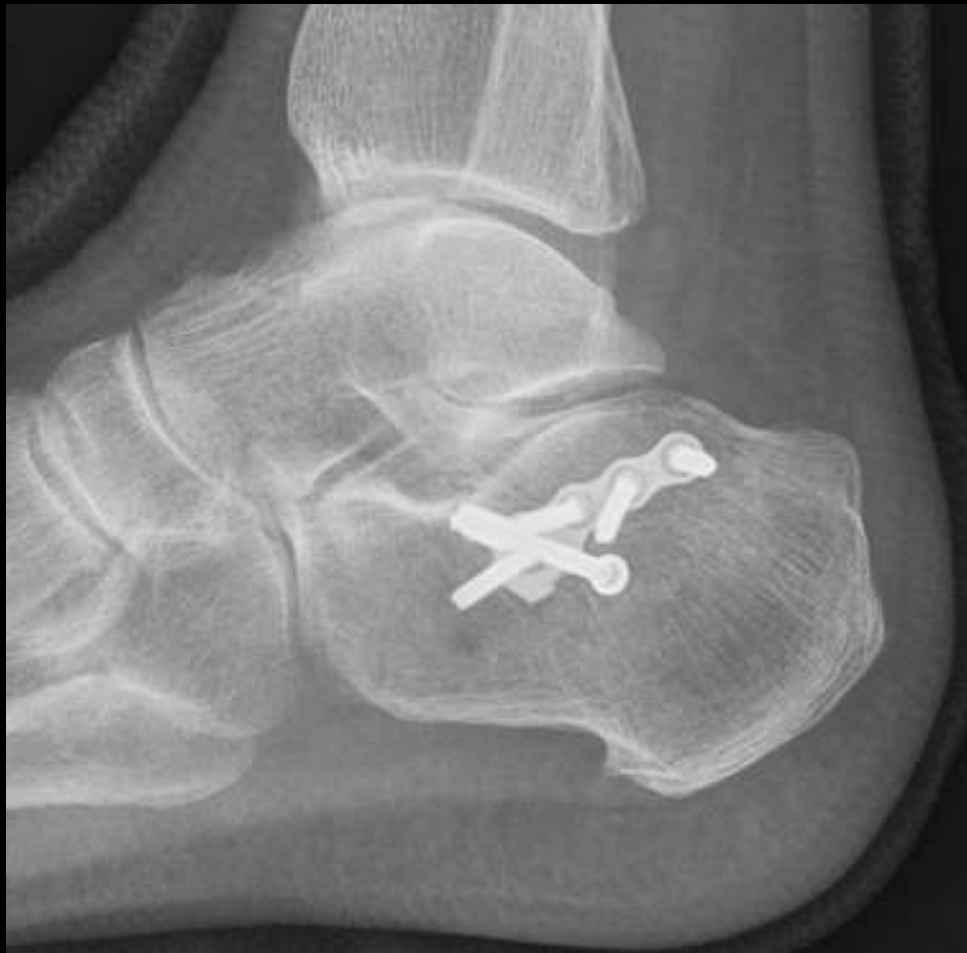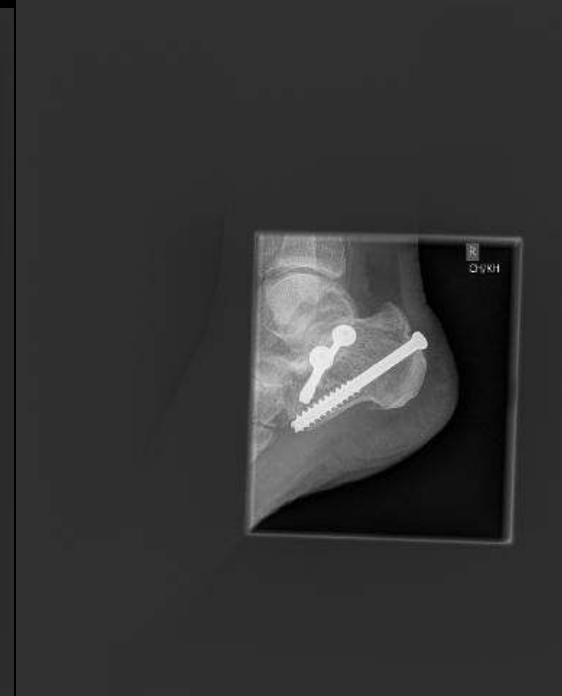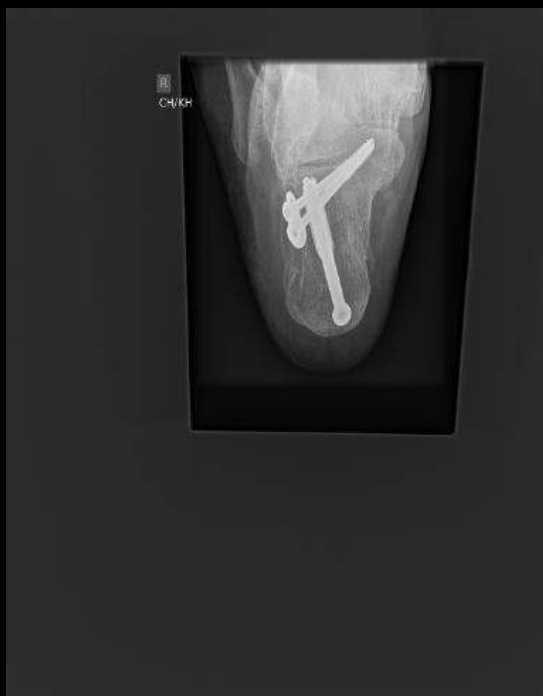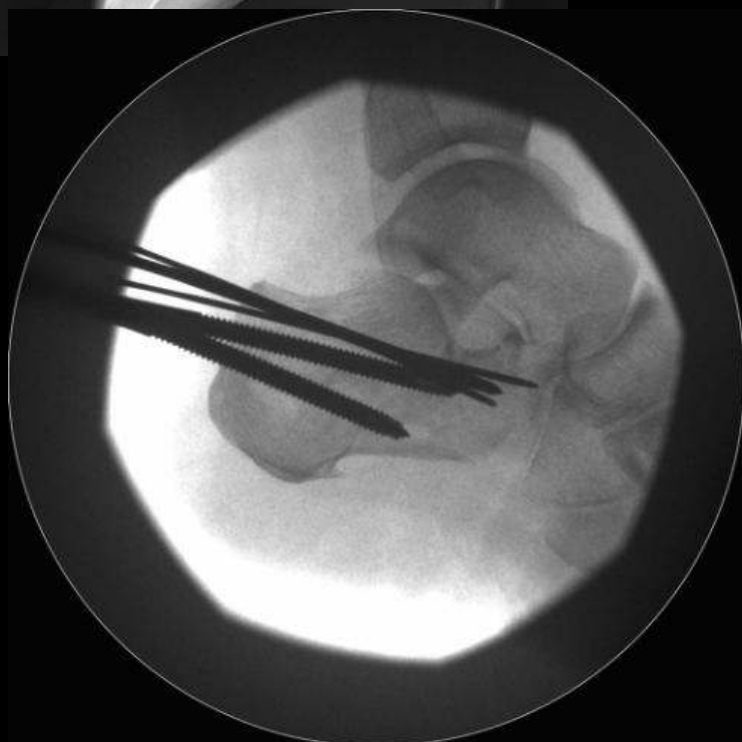






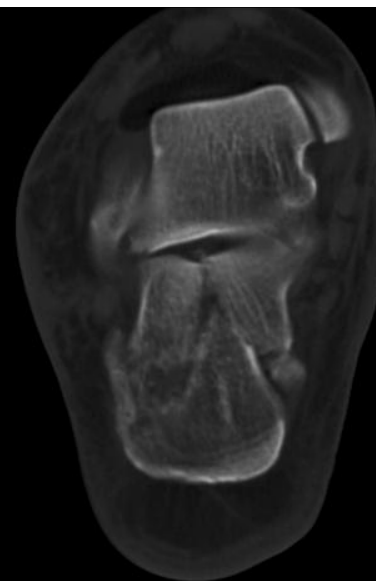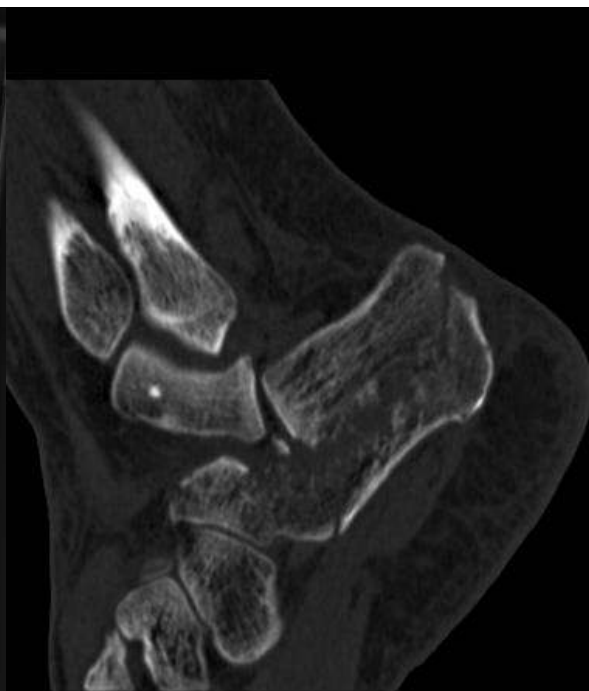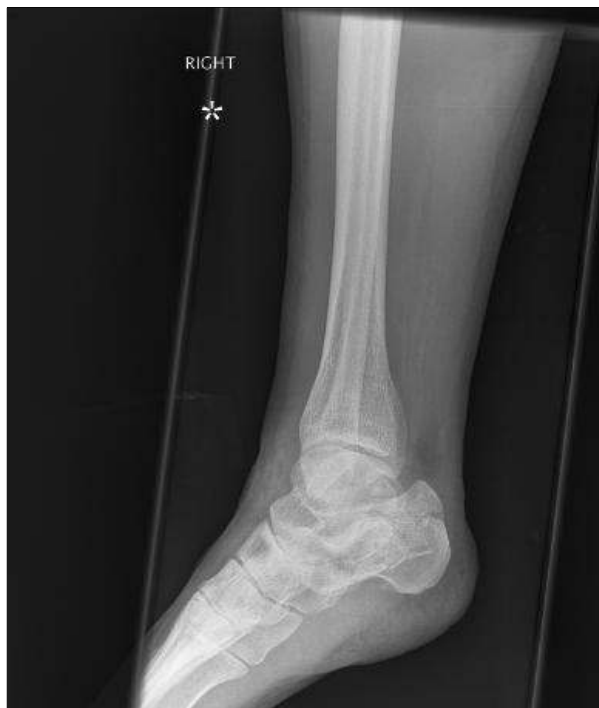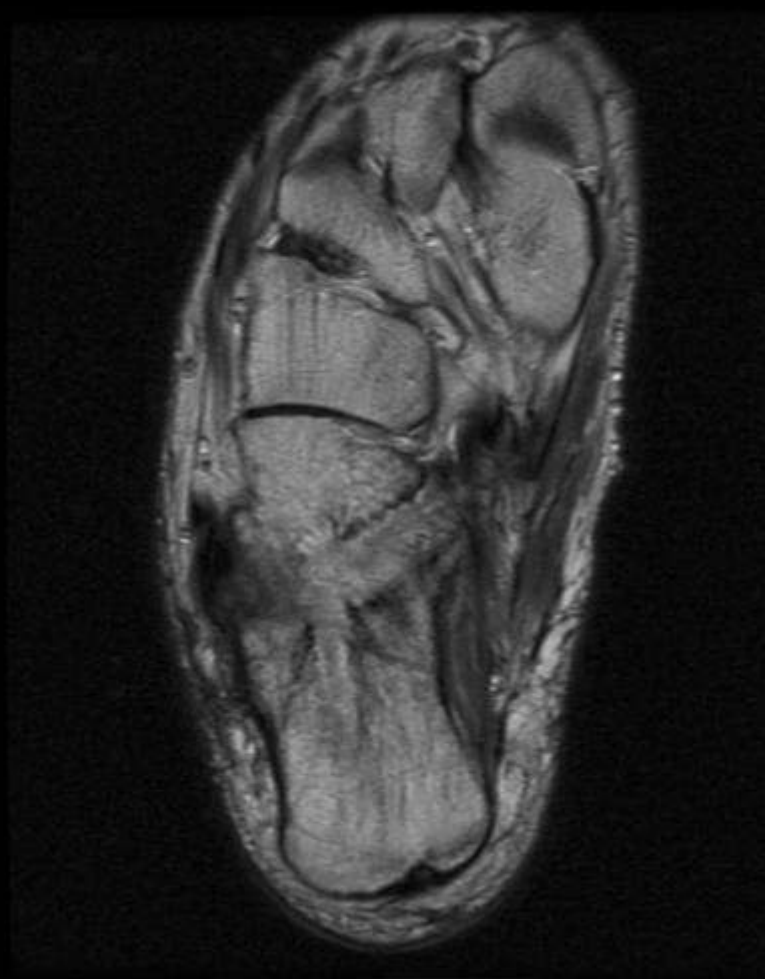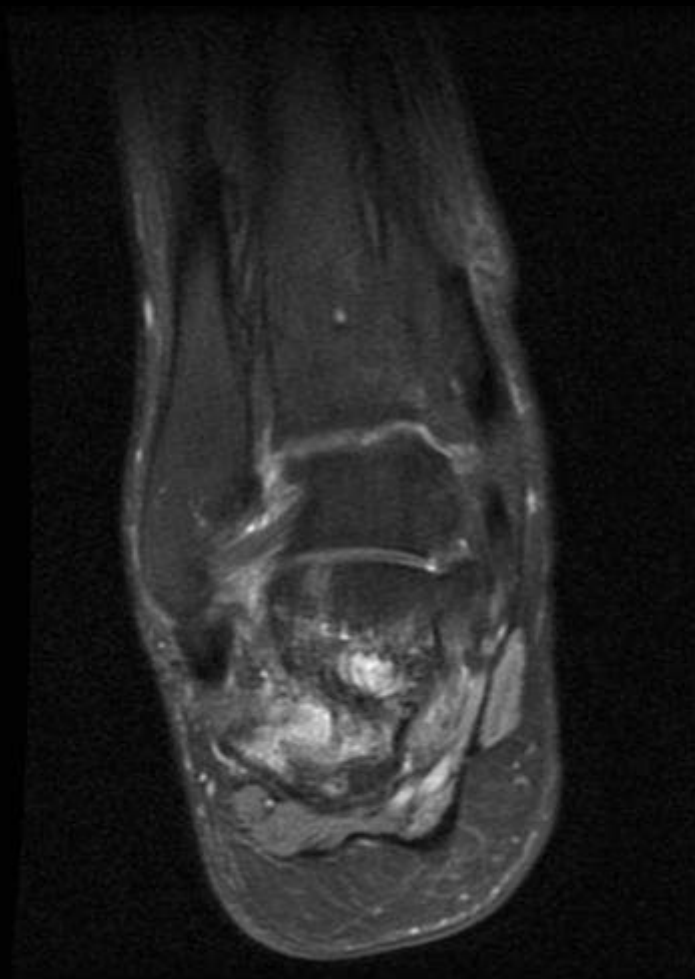


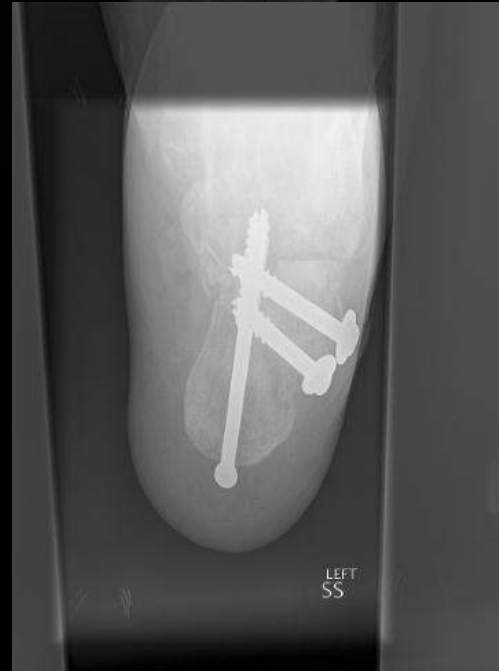




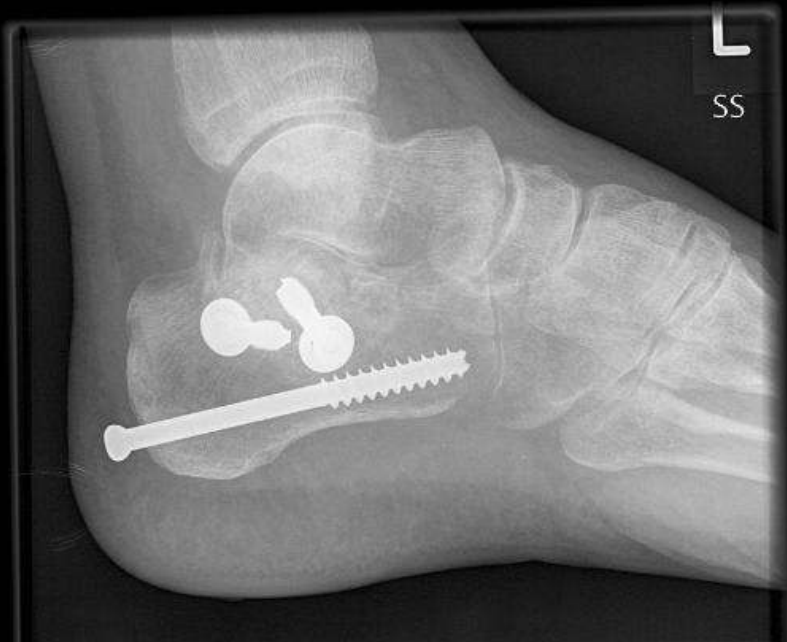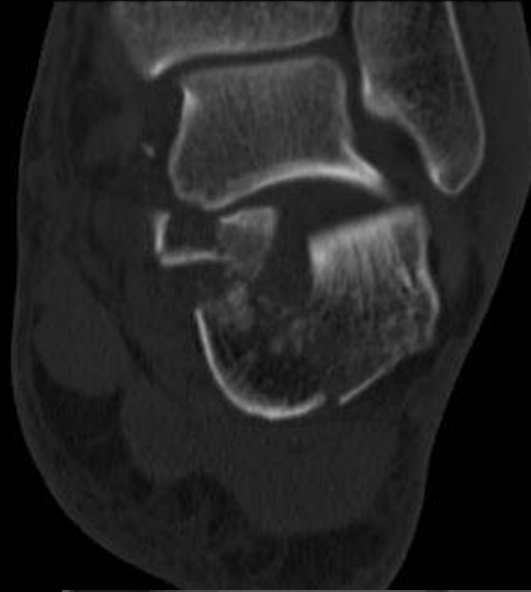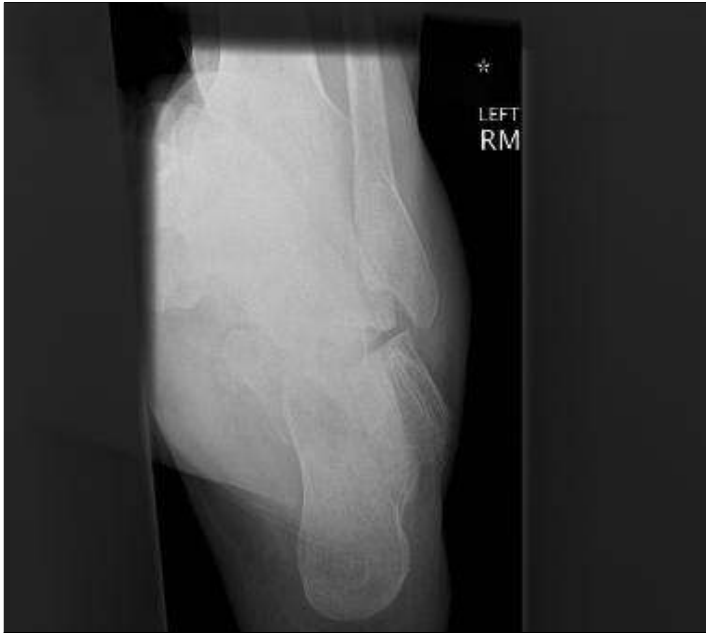Limitations

- Sustentacular fragment and medial depression
- Medial plantar Nerve
- Calcaneocuboid joint depression
- Severe injuries ?





Experience

- 13 cases
- All united
- No infections
- Reoperations : 3 (screw removals)
- Medial Plantar nerve injuries -1.5
- Sural nerve dysfunction : 1

Questions ?

