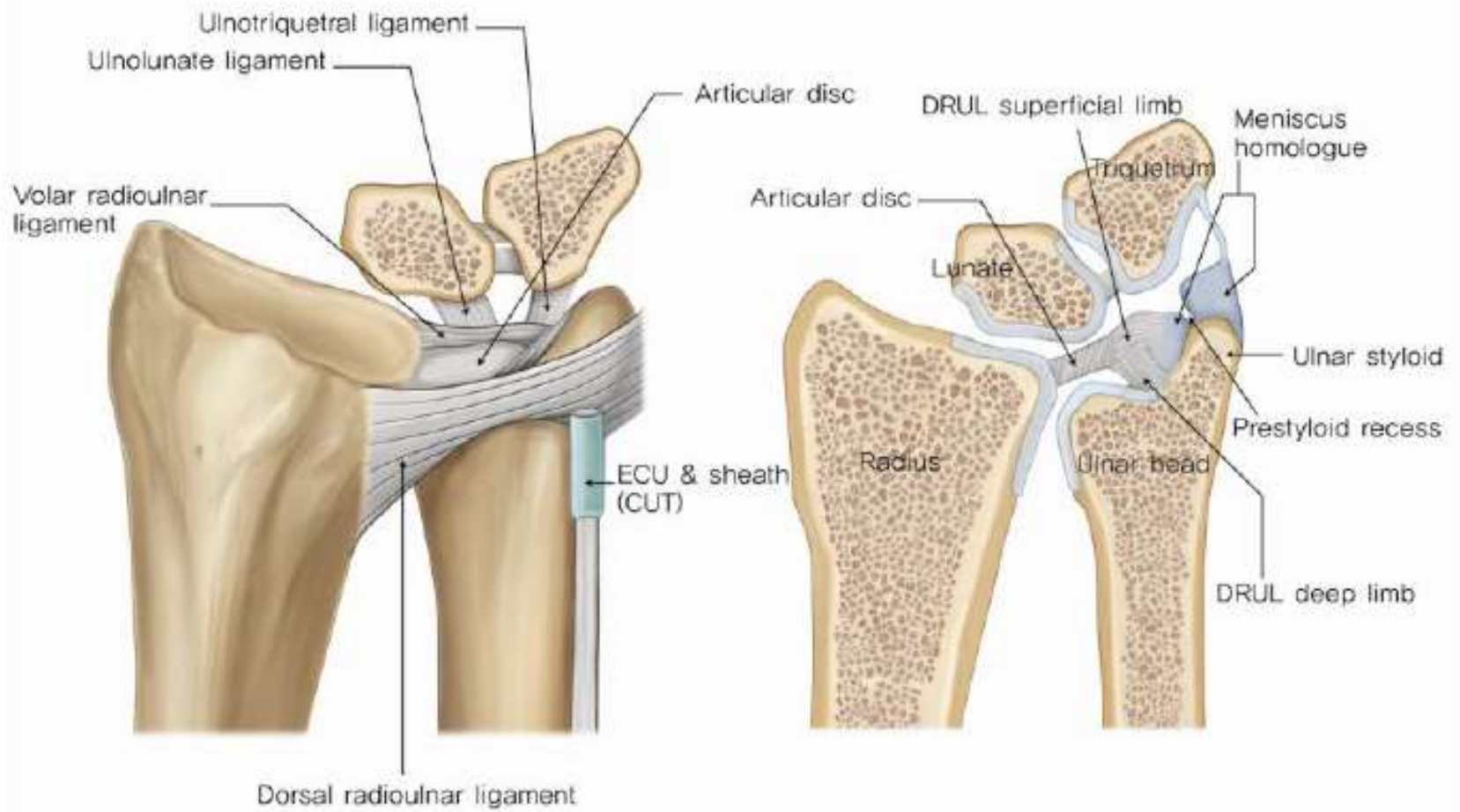




# DRUJ Instability

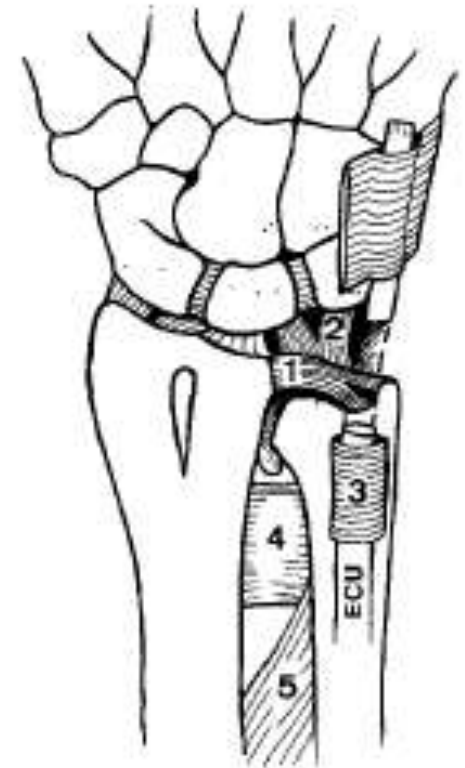
Jeff Auyeung





# DRUJ Stabilising Factors

- 1 – TFCC
- 2 – Palmar ulno-carpal ligaments
- 3 – ECU
- 4 – PQ
- 5 - IOM



# Investigation

- X-rays
- MR Arthrogram



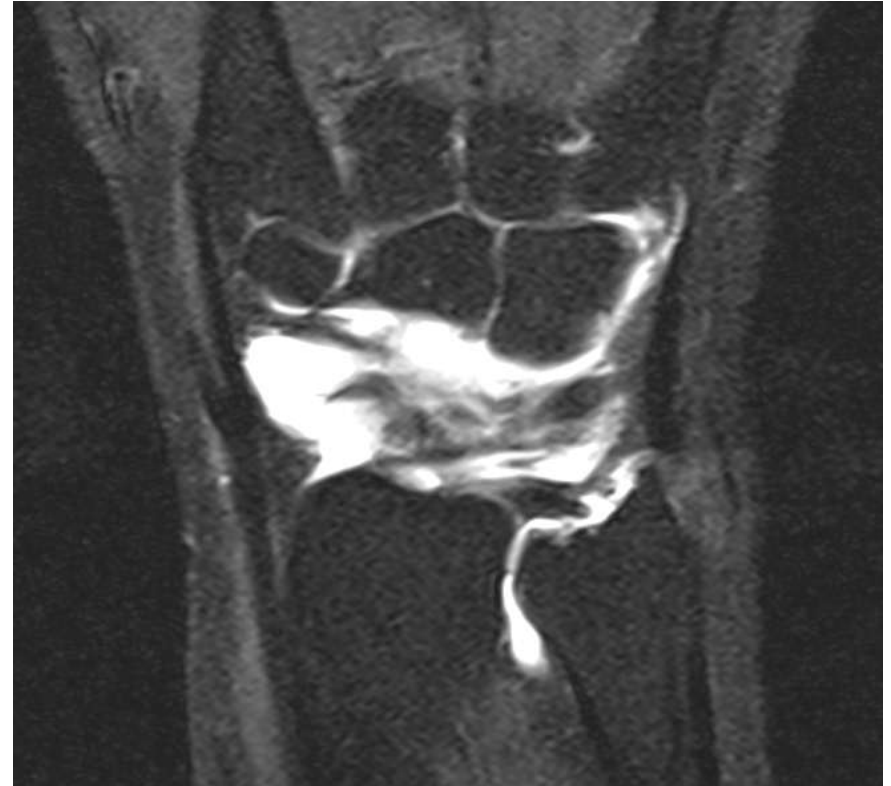# Acute ligamentous injury

- Reduce and POP AE – Sup vs Pron
- Galeazzi = fix radius
- Korompilias 2011 – 37/40 Galeazzi had residual DRUJ instability = repair TFCC acutely
- Irreducible = Open repair

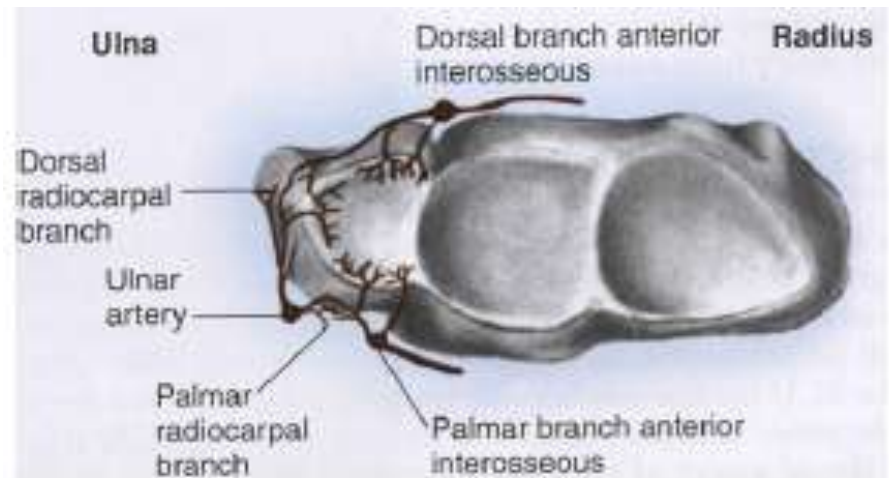


# TFCC tears

- Ulnar sided detachment
- Deep insertion more important



- Rim detachment a la menisci R/W vs W/W



# TFCC tears

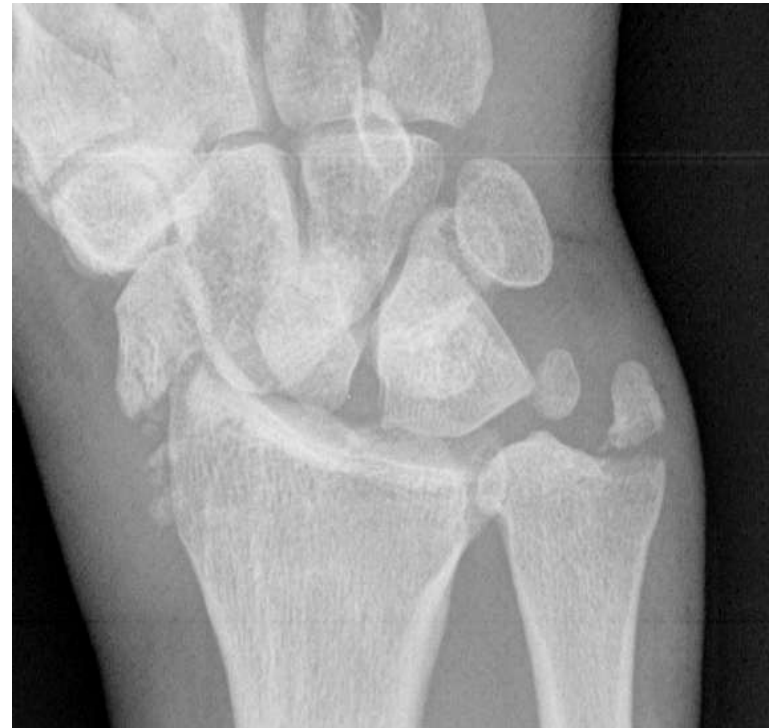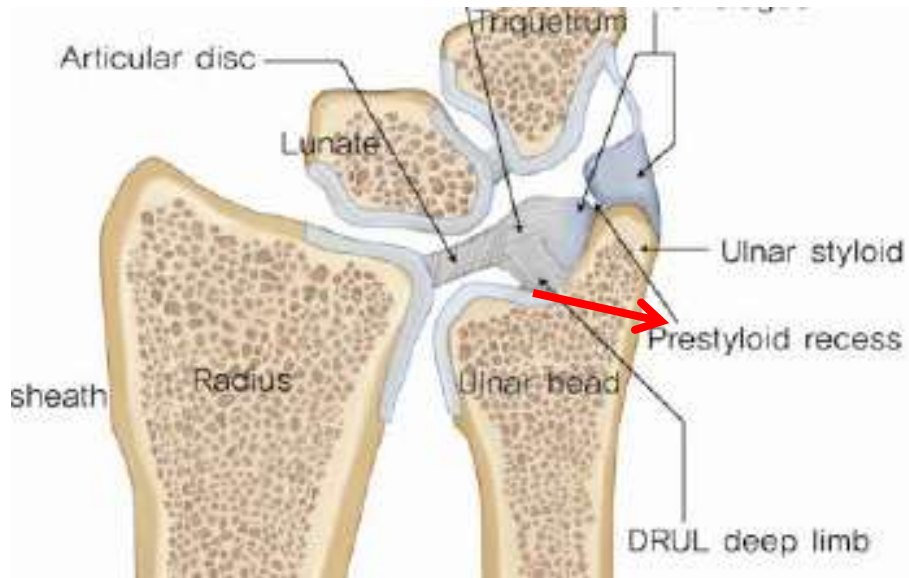
- Peripheral detachment amenable to arthroscopic repair
- Foveal detachment mainly repairable open
- Use anchor or sutures for foveal reattachments
- Chronic tears will improve after repair



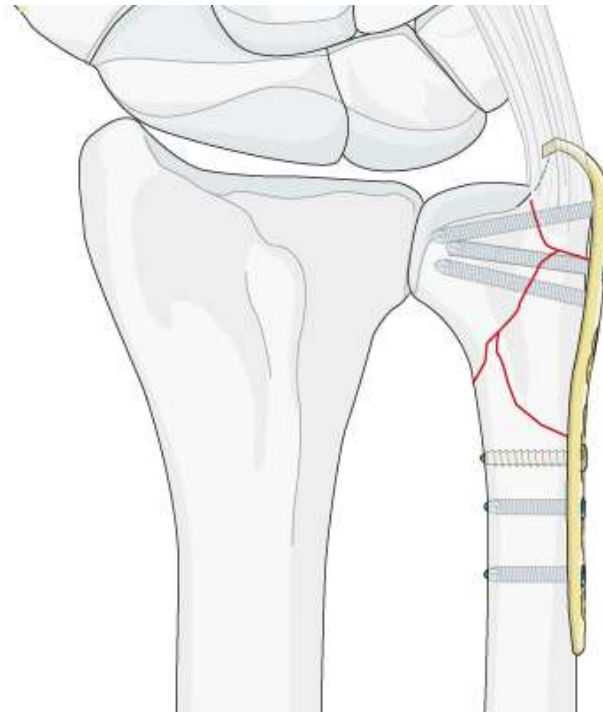
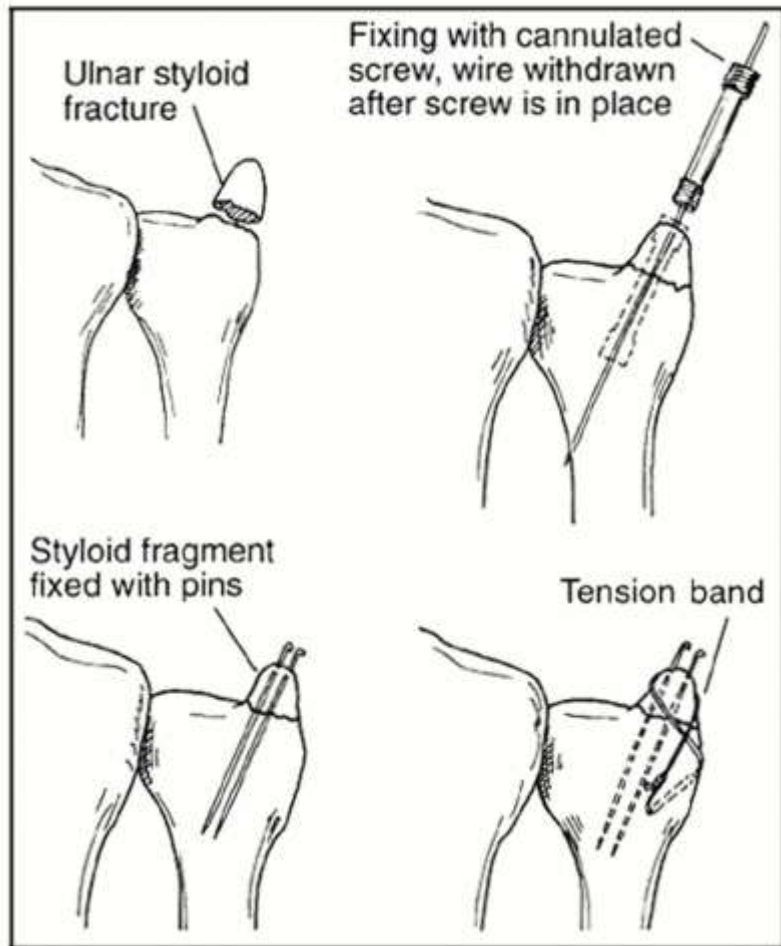
- Ruch 2003
- 13 pts with acute ulnar TFCC detachment had arthroscopic repair
- 24 months average FU
- ROM – 90% normal, 78% grip strength
- DASH 13 average



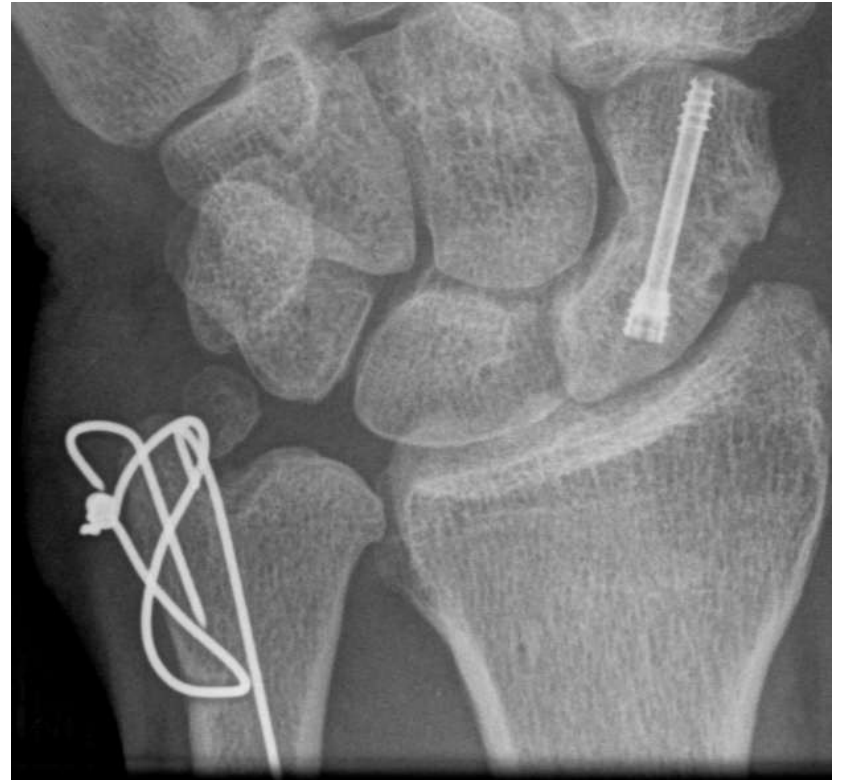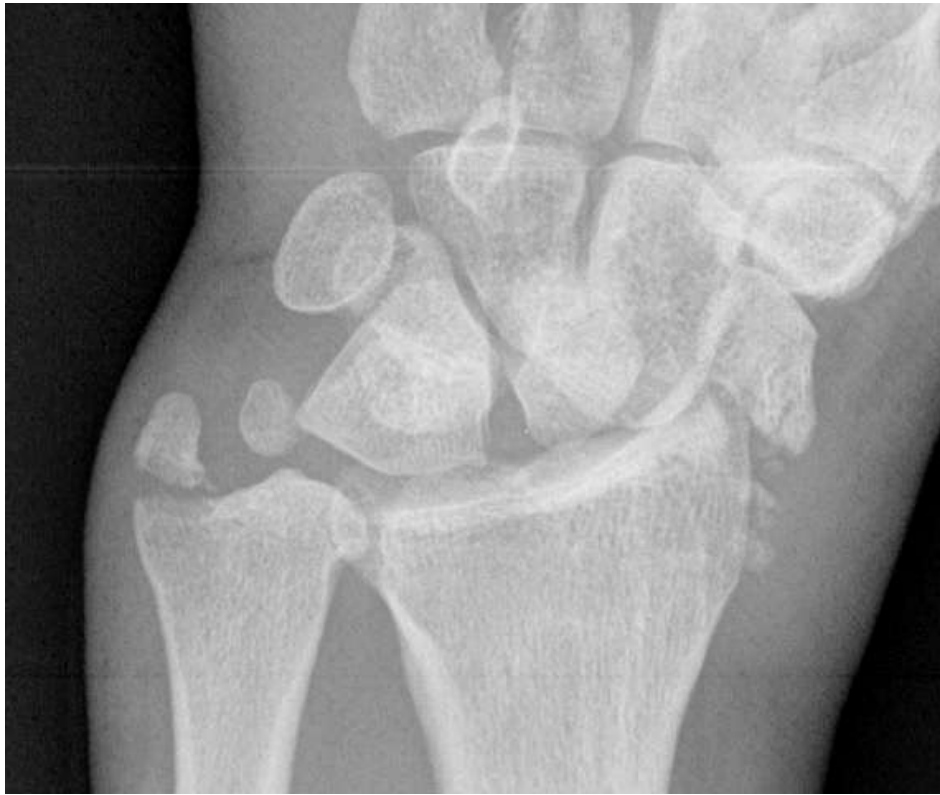# Ulnar styloid #



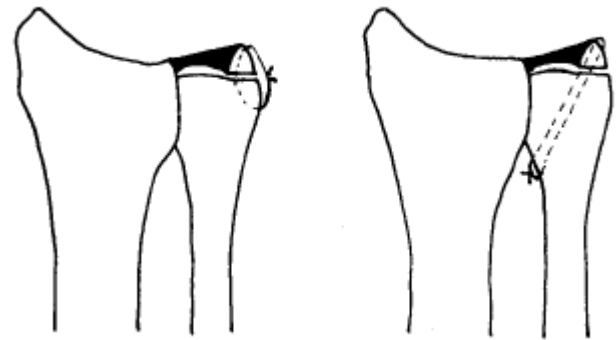
# Ulnar styloid #



# Ulnar styloid #



- Mikic 1995
- 130 pts in total – 73% Excellent, 23% Good, 4% Poor
- 13 pts with ORIF ulnar styloid # and DRUJ instability



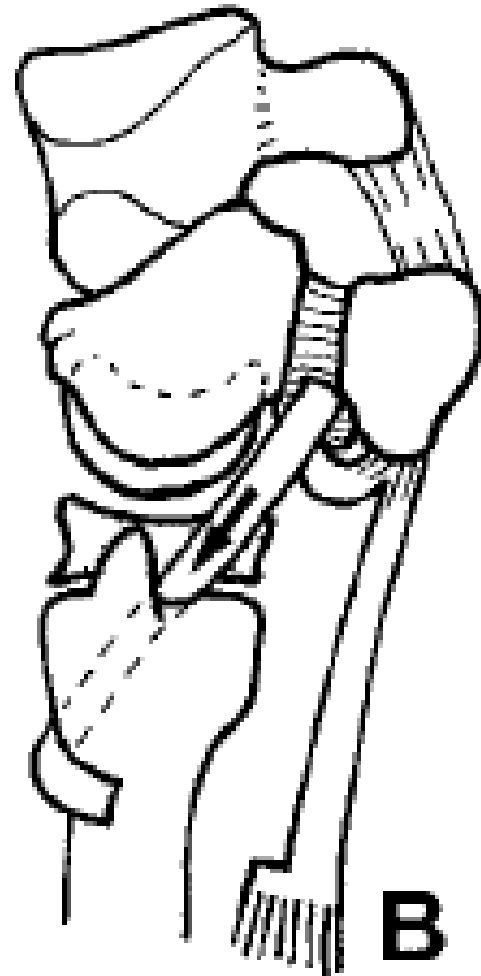
# TFCC reconstruction

- Chronic TFCC tears with DRUJ Instability
- Restores stability of joint
- Need graft – Palmaris longus, Plantaris, Toe long extensors
- Various techniques
- Sugar Tong cast post op

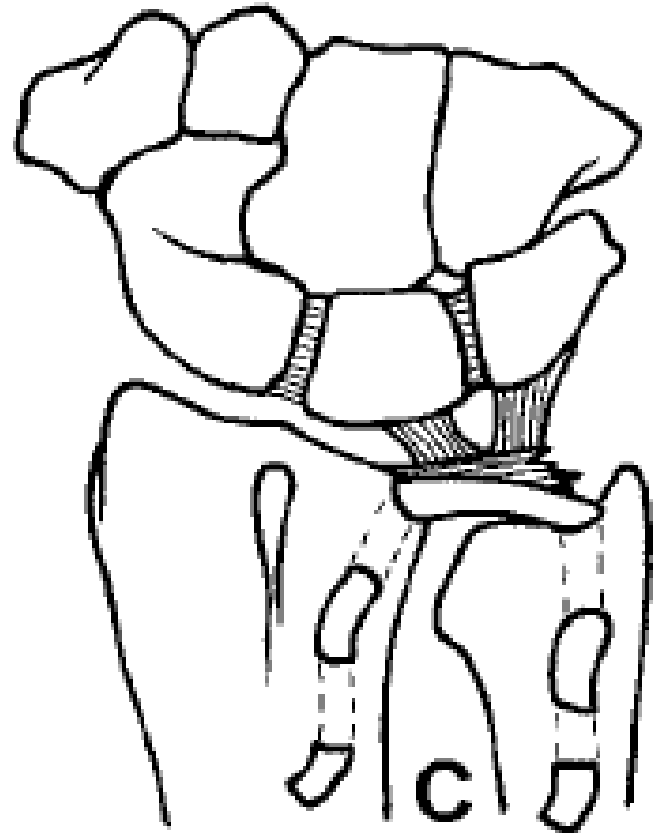


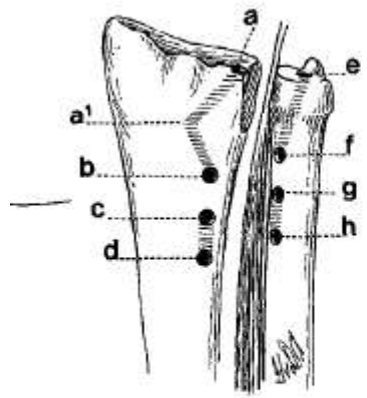
# TFCC reconstruction

- Hui and Linscheid 1982
- 8 pts with isolated dorsal DRUJ instability
- All had improved stability
- 5 complete and 3 satisfactory pain relief

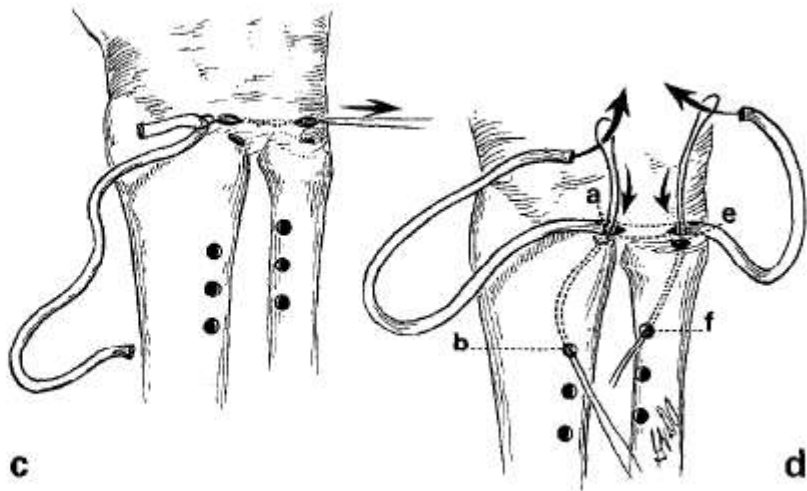


- Scheker 1994
- 14 pts
- Average 18 mths FU
- 12 pts complete resolution of pain
- 2 c/o with heavy lifting
- Grip 37 lb to 65lb



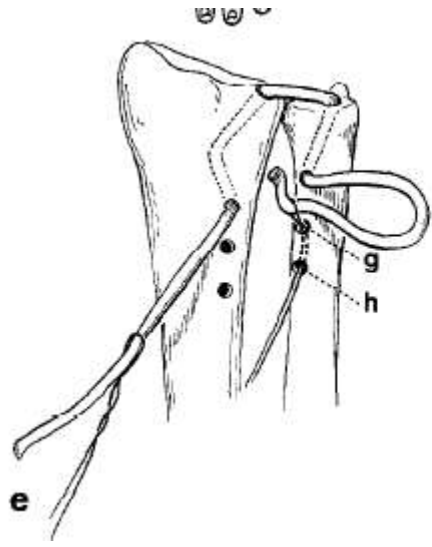


b

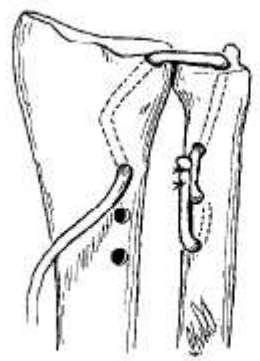


c

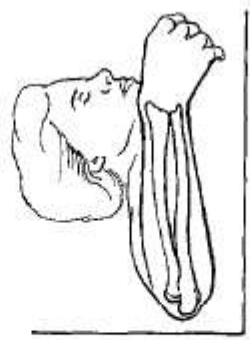
d



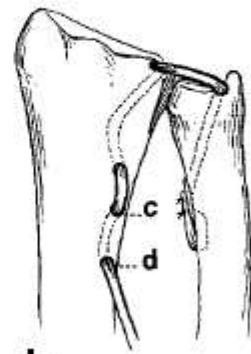
e



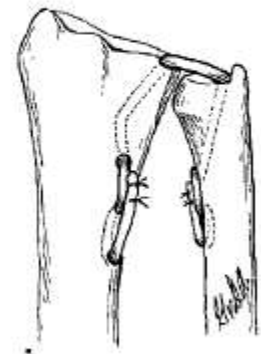
f



g



h

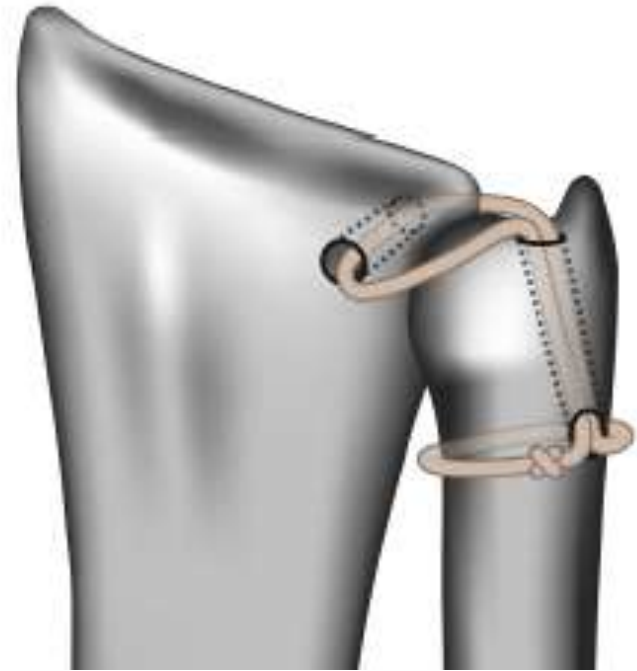


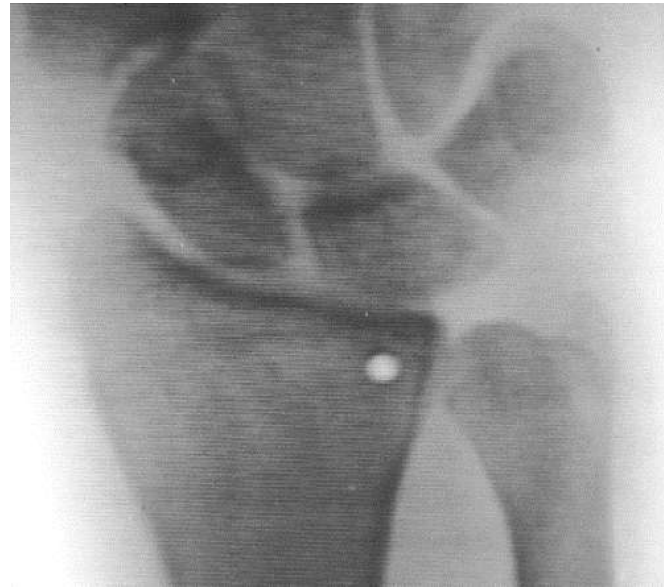
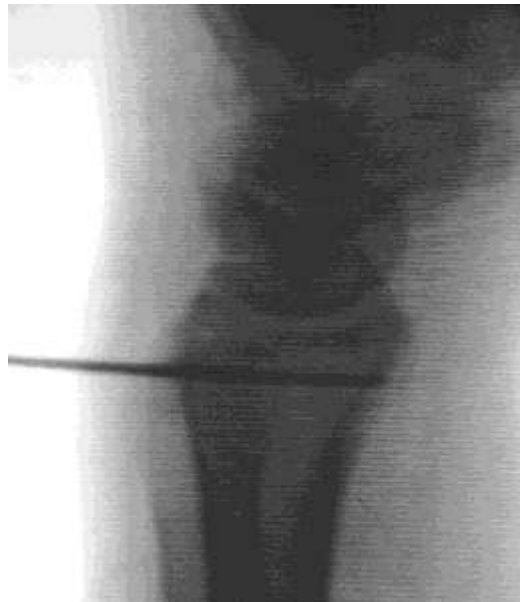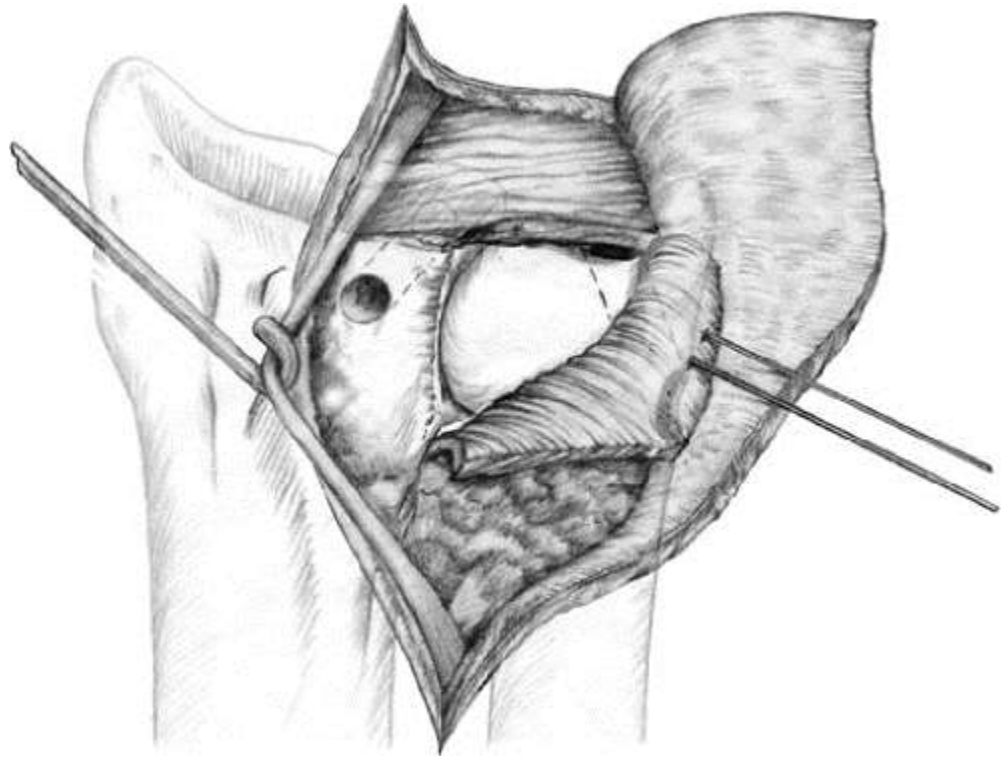
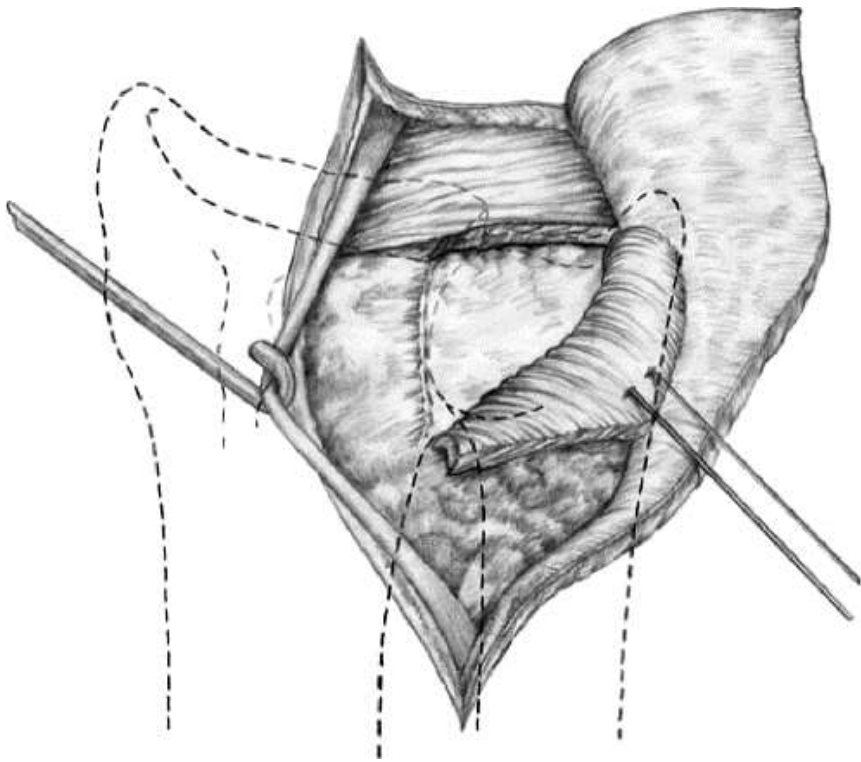
i

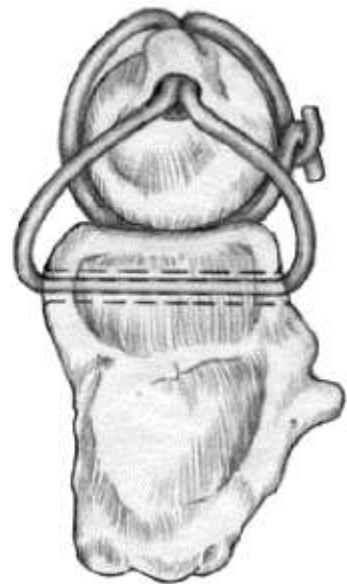
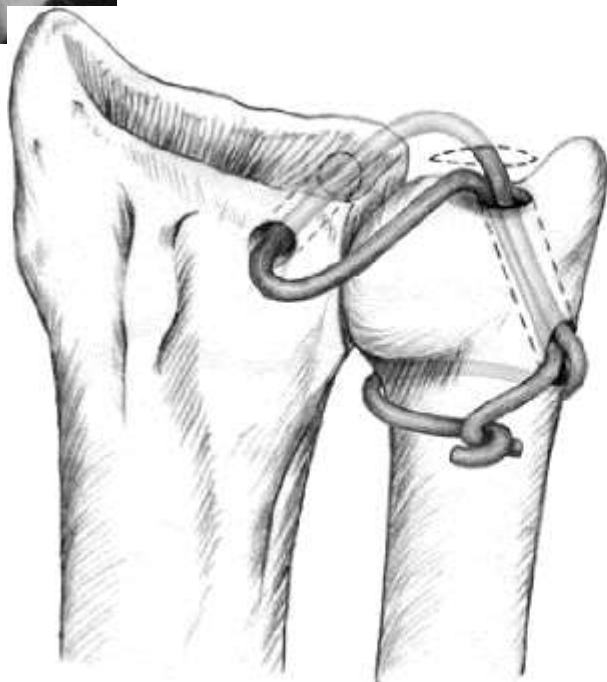
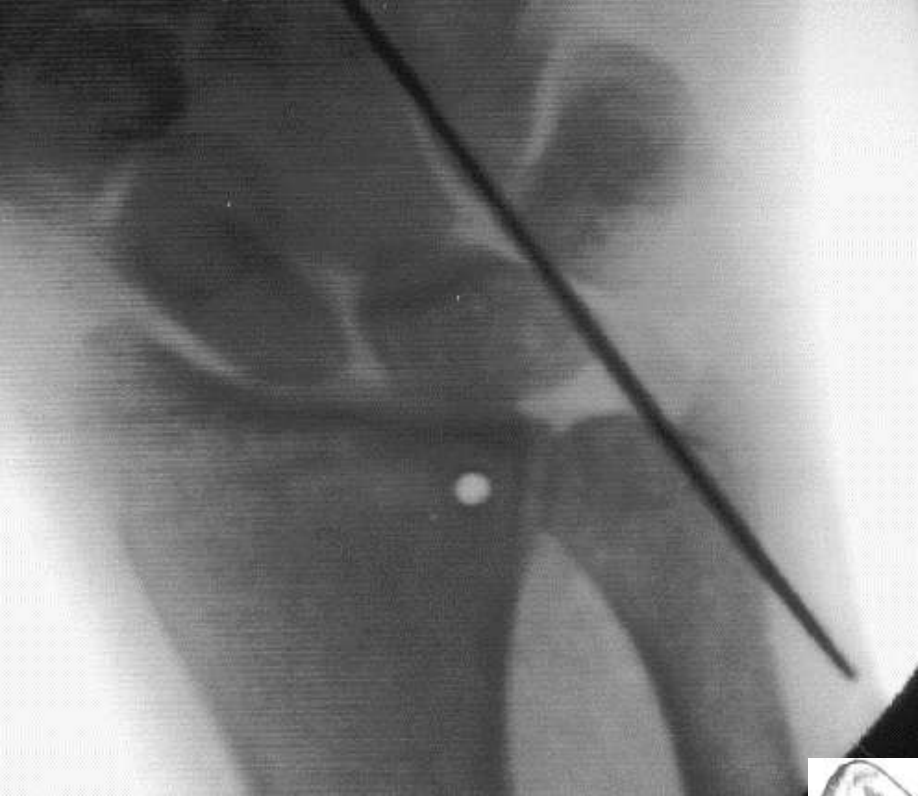

# TFCC reconstruction

- Adam's 2002
- 12/14 DRUJ stable at follow up
- These return to previous work
- All FROM
- Grip strength 84%
- 2 had temporary paraesthesia



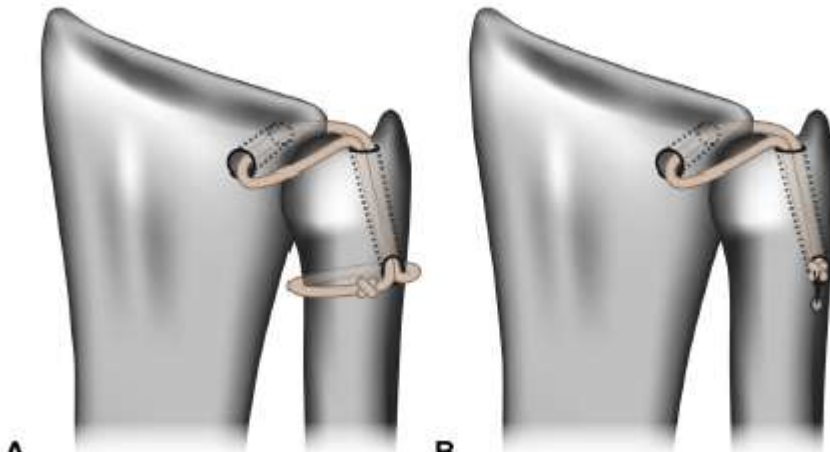




# Selection of Tendon Grafts for Distal Radioulnar Ligament Reconstruction and Report of a Modified Technique

(*J Hand Surg Am.* 2014;39(10):2027–2032.

Eugene Jang, MS, Christopher J. Dy, MD, MPH, Scott W. Wolfe, MD

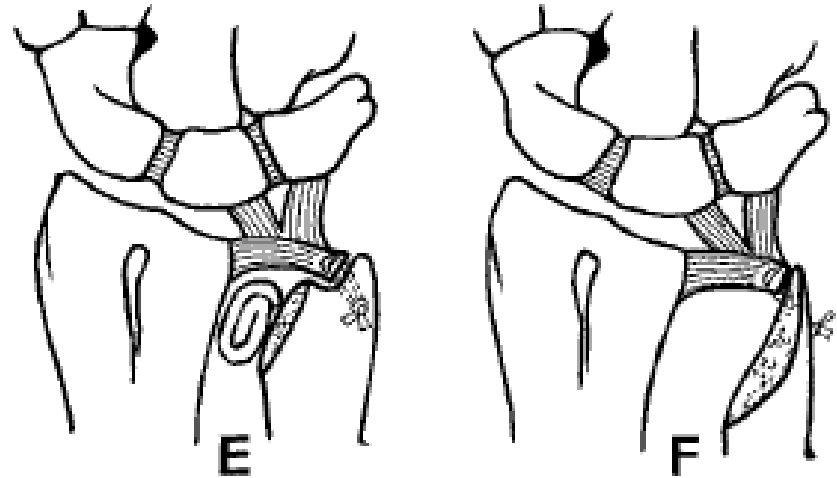


Measurement	Average Length	% Specimens Sufficient for Original Technique	% Specimens Sufficient for Modified Technique
Palmaris longus	127 ± 20 mm	43	86
Extensor indicis proprius	100 ± 25 mm	0	86
Slip of extensor digiti minimi	112 ± 23 mm	29	57
Portion of flexor carpi radialis	87 ± 16 mm	0	57
Portion of extensor carpi ulnaris	67 ± 22 mm	0	29
Portion of flexor carpi ulnaris	67 ± 17 mm	0	14
Slip of abductor pollicis longus	69 ± 18 mm	0	0
DRUL reconstruction (original)	138 ± 36 mm	—	—
DRUL reconstruction (modified)	89 ± 20 mm	—	—



# TFCC reconstruction

- Bower's hemiarthroplasty
- "Matched ulna" procedures
- Degenerate DRUJ



# Persistent instability

- Scheker implant



# One bone forearm

- First describe by Hey Groves 1921
- Failed stabilisation/replacement
- Fuse between neutral and pronation
- Various techniques



# Clinical Results of the One-Bone Forearm

(J Hand Surg 1995;20A:609-618.)

Charles A. Peterson II, MD, Rochester, MN, Shinya Maki, MD, Kagoshima, Japan, Michael B. Wood, MD, Rochester, MN

- 19 pts
- 13 Trauma and 6 post tumour resection
- Trauma pt poorer results via homemade score

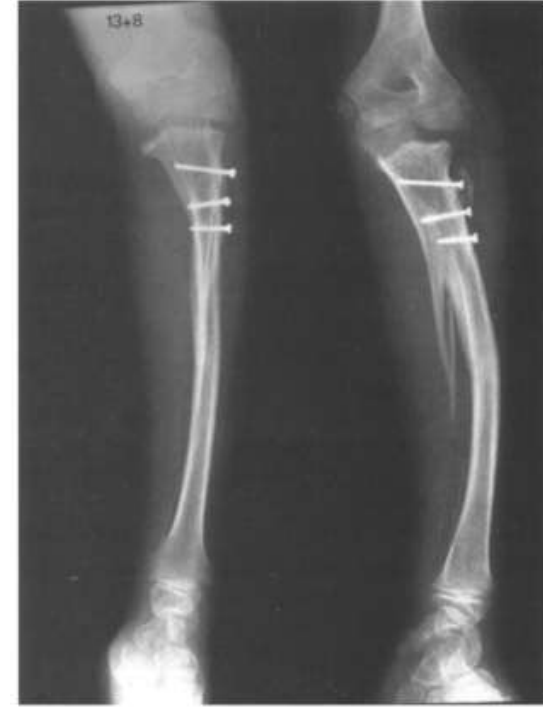

Figure 2. One-bone forearm construct with synostosis




Figure 3. One-bone forearm construct with free, vascularized bone grafting

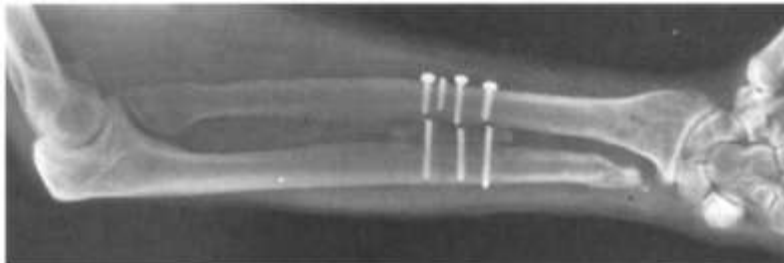


Figure 4. This fixation failure required revisional internal fixation to attain union.



# Salvage of Failed Distal Radioulnar Joint Reconstruction

Adam C. Watts, FRCS (Tr and Ortho)\*,  
Michael J. Hayton, FRCS (Tr and Ortho), FFSEM(UK),  
John K. Stanley, FRCS, FRCSEd

Hand Clin 26 (2010) 529-541

