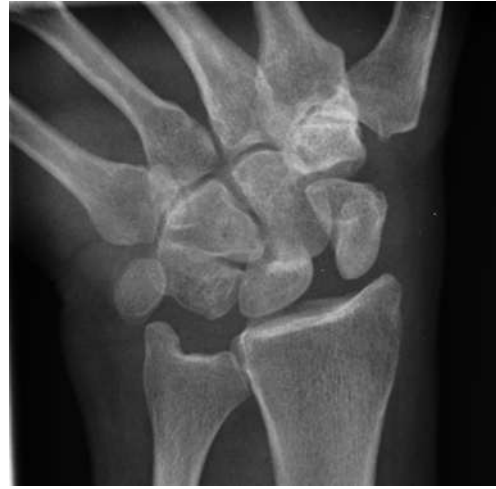



CARPAL INSTABILITY

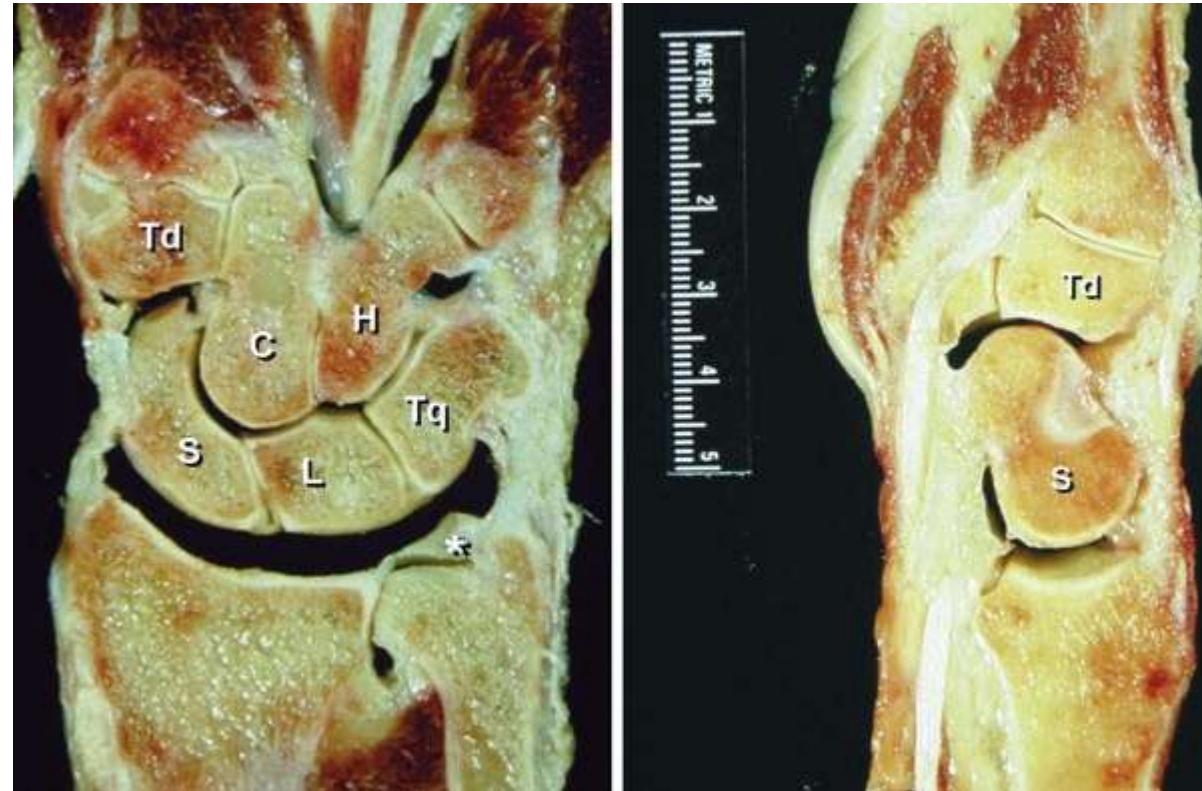*Soham Gangopadhyay
Consultant Hand Surgeon
South Tyneside Hospital*

ST Teaching HAND TERM – 4 July 2016

WRIST BIOMECHANICS

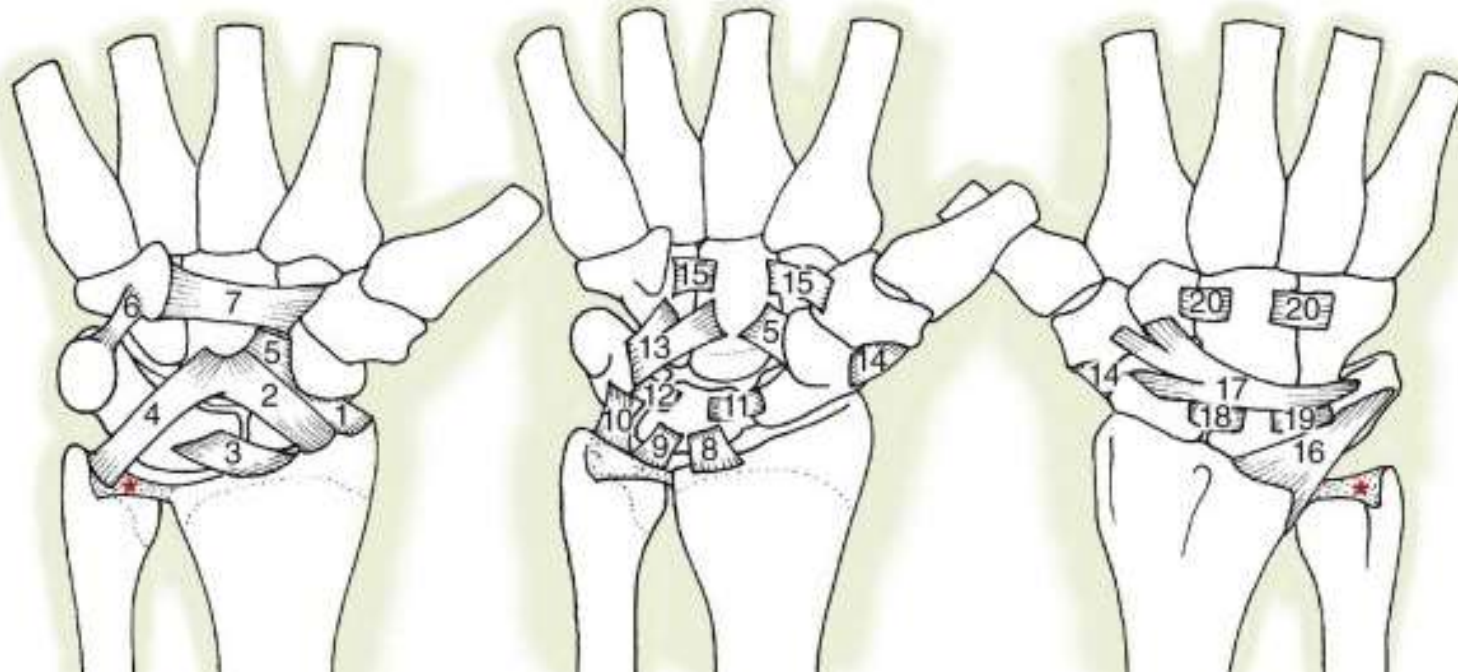
Wrist – Osseous Anatomy

- Radio-carpal
- Intercalated proximal row
- Mid-carpal



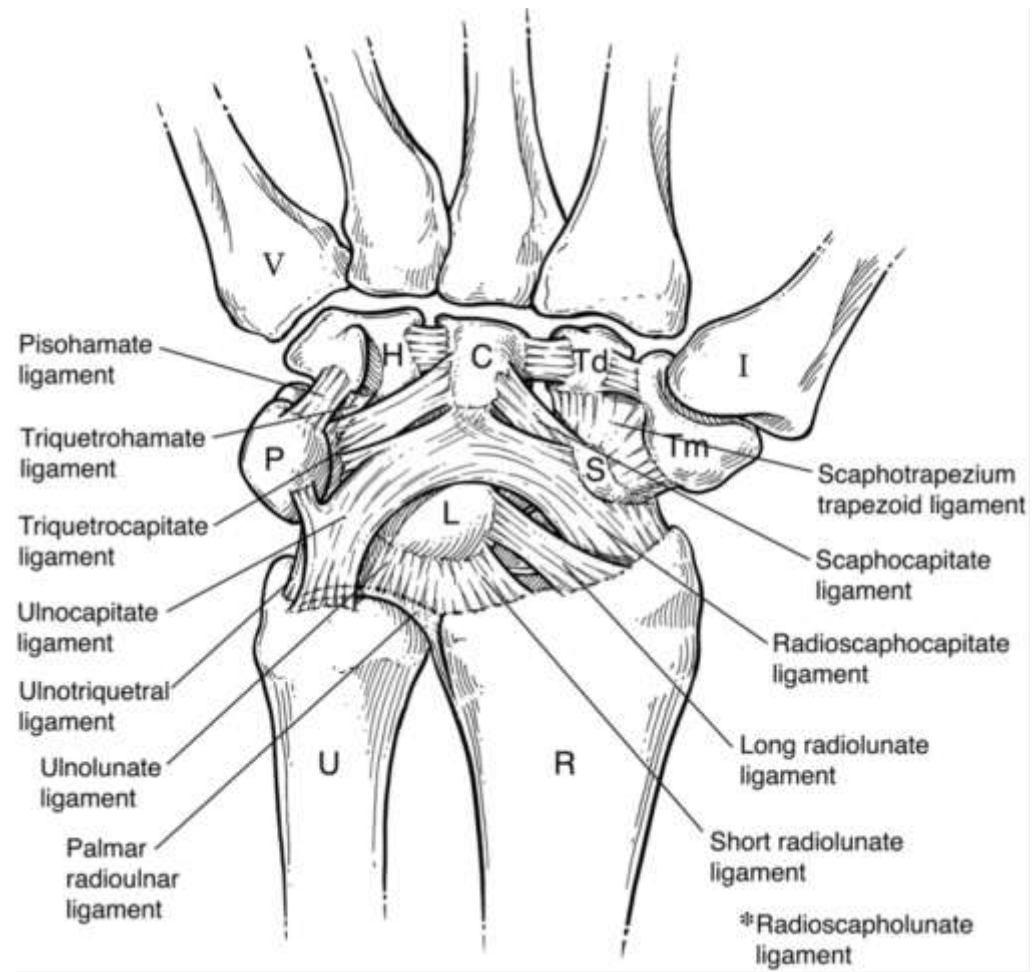
Wrist - Ligamentous Anatomy

- Intra-capsular/ Intra-articular (exceptions)
- Extrinsic
- Intrinsic



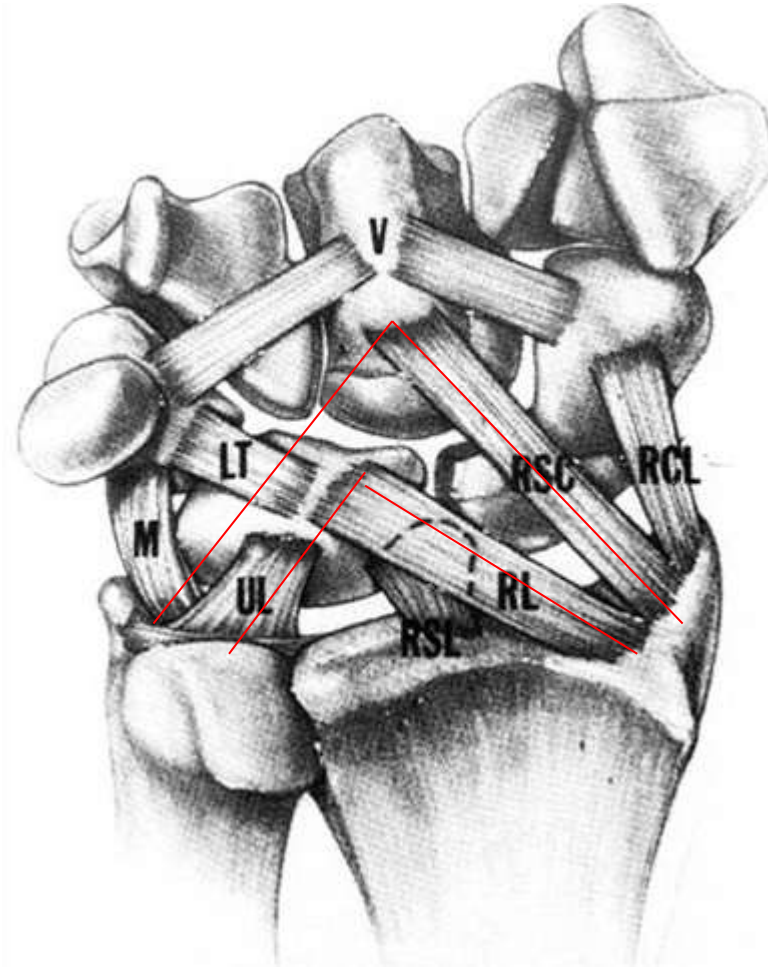
Extrinsic Ligaments

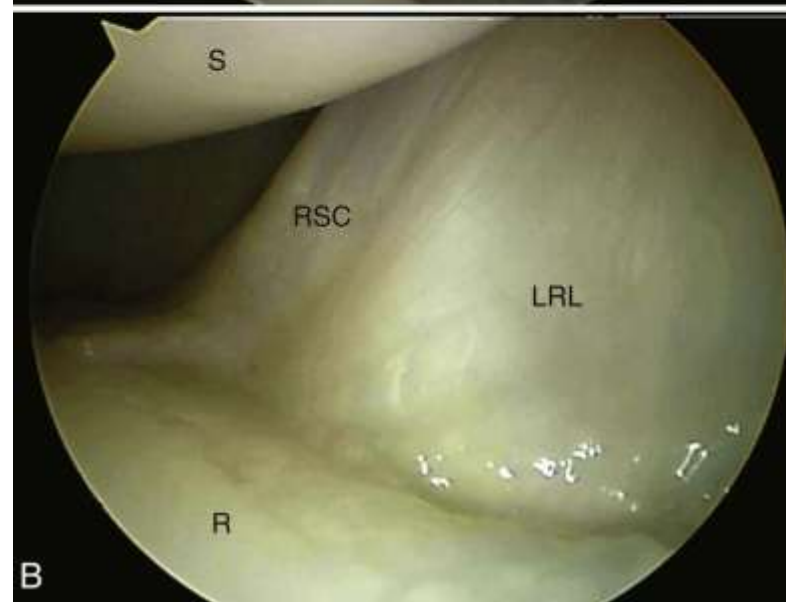
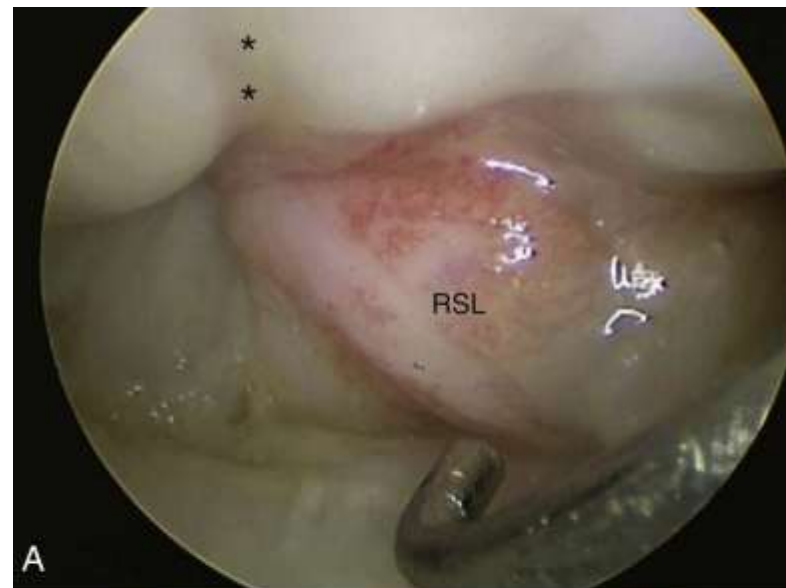
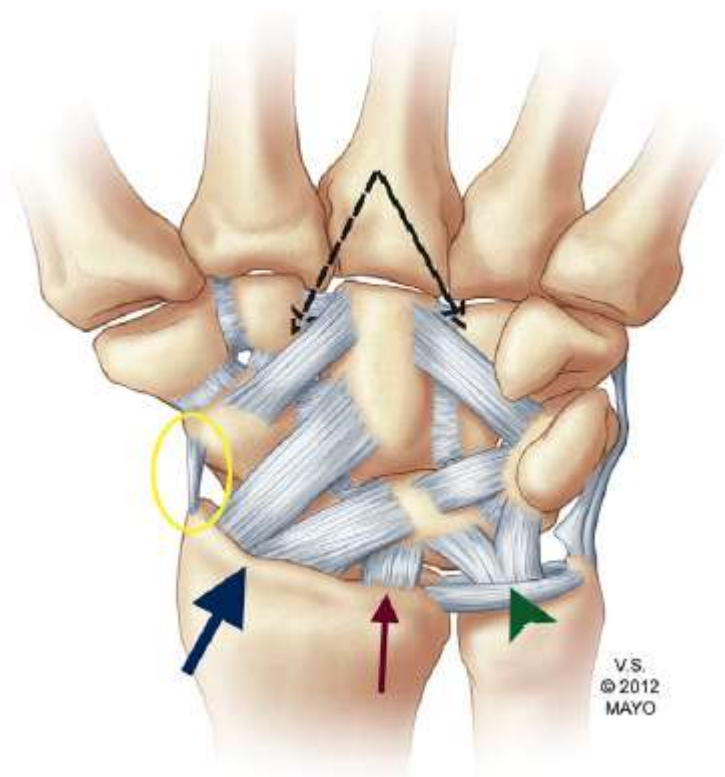
- Palmar
 - RSC
 - Long RL
 - Short RL
 - RSL
- Ulnocapitate
- Ulnolunate
- Ulnotriquetral



Space of Porier

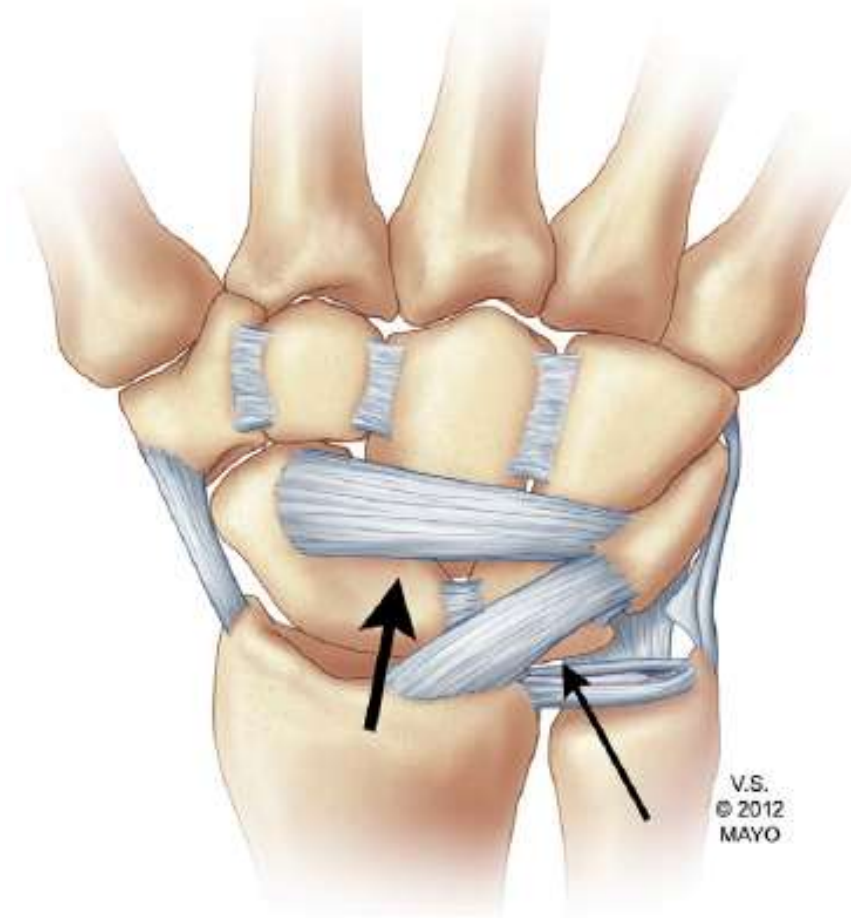
- Between RSC and LRL
- Floor of Carpal Tunnel
- Head of Capitate
- Increases with DF
- Weak spot
- Perilunate/lunate dislocations





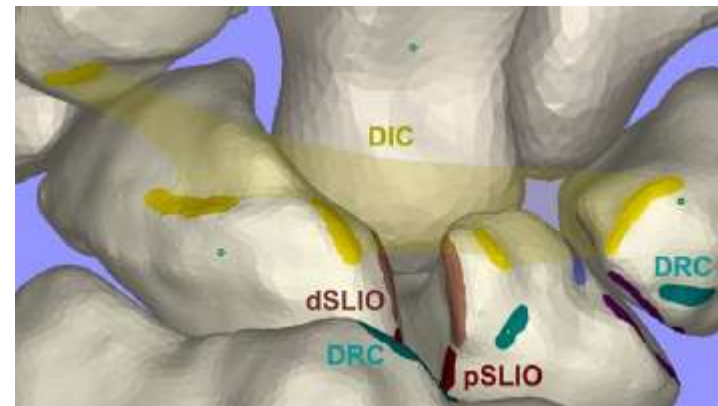
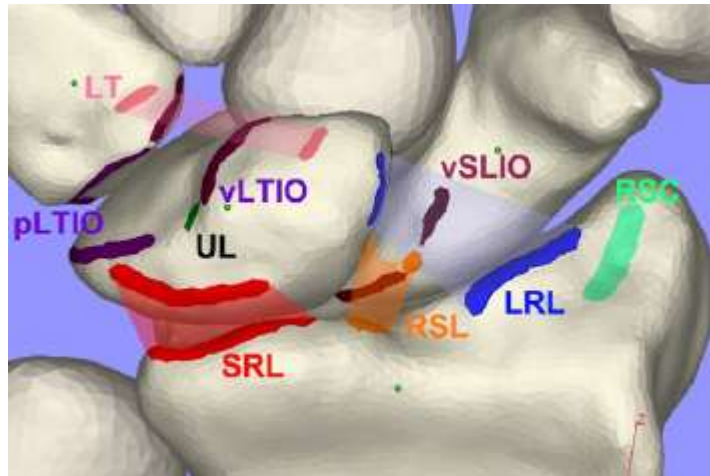
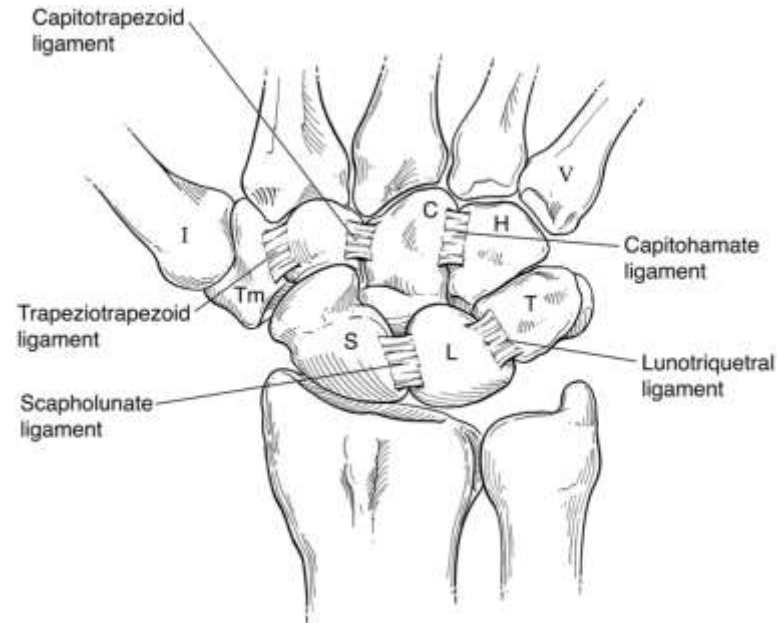
Extrinsic Ligaments

- Dorsal
 - Radiocarpal



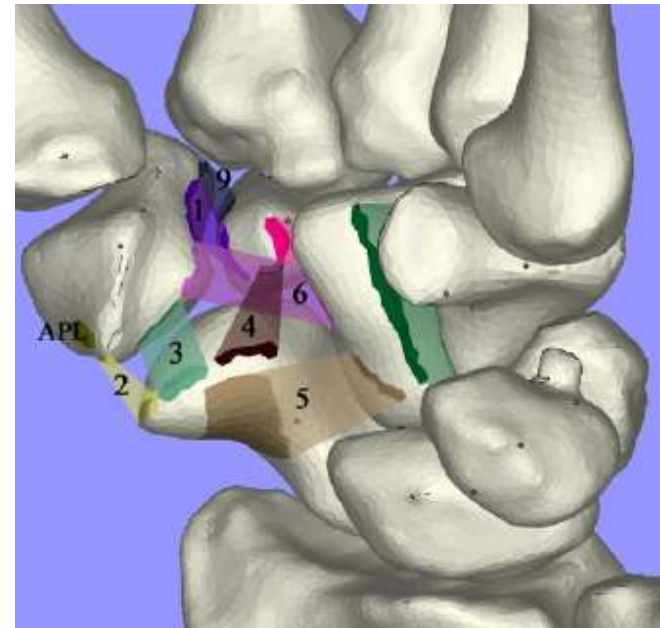
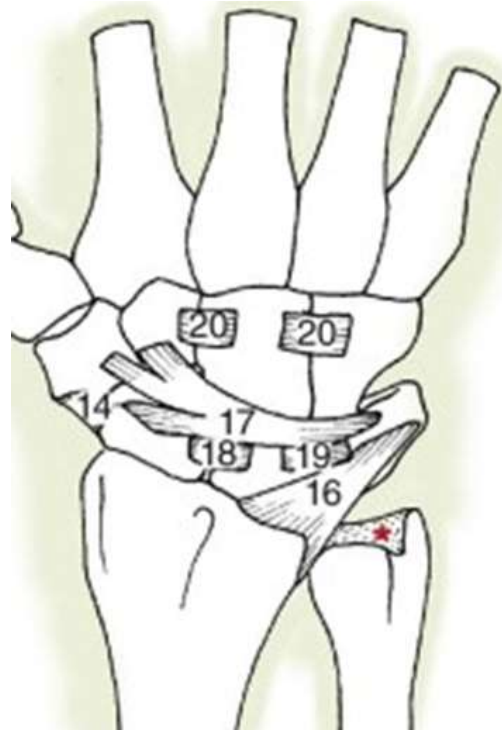
Intrinsic ligaments (proximal row)

- SL
 - 3 parts, dorsal strongest
- LT
 - 3 parts, palmar strongest



Intrinsic Ligaments (mid-carpal)

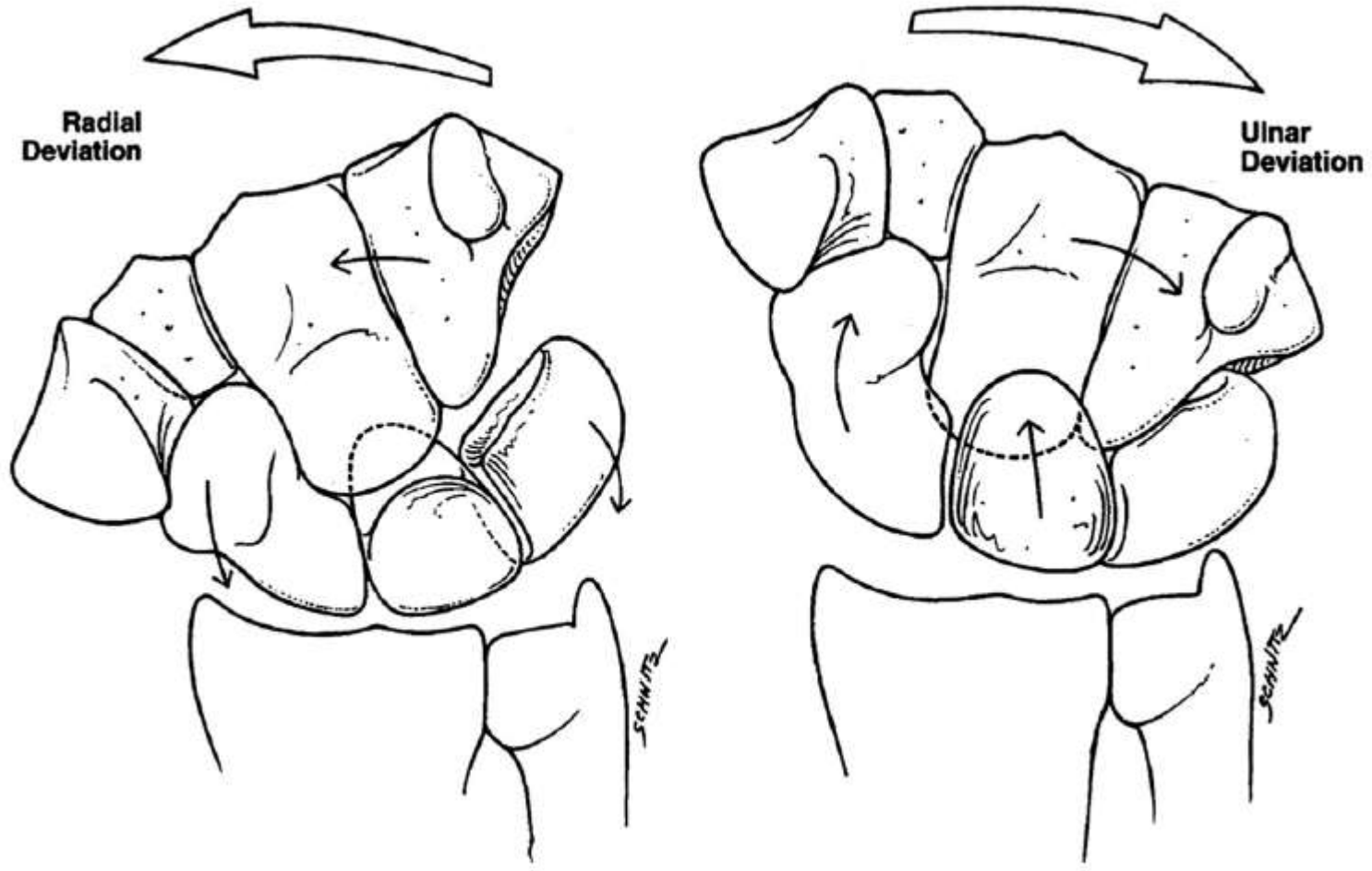
- DIC
- STT
- Secondary stabilisers

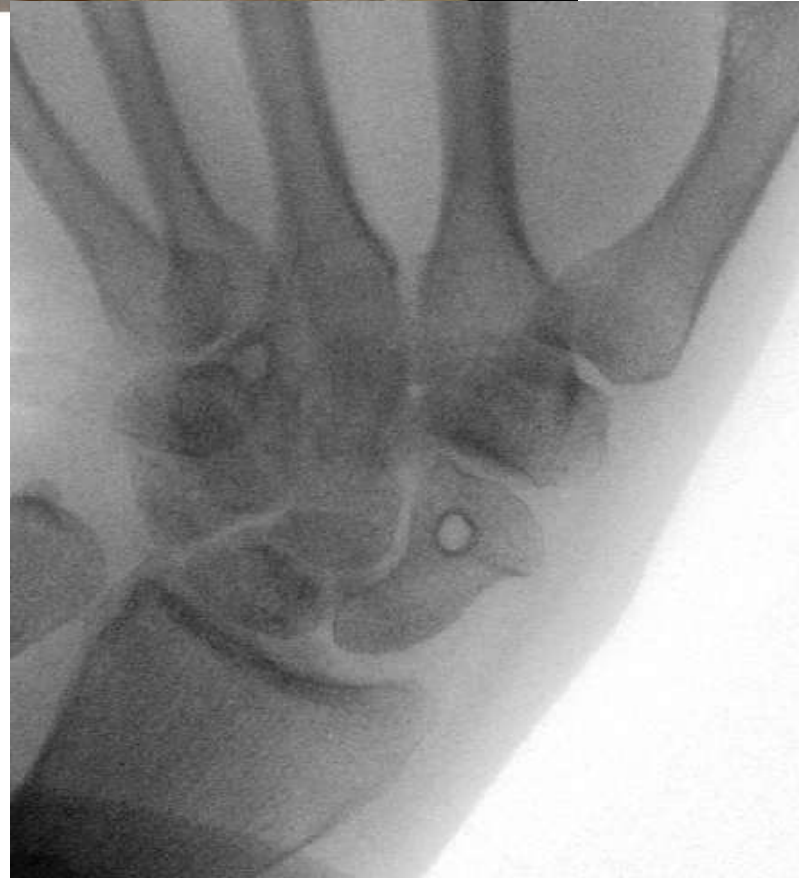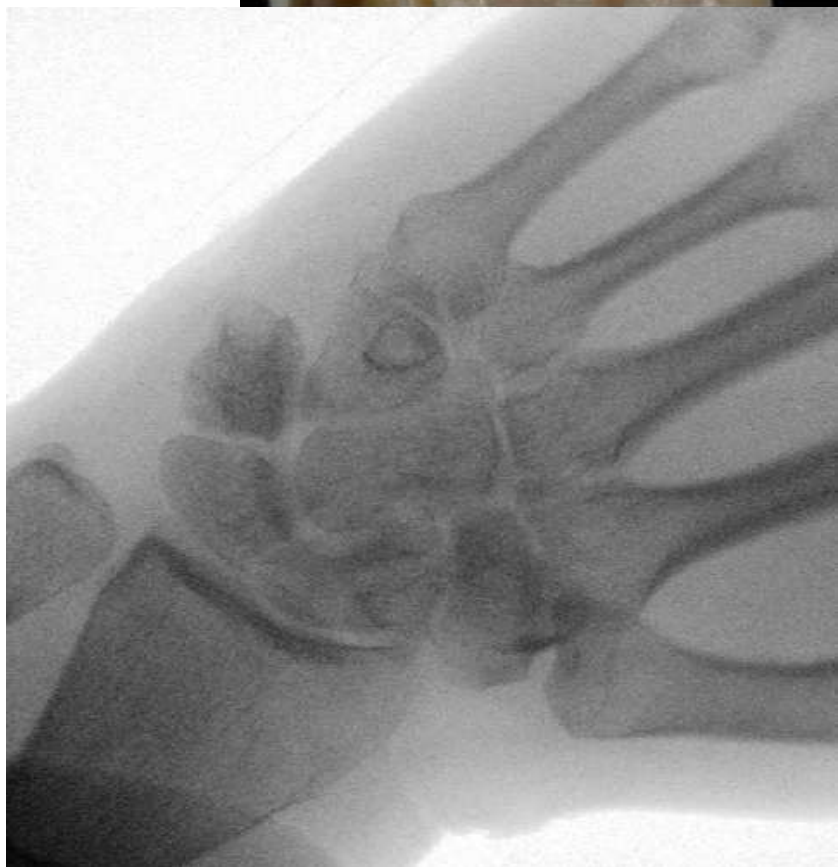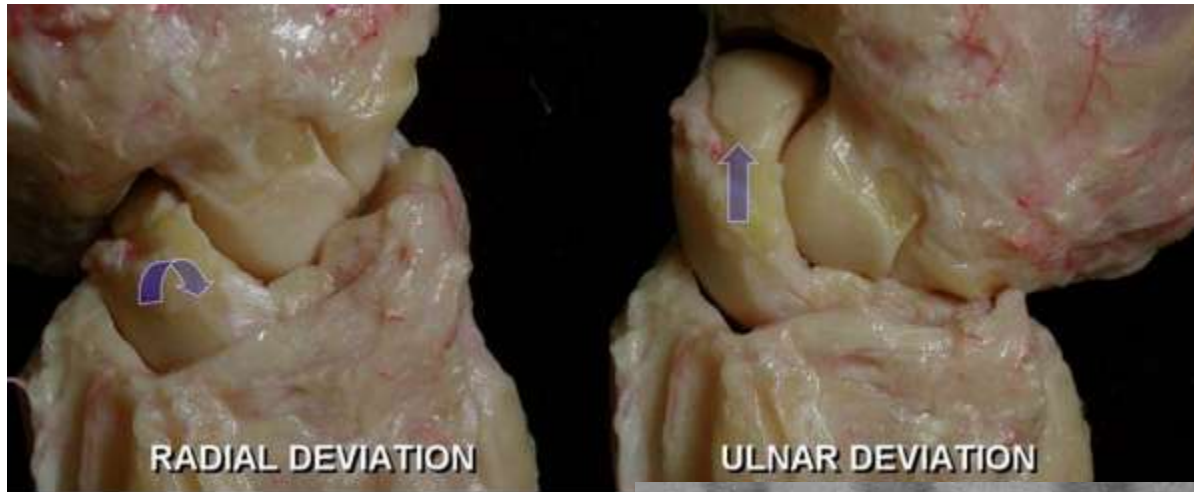


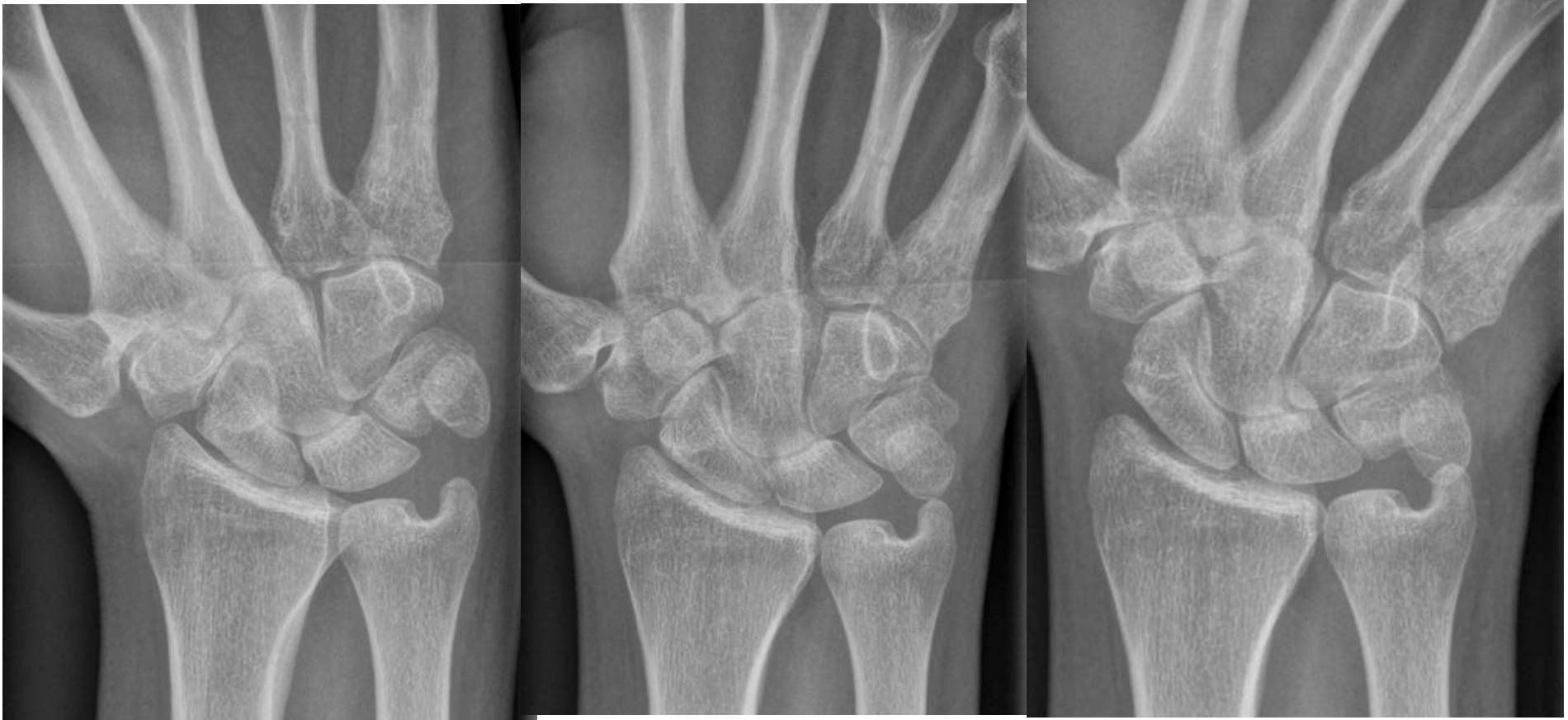Kinematics

- Multiple articulations/complex motion
- Instant centre of rotation – Capitate head
- Axis of flx/ext – radial to ulnar styloid
- Flexion/extension
- Radial/ulnar deviation
- Dart throwing
- Range (functional)
 - Flexion 65 (10)
 - Extension 55(35)
 - RD 15 (10)
 - UD 35 (15)
- Flexion
 - 40% RC
 - 60% MC
- Extension
 - 66% RC
 - 33% MC

Movement of Proximal Row with Radial and Ulnar Deviation

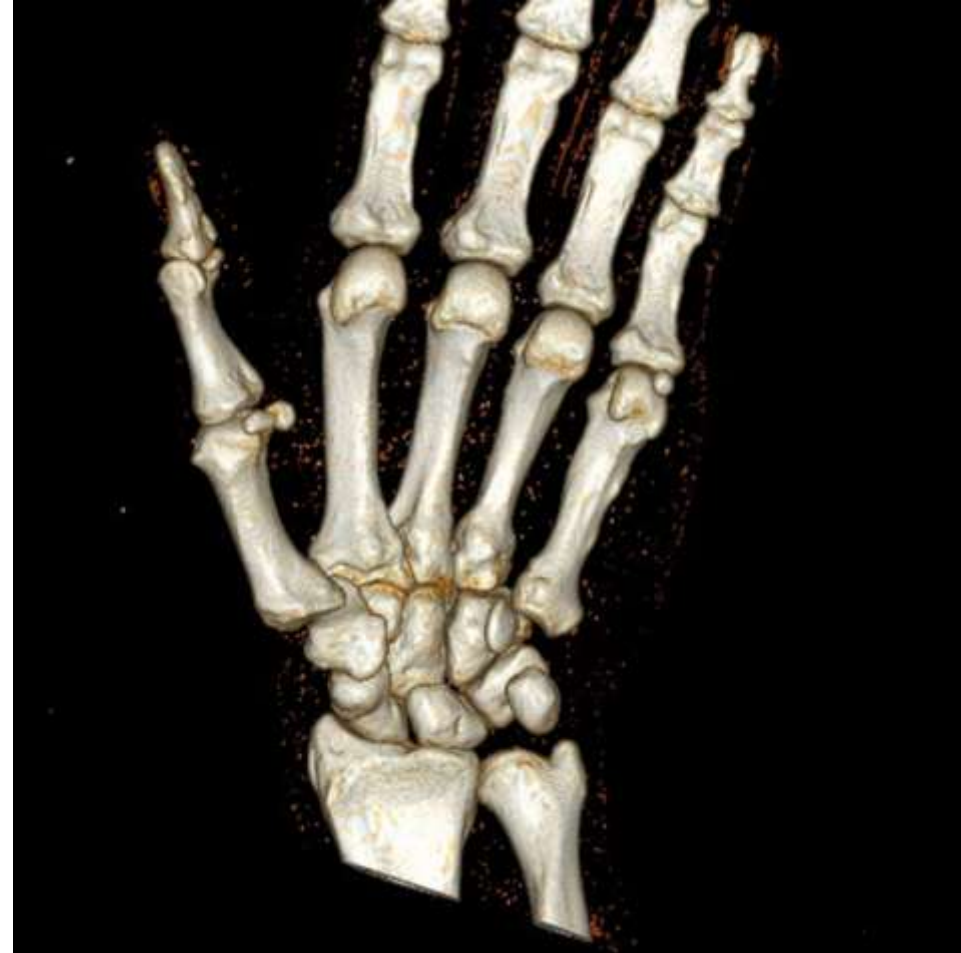





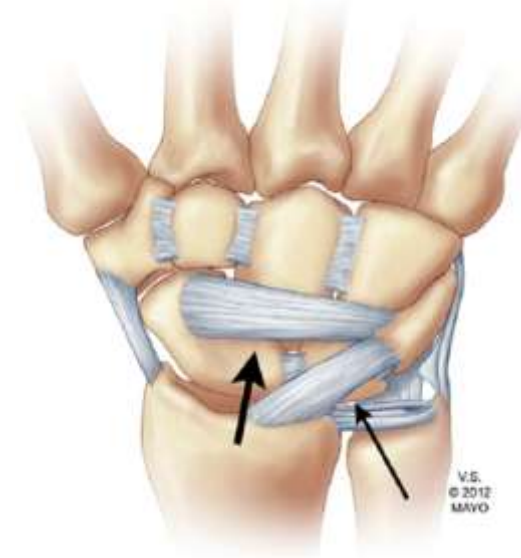
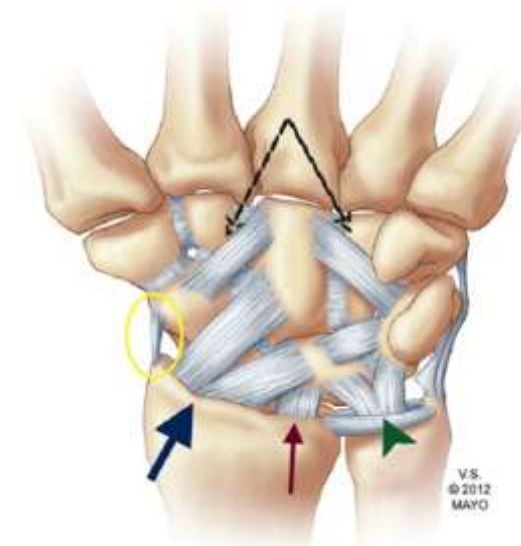
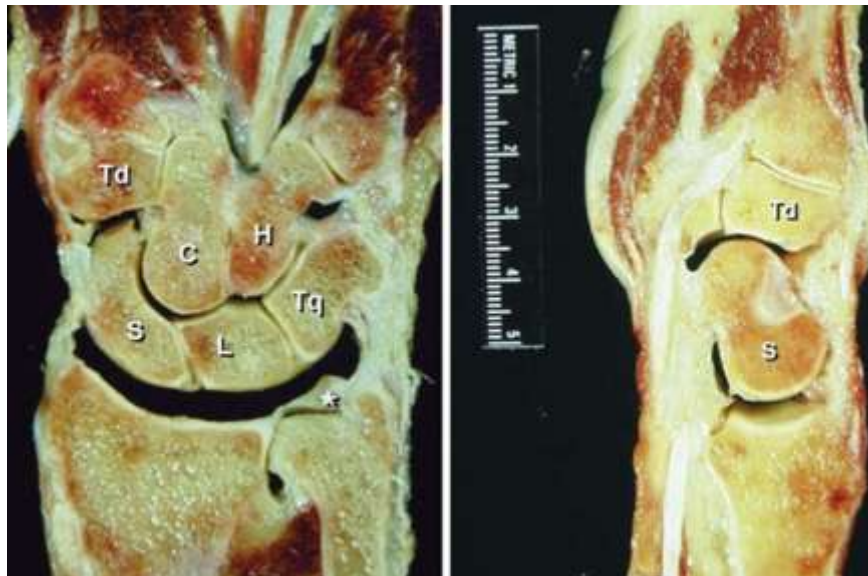Carpal Kinetics

- Considerable force (25 kg during flx/ext, upto 500kg with grip and load)
- Load + muscle contraction
- 60% load through capitate-scaphoid-lunate articulation
- 80% RC (50% RS, 30% RL)
- 20% UC
- Varies with position and variance



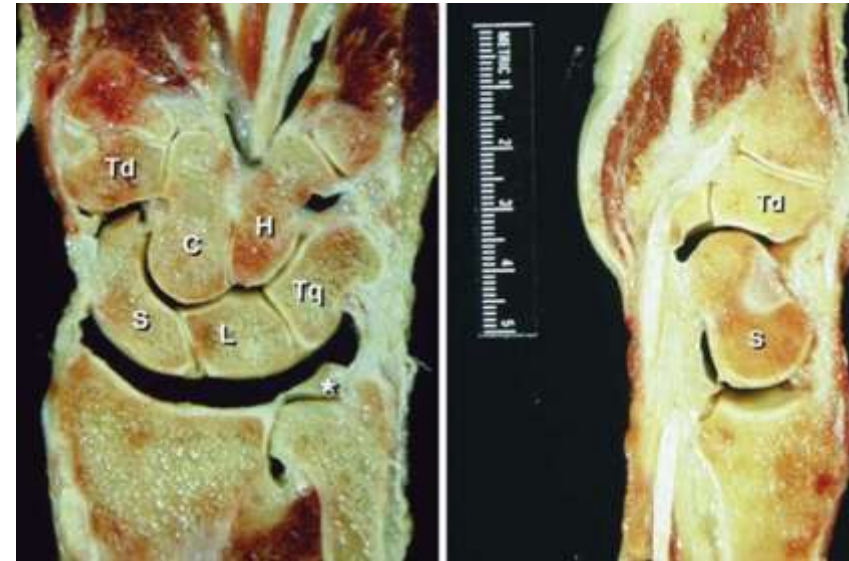Carpal Stability with Loading

- Radiocarpal
- Oblique distal ulnar orientation of extrinsic ligaments



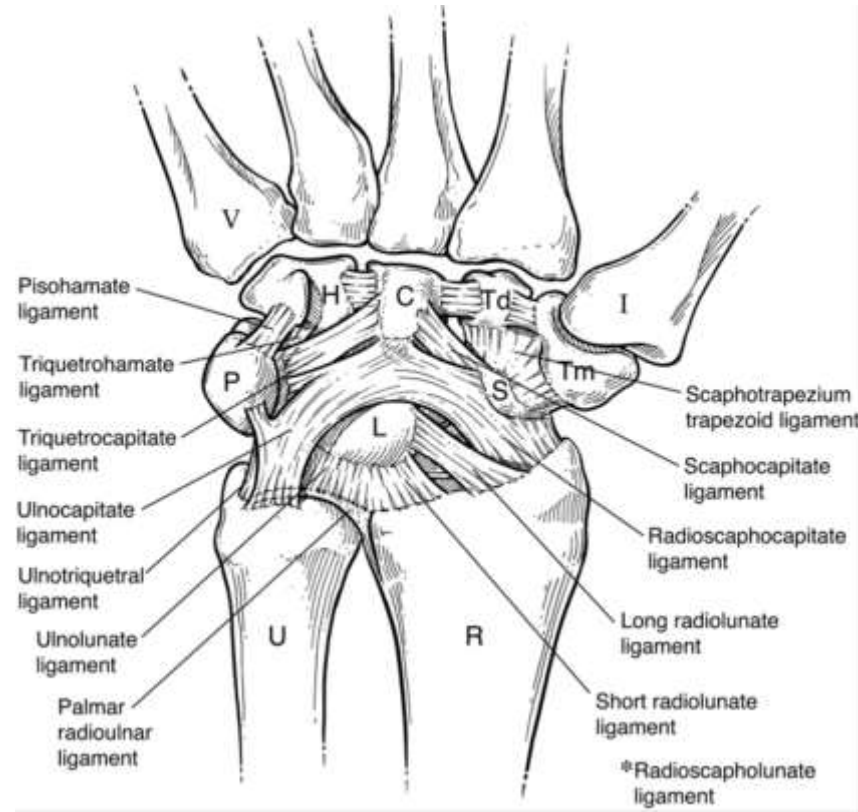
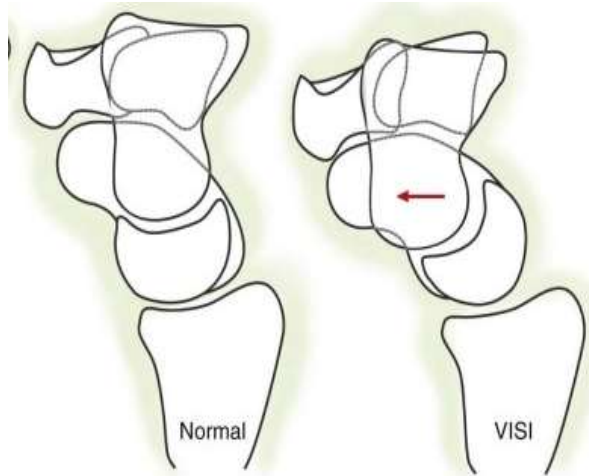
Carpal Stability with Loading

- **Proximal Row**
- Scaphoid flexes and pronates > Lunate (STT and SC lig)
- Triquetrum extends
- Increases co-aptation
- Lunate in equilibrium
- SLL– Lunate extends (DISI)
- LTL – Lunate flexes (VISI)

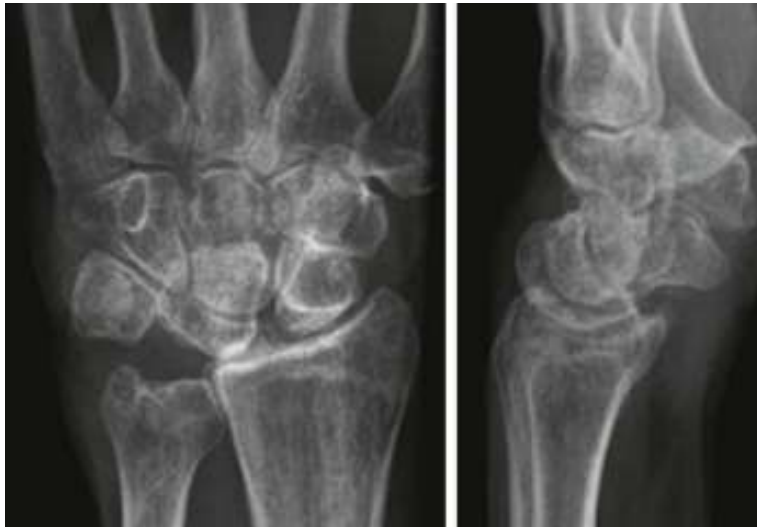


Carpal Stability with Loading

- **Midcarpal Joint**
- Scaphoid flexes
- TrH/TrC,STT/SC,DIC
- Unconstrained flx of PR
- VISI



- VISI (LT Instability)



- VISI (Midcarpal instability)

